



Pathology reporting of breast disease in surgical excision specimens incorporating the dataset for histological reporting of breast cancer

May 2016

Authors:

Professor IO Ellis (Chair)	Dr S Al-Sam	Dr N Anderson
Dr P Carder	Dr R Deb	Dr A Girling
Dr S Hales	Professor A Hanby	Dr M Ibrahim
Dr AHS Lee	Dr R Liebmann	Dr E Mallon
Professor SE Pinder	Dr E Provenzano	Dr C Quinn
Dr E Rakha	Dr D Rowlands	
Professor T Stephenson	Dr C A Wells	

Unique document number	G148 HR (This publication contains high-resolution images and is 12 MB. It is also available on www.rcpath.org as a 4 MB PDF, with lower-res images.)
Document name	Pathology reporting of breast disease in surgical excision specimens incorporating the dataset for histological reporting of breast cancer
Version number	1
Produced by	The authors are members of the Guidelines Working Group of the UK National Coordinating Committee for Breast Pathology, which leads on developing pathology guidance for the NHS Breast Screening Programme (NHSBSP) and for preparation of dataset standards in breast cancer pathology for The Royal College of Pathologists. Dr Ibrahim is a member of UK NEQAS and was co-opted to the Working Group to assist with the sections regarding quality assurance of immunocytochemical predictive testing for hormone receptors and HER2. Dr Liebmann provided guidance on RCPATH policy including standards for hormone receptor evaluation. Dr Rakha is a member of the Research Sub-Committee of the UK National Coordinating Committee for Breast Pathology.
Date active	May 2016
Date for review	May 2019
Comments	This document updates the NHSBSP <i>Guidelines for Pathology Reporting in Breast Cancer Screening</i> and The Royal College of Pathologists' <i>Standards and datasets for reporting cancers: Dataset for histological reporting of breast cancer</i> . It replaces the previous <i>Minimum dataset for breast cancer histopathology</i> , published in 2005. In accordance with the College's pre-publications policy, this document was on the College website for consultation from 21 October to 18 November 2015. Thirty-six items of feedback were received and the document was amended accordingly. Please email publishing@rcpath.org to see the responses and comments. Dr Lorna Williamson Director of Publishing and Engagement



Published by The Royal College of Pathologists.

4th Floor, 21 Prescott Street, London, E1 8BB

Tel: 020 7451 6700

Email: publishing@rcpath.org

Web: www.rcpath.org

Registered charity in England and Wales, no. 261035

© 2016, The Royal College of Pathologists

This work is copyright. You may download, display, print and reproduce this document for your personal, non-commercial use. Apart from any use as permitted under the Copyright Act 1968 or as set out above, all other rights are reserved. Requests and inquiries concerning reproduction and rights should be addressed to The Royal College of Pathologists at the above address.

First published: 2016

Contents

Writing group membership	6
Foreword	7
Introduction.....	8
Key changes in this edition	9
1 Specimen handling.....	9
1.1 General principles.....	9
1.2 Pathology request form	10
1.3 Surgical handling	12
1.4 Laboratory handling.....	13
1.5 Diagnostic localisation excision biopsies.....	13
1.6 Therapeutic wide local excisions.....	14
1.7 Mastectomy specimens	24
1.8 Therapeutic excision and mastectomy specimens for invasive carcinoma following neoadjuvant chemotherapy: macroscopic handling.....	30
1.9 Oncoplastic specimens.....	32
1.10 Pathological examination of lymph nodes	32
2 Classifying benign lesions.....	35
2.1 Solitary cyst	35
2.2 Fibrocystic change.....	36
2.3 Columnar cell change without atypia.....	37
2.4 Fibroadenoma.....	37
2.5 Papilloma.....	39
2.6 Sclerosing adenosis.....	41
2.7 Sclerosing lesions (complex sclerosing lesion/radial scar)	41
2.8 Periductal mastitis/duct ectasia (plasma cell mastitis).....	43
2.9 Mastitis and mammary duct fistula	43
2.10 Reaction to breast implants.....	43
2.11 Other (specify)	43
2.12 Benign lesions in male breast including gynaecomastia	44
3 Classifying epithelial proliferation.....	44
3.1 Epithelial proliferation – not present.....	44
3.2 Epithelial proliferation – present without atypia	45
3.3 Columnar cell lesions.....	47
3.4 Epithelial proliferation – present with atypia (ductal).....	49
3.5 Epithelial proliferation – present with atypia (lobular)	52

4	Classifying malignant non-invasive lesions	55
4.1	Ductal carcinoma <i>in situ</i>	55
4.2	Rarer subtypes of DCIS.....	57
4.3	DCIS in papilloma, papillary carcinoma <i>in situ</i> and encysted papillary carcinoma	59
4.4	Paget’s disease of the nipple	61
4.5	Microinvasive carcinoma.....	62
4.6	Epithelial displacement in breast tissue following needle/core biopsy	62
5	Classifying invasive carcinoma.....	63
5.1	Tumour type categories	63
5.2	Morphological types of invasive breast cancer	64
6	RCPATH core data items.....	70
6.1	Basic data items	70
6.2	Tumour classification and prognostic factors.....	72
7	Assessment of hormone receptors	89
7.1	Recommendations for steroid receptor testing	89
7.2	Principles	90
7.3	Scoring	91
7.4	Core biopsy	92
7.5	Multiple tumours	92
7.6	Ductal carcinoma <i>in situ</i>	92
7.7	Audit and benchmarking	92
7.8	Quality assurance for oestrogen receptor evaluation	93
8	Assessment of human epidermal growth factor receptor 2 (HER2)	95
8.1	Introduction.....	95
8.2	Pre-analytical measures	96
8.3	Algorithms for HER2 testing.....	97
8.4	Good practice and quality assurance measurements.....	102
8.5	Quality assurance for HER2 receptor evaluation.....	105
9	Comments/additional information	108
10	Diagnostic staging and coding.....	108
10.1	pTNM status should be recorded according to the 7th edition UICC	108
10.2	SNOMED codes	108
11	Non-core data items	108
12	Criteria for audit.....	109
13	References	109

Appendices

A	NHS BSP breast pathology synoptic proforma template, including dataset and commonly used optional items.....	118
B	RCPATH dataset for histopathological reporting of breast cancer surgical resections (<i>in situ</i> and invasive disease)	123
C	RCPATH proforma in list format.....	127
D	TNM classification of tumours of the breast	133
E	Recommended SNOMED codes for breast pathology	137
F	Index for screening NHSBSP office pathology system	142
G	Diagnostic immunohistochemistry of the breast	147
H	Prognostic classifiers in breast cancer and emerging prognostic and biomarker assays.....	153
I	Histological grade monograph	158
J	Summary table – Explanation of grades of evidence.....	159
K	AGREE compliance monitoring sheet.....	160



NICE has accredited the process used by The Royal College of Pathologists to produce its Cancer Datasets and Tissue Pathways guidance. Accreditation is valid for 5 years from July 2012. More information on accreditation can be viewed at www.nice.org.uk/accreditation. For full details on our accreditation visit: www.nice.org.uk/accreditation.

Membership of the Writing Group

Chair: Professor I O Ellis	Professor of Cancer Pathology Nottingham University Hospitals NHS Trust Department of Histopathology City Hospital Campus Hucknall Road Nottingham NG5 1PB
Dr S Al-Sam	Princess Alexandra Hospital, Harlow
Dr N Anderson	Royal Victoria Hospital, Belfast
Dr P Carder	Bradford Royal Infirmary
Dr R Deb	Royal Derby Hospital
Dr A Girling	Norfolk and Norwich University Hospital
Dr S Hales	Countess of Chester Hospital, Chester
Professor A Hanby	St James's University Hospital, Leeds
Dr M Ibrahim	UK NEQAS for Immunocytochemistry, University College London
Dr A H S Lee	Nottingham University Hospitals NHS Trust
Dr R Liebmann	Queen Victoria Hospital NHS Foundation Trust, Sussex
Dr E Mallon	Department of Pathology, Southern General Hospital, Glasgow
Professor S E Pinder	Division of Cancer Studies, King's College London
Dr E Provenzano	Cambridge University Hospitals NHS Foundation Trust
Dr C Quinn	St Vincent's University Hospital, Dublin
Dr E Rakha	Nottingham University Hospitals NHS Trust
Dr D Rowlands	Royal Wolverhampton Hospitals NHS Trust
Professor T Stephenson	Royal Hampshire Hospital, Sheffield
Dr C A Wells	University College London

Authors can be contacted via The Royal College of Pathologists (publishing@rcpath.org).

Acknowledgement

The NHS Breast Screening Programme is grateful to the members of the Guidelines Working Group of the UK National Coordinating Committee for Breast Pathology for their work in updating the *Guidelines for Pathology Reporting in Breast Cancer Screening*. The NHS Breast Screening Programme will reference this updated guidance in its future publications.

Jacque Jenkins

Programme Manager

NHS Breast Screening Programme

April 2016

Foreword

The cancer datasets published by The Royal College of Pathologists (RCPATH) are a combination of textual guidance, educational information and reporting proformas. The datasets enable pathologists to grade and stage cancers in an accurate, consistent manner in compliance with international standards and provide prognostic information thereby allowing clinicians to provide a high standard of care for patients and appropriate management for specific clinical circumstances. It may rarely be necessary or even desirable to depart from the guidelines in the interests of specific patients and special circumstances. The clinical risk of departing from the guidelines should be assessed by the relevant multidisciplinary team (MDT); just as adherence to the guidelines may not constitute defence against a claim of negligence, so a decision to deviate from them should not necessarily be deemed negligent.

Each dataset contains core data items that are mandated for inclusion in the Cancer Outcomes and Services Dataset (COSD – previously the National Cancer Data Set) in England. Core data items are items that are supported by robust published evidence and are required for cancer staging, optimal patient management and prognosis. Core data items meet the requirements of professional standards (as defined by the Information Standards Board for Health and Social Care [ISB]) and it is recommended that at least 90% of reports on cancer resections should record a full set of core data items. Other, non-core, data items are described. These may be included to provide a comprehensive report or to meet local clinical or research requirements. All data items should be clearly defined to allow the unambiguous recording of data.

The following stakeholder organisations have been consulted during the preparation of the dataset:

- National Co-ordinating Committee for Quality Assurance Radiologists
- The Royal College of Radiologists' Breast Group
- Association of Breast Surgery
- NHS Screening Programmes.

Evidence for the revised dataset was obtained from updates to international tumour grading, staging and classification systems and by electronically searching medical literature databases for relevant research evidence, systematic reviews and national or international breast cancers. The level of evidence for the recommendations has been summarised (Appendix J). Unless otherwise stated, the level of evidence corresponds to 'Good practice point (GPP): Recommended best practice based on the clinical experience of the authors of the writing group'.

No major organisational changes or cost implications have been identified that would hinder the implementation of the dataset for the core items.

A formal revision cycle for all cancer datasets takes place on a three-yearly basis. However, each year, the College will ask the authors of the dataset, in conjunction with the relevant sub-specialty advisor to the College, to consider whether or not the dataset needs to be updated or revised. A full consultation process will be undertaken if major revisions are required, i.e. revisions to core data items (the only exception being changes to international tumour grading and staging schemes that have been approved by the Specialty Advisory Committee on Cellular Pathology and affiliated professional bodies; these changes will be implemented without further consultation). If minor revisions or changes to non-core data items are required, an abridged consultation process will be undertaken whereby a short note of the proposed changes will be placed on the College website for two weeks for Fellows' attention. If Fellows do not object to the changes, the short notice of change will be incorporated into the dataset and the full revised version (incorporating the changes) will replace the existing version on the College website.

The dataset has been reviewed by the Working Group on Cancer Services and was placed on the College website for consultation with the membership from 21 October to 21 November 2015. All

comments received from the Working Group and the membership were addressed by the authors to the satisfaction of the Chair of the Working Group and the Director of Publishing and Engagement.

This dataset was developed without external funding to the writing group. The College requires the authors of datasets to provide a list of potential conflicts of interest; these are monitored by the Director of Clinical Effectiveness and are available on request. The authors of this document have declared that there are no conflicts of interest.

Introduction

To reduce mortality from breast cancer requires all professional groups involved to perform to the highest standards. The quality of pathological services is of the utmost importance; it is the pathologist who invariably makes the definitive diagnoses of breast cancer but additional features of *in situ* and invasive carcinomas that have prognostic significance are also required to determine the most appropriate management for individual patients. Thus the management of patients with breast disease and breast cancer detected through mammographic screening or symptomatic presentation depends heavily on the quality of the pathology service.

This document has been produced by The Royal College of Pathologists and updates the NHS Breast Screening Programme's (NHSBSP) guidelines for pathology reporting in breast cancer screening and The Royal College of Pathologists' dataset for breast cancer. It serves to give guidance and recommendations on all aspects of pathology examination of breast lesions. It is relevant to both screen-detected and symptomatic disease. Accurate pathology diagnoses and the provision of prognostically significant information are important to ensure that patients are managed appropriately and that that breast services and the NHSBSP are effectively monitored and evaluated. A standard set of data from each patient, using the same terminology and diagnostic criteria, is essential to achieve these objectives. These guidelines therefore aim to encourage use of common terminology and definitions of breast disease and methods of classifying breast cancer.

The reporting forms and the guidance in the following pages were produced after extensive and lengthy consultation with participating pathologists. They define the RCPATH set of data for reporting breast cancer and the complementary NHSBSP dataset for breast screening pathology. The standards of reporting symptomatic cancers are the same as those for reporting screen detected lesions. The dataset for reporting of breast cancer has been implemented for the following reasons.

1. Certain features of invasive carcinoma (size, type, grade, lymphovascular invasion, lymph node status) have been shown to be related to clinical outcome. Consequently these features may be important in:
 - deciding on the most appropriate treatment for a particular patient, including the extent of surgery and the use and choice of adjuvant therapy
 - monitoring breast screening programmes, the success of which is reflected by more favourable prognostic features of the cancers detected
 - monitoring changing patterns of disease, particularly by cancer registries.
2. Classification of ductal carcinoma *in situ* (DCIS) together with reporting of margins of excision and size has been shown to be related to the probability of recurrence after local excision and may influence the use of mastectomy or adjuvant radiotherapy.
3. Close correlation of radiological and histopathological features is essential to ensure that mammographically detected lesions have been sampled and accurately diagnosed.

This document also serves to provide guidance for pathologists when participating in the UK breast pathology EQA scheme. Two of the major objectives for pathology quality assurance (QA) in the NHSBSP were to improve the consistency of diagnoses made by pathologists and the quality of prognostic information in pathology reports. In order to achieve these objectives, a standardised

reporting proforma and, as stated above, supporting guidelines for reporting breast pathology were developed jointly by The Royal College of Pathologists and the NHSBSP. The national breast EQA scheme was set up in parallel as an educational tool and to investigate the level of consistency that pathologists involved in the screening programme could achieve in reporting breast lesions. Clearly this is determined not only by the performance of the pathologists themselves but also by the methodology they use. Problems identified can be addressed through various initiatives, the success of which could be evaluated in further rounds of the scheme. The EQA scheme now incorporates a measure of performance appraisal.

In addition, guidance is included in this document on laboratory evaluation and reporting predictive factors, specifically hormone receptor and HER2 status. New sections dealing with the handling of oncoplastic and post neoadjuvant therapy surgical specimens are included, as are appendices on immunohistochemistry and on emerging prognostic biomarkers.

Key changes in this edition

- Document has been updated to the standards of the RCPATH cancer datasets.
- Improved guidance on specimen examination, including handling of oncoplastic and post-neoadjuvant therapy specimens.
- A back-to-basics approach, including recommendations on fixation, macroscopic handling and measurement of tumour size.
- Recognition of the implications of the 2015 Association of Breast Surgeons' recommendation of a 1 mm or greater margin distance as definition of complete excision on pathological specimen handling.
- Guidance on ER/PR/HER2 staining and reporting, including the role of NEQAS, QA, minimum numbers, audit and benchmarking.
- Clarification of the definition of negative, borderline and positive HER2 status.
- New appendix of routinely used immunohistochemistry adjuncts.
- Guidance and synoptic reporting template for reporting post-neoadjuvant specimens.
- Significant updates to reporting of lymph nodes, adopting a pragmatic approach.
- The term 'multifocal/multicentric' replaced by 'multiple invasive'.
- Greater emphasis on adherence to criteria use for assessment of tumour type and use of 90% purity rule for definition of pure special type and 50–90% rule for mixed types.
- Further clarification on change of definition of carcinomas with medullary-like features.

1 Specimen handling

1.1 General principles

Some general principles for specimen handling, both in the operating theatre and in the laboratory, should be applied. The type of surgical procedure will be influenced by whether a preoperative diagnosis has been achieved and, if so, the nature of the diagnosis (benign, indeterminate (core/cytology biopsy categorised B3/C3 or B4/C4) or malignant). If no preoperative diagnosis has been made, the surgical procedure will be in the form of a diagnostic open biopsy – see section 1.5. Surgical QA guidelines indicate that such diagnostic specimens should be confined to removal of the lesion with a minimal amount of surrounding tissue in order to avoid leaving a cosmetic defect. These specimens should

generally weigh less than 20 g and should therefore be weighed in the pathology laboratory and the result included in the pathology report. The lesion may be impalpable, and resection may require image-guided localisation using a wire, dye or radioisotope. Frozen section examination is inappropriate for the diagnosis of screen-detected lesions.

If a benign preoperative diagnosis has been made, the lesion may be removed at the patient's request. Such resection specimens should be confined to removal of the lesion with a minimal amount of surrounding tissue, to avoid leaving a cosmetic defect. In some centres, where available, vacuum assisted large bore needle resection may be used for the resection of some benign and selected indeterminate (B3) lesions.

If a malignant diagnosis has been made, the surgical procedure is therapeutic. The type of operation (e.g. wide local excision or mastectomy) will be influenced by the nature, size and location of the lesion, as well as by patient choice. The technique chosen for pathological examination of these specimens requires knowledge of the surgical method used, the anatomical boundaries of the resection, and whether (particularly if the lesion has been detected mammographically) the radiological abnormality is a mass lesion or calcification. Whichever technique is used, the method should enable production of the breast cancer dataset information, which should be collated by the pathologist from the findings in multiple specimens (if required).

Before examining the specimen the pathologist should ensure that they are aware of any previous pathological findings, including the pre-operative diagnosis. The pathologist also needs to be aware of the pre-operative clinical and radiological findings, including the nature, size, site and location of the lesion(s) and any previous treatment (e.g. neoadjuvant chemotherapy) as these will determine the most appropriate approach to examination, dissection and block selection. The pathology request form should be used to convey this information.

1.2 Pathology request form

A request form (Figure 1) with a standardised approach to its completion for all breast tissue specimens is recommended. The information provided should be relevant to the specimen type and includes at least the following items of information, in addition to patient's details/demographic information.

1. Date and (ideally) time of surgery.
2. Number of specimen containers submitted and their contents/type of specimen, identifying each specimen separately and their relationship to each other.
3. History and clinical findings, including: whether right or left breast, number of lesions and their size, location within the breast (clock-face/quadrant position), and whether there is a history of neoadjuvant therapy including comment on clinical or radiological response. A diagram can be very helpful.
4. Imaging (mammography, ultrasound, MRI) results, including type of imaging abnormality, final imaging classification, size and location of imaging abnormality (clock face/quadrant position).
5. Biopsy results for each lesion; if appropriate quoting previous histology numbers/details and laboratory of origin if performed elsewhere.
6. Method of localisation used.
7. A diagram or description indicating the position of the orientating clips/sutures on the specimen.
8. Whether the relevant lesion was identified on specimen imaging, if performed.
9. Radioactive specimens should be clearly labelled as such.

- 10. For axillary specimens: whether sentinel node, lymph node sample or axillary clearance specimen.
- 11. For axillary clearance specimens: a clear indication as to which level was dissected.

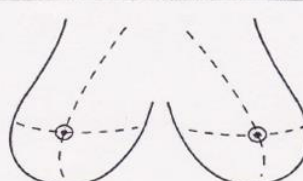
Please affix patient's sticker here (to include name, address and D.O.B.)		BSU / Ward _____ Consultant: _____ Date: _____ Path Meeting Date: _____ Routine / Rapid: _____																												
Symptomatic / Screening	Previous Breast Specimens: YES / NO	Previous Number:																												
Nature of specimen: Nipple discharge FNA Core Biopsy Mammotome Biopsy Mammotome Excision Wide Local Excision Diagnostic Excision Mastectomy	Side: RIGHT LEFT CENTRAL Upper / Lower Inner / Outer Breast Lump Biopsy Microdochetomy	Sampling method: Freehand Ultrasound guided Stereotaxis Mammotome J. Wire	For Histology use: <table border="1" style="width: 100%; border-collapse: collapse;"> <thead> <tr> <th style="padding: 2px;">SFX</th> <th style="padding: 2px;">PCS</th> <th style="padding: 2px;">BLK</th> </tr> </thead> <tbody> <tr><td> </td><td> </td><td> </td></tr> <tr><td> </td><td> </td><td> </td></tr> <tr><td> </td><td> </td><td> </td></tr> <tr><td> </td><td> </td><td> </td></tr> <tr><td> </td><td> </td><td> </td></tr> <tr><td> </td><td> </td><td> </td></tr> <tr><td> </td><td> </td><td> </td></tr> <tr><td> </td><td> </td><td> </td></tr> </tbody> </table>	SFX	PCS	BLK																								
SFX	PCS	BLK																												
Clinical Abnormality Yes / No Thickening / Mass Other: Size: _____ mm	Clinical Score 1. Normal 2. Benign 3. Equivocal 4. Suspicious 5. Malignant	US Score 1. Normal 2. Benign 3. Equivocal 4. Suspicious 5. Malignant	Radiological Score 1. Normal 2. Benign 3. Equivocal 4. Suspicious 5. Malignant	Image Abnormality Single / Multifocal Calcification ^u Mass Asymmetry / Distortion																										
Calcification Benign Indeterminate Malignant	Radiological Size _____ mm	Axillary Procedure None Clearance Sample Sentinel	Specimen Weight _____ grams																											
Other clinical details: Signature: _____																														
		ER status required YES / NO Specimen x-ray on PACS YES / NO Second form sent YES / NO																												

Figure 1: An example specimen request form

1.3. Surgical handling

It is anticipated that lesions will be resected according to a defined surgical protocol as per the Surgical Guidelines for the management of breast cancer (Association of Breast Surgeons at BASO 2009). If the surgical resection differs from the protocol, e.g. if dissection does not extend to the deep fascia or skin when this is the norm, this should be clearly indicated on the request form, as this will influence the examination of the margins of the specimen.

- The surgeon should orientate all breast cancer resection specimens. Each unit should establish a code of orientation using either different lengths, or number, of sutures and/or metal staples/clips or ink. The code should be anatomically relevant and assist in accurate evaluation of the specimen and its margins. The nipple extension/direction of the nipple should be separately marked. If clip/suture placement differs from the agreed local protocol this should be clearly stated on the request form.
- It is helpful if the site of the tumour in the breast is indicated on the specimen request form as this will assist in identification of the margin nearest the nipple, if this has not been marked by the surgeon. Diagrams can be very useful.
- If more than one piece of tissue is removed, it should be made clear (e.g. using clips and/or diagrams) how the samples are orientated with respect to each other in order to simplify assessment of the size of the lesion and final distance to resection margins.
- Intra-operative specimen radiography is mandatory for impalpable lesions requiring localisation and recommended for all wide local excision procedures.¹ This allows confirmation of the presence of the abnormality and also its location in the specimen, thus facilitating immediate re-excision if the specimen is close to a margin. The specimen radiographs, whether digital or hard copy film must, however, be available to the pathologist so that he/she can be certain of the nature of the lesion, e.g. mass, stromal deformity, calcification and the site within the specimen, in order to facilitate histological sampling.
- It is strongly recommended that the specimen should be sent immediately to the pathology laboratory and pre-dissected/incised, ideally in the fresh state. Ideally the plane of maximum dimension of the tumour should be palpated and thus identified prior to slicing to enable accurate incision through the tumour. If incision of the fresh specimen is not possible, it should be immediately placed in an adequate volume of fixative, at least twice that of the specimen. In the latter circumstance, and by arrangement with the pathologist, consideration should be given to training the surgeon to make a controlled single or cruciate pair of incisions into the lesion from the posterior aspect, thus preserving the integrity of key margins while allowing immediate penetration of fixative (Figure 2a). Some centres have adopted a fixative injection methodology to assist in fixation of larger mastectomy specimens. Refrigeration can also be helpful in delaying autolysis.
- The benefits of rapid fixation (good tissue morphological conservation with preservation of mitotic figures and retention of proteins such as oestrogen receptor) in general outweigh the desire to preserve the specimen intact prior to examination by the pathologist. This is most important for mastectomy specimens into which formalin penetration can be particularly poor resulting in tumour autolysis with consequent effects on mitotic count as a component of histological grade, biomarker expression including oestrogen receptors (ER) and the assessment of lymphovascular invasion.

[Level of evidence – GPP.]

1.4 Laboratory handling

Once received in the laboratory, the entire clinically relevant surgical margins should be inked so that the margins of excision can be easily determined histologically. This can be facilitated by prior removal of surface lipid by dipping the specimen in alcohol and drying and then applying an appropriate pigment such as India ink, Alcian blue, dyed gelatine or a multiple ink technique. Multiple colour ink techniques have advantages, as specific resection margins are still identifiable even if one has to re-examine the wet specimen. They also facilitate large block use if desired. India ink can be fixed after painting using 10% acetic acid. See section 1.7 below for detailed handling of mastectomy specimens.

Good fixation is vital to preserve the morphological detail. This is particularly relevant for the diagnosis of some difficult intraductal epithelial proliferations, classification and prognostication in malignancy (e.g. histological grade, type and lymphovascular invasion) and expression of biomarkers, e.g. oestrogen receptor (ER). Specimens must be placed in sufficient formalin (twice the volume of the specimen) or other appropriate fixative inside an appropriately sized and shaped container either before or, preferably, after receipt by the laboratory. Incision of the specimen as described above (section 1.3) is beneficial in achieving rapid fixation of the tumour in larger specimens, particularly mastectomies.

There is no requirement to delay handling of radioactive specimens for reasons of radiation risk.² Procedures for the management of radioactive materials and specimens are at the sole discretion of the Local Radiation Protection Officer. However, it has been shown that from a radiation protection risk perspective, there is no reason why radiolabeled specimens in pursuit of sentinel node biopsy should not be handled and/or dissected with any imposed delay, in view of the low radiation exposure from such samples. Furthermore, those who handle them do not need to be registered as Radiation Workers. However, any concerns should be discussed with the local Radiation Protection Office. Aside from the pathology dissection issues, the local Radiation Protection Office will make stipulations about transport of specimens to the laboratory, and about discharge of radioactive material into the waste system, with which the laboratory will need to comply.

1.5 Diagnostic localisation excision biopsies

These specimens are produced when a pre-operative diagnosis has not been made and there are suspicious radiological or clinical findings, or when the pre-operative diagnosis is of an indeterminate (e.g. C3/B3 or C4/B4) lesion.

- The specimen should be inked, weighed, measured in three dimensions and then, usually, serially sliced at intervals of approximately 3–5 mm.
- Specimens containing impalpable mammographic lesions, such as microcalcification, will require specimen slice x-ray examination if a block selection process is undertaken (i.e. those that are not embedded in their entirety). This enables blocks to be taken from the areas corresponding to the mammographic abnormality as well as any other suspicious areas identified.
- Images can be annotated to indicate sites of block selection.
- The sampling technique and the number of blocks taken are clearly dependent on the size of the specimen and the size of the abnormality. If the specimen is small (e.g. less than 30 mm), it is best to block and examine all of the tissue.
- Blocks should be taken to enable a measurement of the histological size of the lesion. Where the maximum macroscopic dimension of a tumour can be blocked directly, it is recommended that a single block across this aspect be taken.
- Where a lesion is larger than can be assessed in a single block, a large block to encompass the maximum dimension may be taken. When taking large blocks at least

one other normal sized lesional block should be processed as well, to allow optimal processing and to avoid the excessive use of antibodies in any immunohistochemistry.

- If large blocks are not available, two or more blocks are recommended from the maximum macroscopic dimension, so that the total tumour size can be estimated by adding the portions together or measuring the maximum dimension on the two slides fitted together. A diagram may be made of how the adjacent blocks relate to each other to avoid misunderstanding of this relationship at the time of microscopy, with the risk of overestimating the tumour size. Occasionally, when the plane of maximum dimension of a non-spherical tumour is not known or is anticipated incorrectly, it may be necessary to stack together the estimated block thicknesses along that axis, to obtain a measurement. This will always be fairly inaccurate and the need to try to find the plane of maximum dimension of the tumour prior to slicing is emphasised.
- For diffuse tumours, especially diffuse lobular carcinomas, it may not be possible to define macroscopically the true extent of tumour and in this case, either a large block or consecutive blocks of the whole abnormal area (including adjacent fibrotic tissue) may be necessary.
- For larger specimens, sampling should be adequate to determine accurately the size of the lesion. Sampling should include the extremes of the mammographic abnormality and adjacent tissue in order to avoid underestimation of size. This is particularly important with cases that prove to be DCIS (e.g. including cases with a pre-operative core biopsy containing an atypical ductal epithelial proliferation) as it is recognised that mammographic size may be an underestimate of true size.
- If specimens are sent as more than one piece of tissue, it can be impossible to measure the absolute extent of the lesion. In these cases, it is appropriate to take a pragmatic approach and to measure the maximum size in each piece of tissue and add the dimensions to give an estimated total size. If, however, the orientation of the specimens can be determined, the true size can be ascertained more reliably.
- If calcifications cannot be seen histologically, specimen block x-ray may be helpful to determine their location in the sampled tissue.
- Occasional cases will have had a diagnostic excision biopsy before definitive treatment, or primary chemotherapy or exceptionally a frozen section may have been performed. Tumour size assessment in these circumstances may be necessarily inaccurate and an evaluation based on the ultrasound or radiographic size in conjunction with the histology may be necessary. There may also be a problem where multiple core biopsies have completely or partially removed a small tumour. In these situations an estimate of the original tumour size should be given. An estimate of the tumour size (and additional dataset items, such as histological grade and tumour type) should be ascertained from review of the core biopsy and a comment made in the report. This may need discussion with the radiologist and correlation with MRI, ultrasound and mammographic features.
- Although pathology measurement of tumour size is considered the 'gold standard', pathologists are recommended to be pragmatic with respect to assessment of tumour size; where accurate pathological assessment is not feasible then the imaging tumour size, based on ultrasound, MRI or mammographic should be used as the best available record of true tumour size and replace pathological size measurement.

1.6 Therapeutic wide local excisions

Lesions that have a pre-operative diagnosis of malignancy and are deemed to be suitable for breast conserving surgery with regard to clinical/radiological size may be excised as a therapeutic wide local excision.

1.6.1 Wide local excision for invasive carcinoma: presenting as a mass lesion

- Invasive carcinomas typically present as mass lesions, which may or may not be clinically palpable, and are usually visible radiologically and macroscopically in the resected tissue.
- It is usual for the surgeon when performing a therapeutic operation to take all of the tissue from the subcutaneous aspect to the pectoral fascia as per Surgical Guidelines for the management of breast cancer.¹ It is essential that the pathologist be informed if the usual surgical protocol has not been undertaken as this will affect the optimum specimen handling methodology, e.g. central excisions. In such circumstances, when tissue remains at the deep (posterior) or superficial (anterior) aspects of the specimen, the distance to these margins is clinically relevant.
- The surgeon should orientate cancer resection specimens. Each unit should establish a code of orientation using either different lengths or numbers of sutures or metal staples/clips or ink. The code should be anatomically relevant and assist in accurate evaluation of the specimen and its margins. The nipple extension/direction of the nipple may be separately marked by the surgeon and it is helpful if the request form indicates the site of the tumour within the breast so that the radial margin of the specimen nearest the nipple can be identified more easily.
- The specimen should be weighed and measured in three dimensions.
- The specimen should have been incised to allow prompt fixation (see above and Figure 2a) and excision margins should be inked and the specimen can be sliced either before fixation or (less preferably) after fixation.
- The technique for examining the specimen and sampling the abnormality will vary somewhat according to type of sample and specimen size and also according to pathologist/laboratory preference therefore a degree of flexibility is required. Several options are available. Whichever is utilised, as an absolute minimum, the information for the breast cancer dataset, including accurate measurement of size and detailed examination of the margin status and distance to margins, must be provided. Three preferred methods for handling these samples are described below in (Figures 2–4).

Method 1: Radial block, with or without shave margin, examination

- As shown in Figures 2b and 2c, the specimen may be incised from the deep (posterior) fascial plane in a cruciate fashion through the centre of the tumour, essentially extending the fixation cruciate excisions (Figure 2a). This allows the tumour to be sampled as four blocks, which include the medial to lateral and superior to inferior dimensions with the anterior-posterior portions on each of the four.
- It may be possible to sample the lesion and its adjacent radial margin in one block from smaller resections. Larger specimens may require tumour and margin blocking in two (or more) cassettes.
- Sections taken for measurement of distance to margins will include a slice through the lesion to the radial edges of the specimen and will allow measurement of the lesion to the margin distance.
- One or more additional radial blocks extending to the closest margin (e.g. superolateral, superomedial, inferomedial, inferolateral) should be taken if these are the closest.
- For larger specimens, sampling should include the periphery of the abnormality and adjacent tissue in order to avoid underestimation of the size of the lesion. This is particularly important for radiological microcalcifications associated with DCIS as it is recognised that mammographic size can be an underestimate of true lesion size.
- Additional shave margin blocks can be taken³ (Figure 2c).

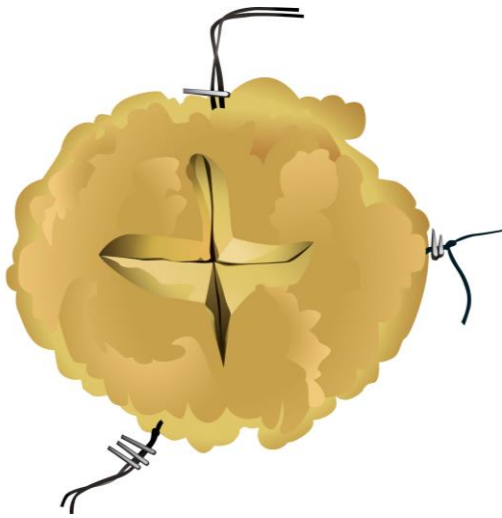


Figure 2a: Cruciate incision of a wide local excision specimen from the posterior deep fascial margin to aid fixation

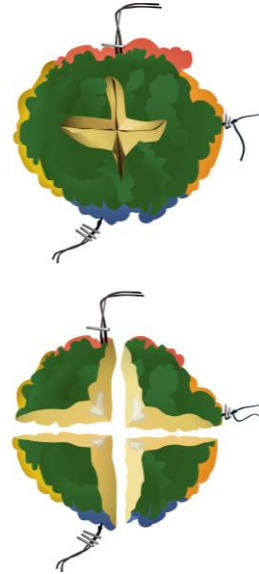

Figure 2b: Cruciate specimen incision method for block sampling

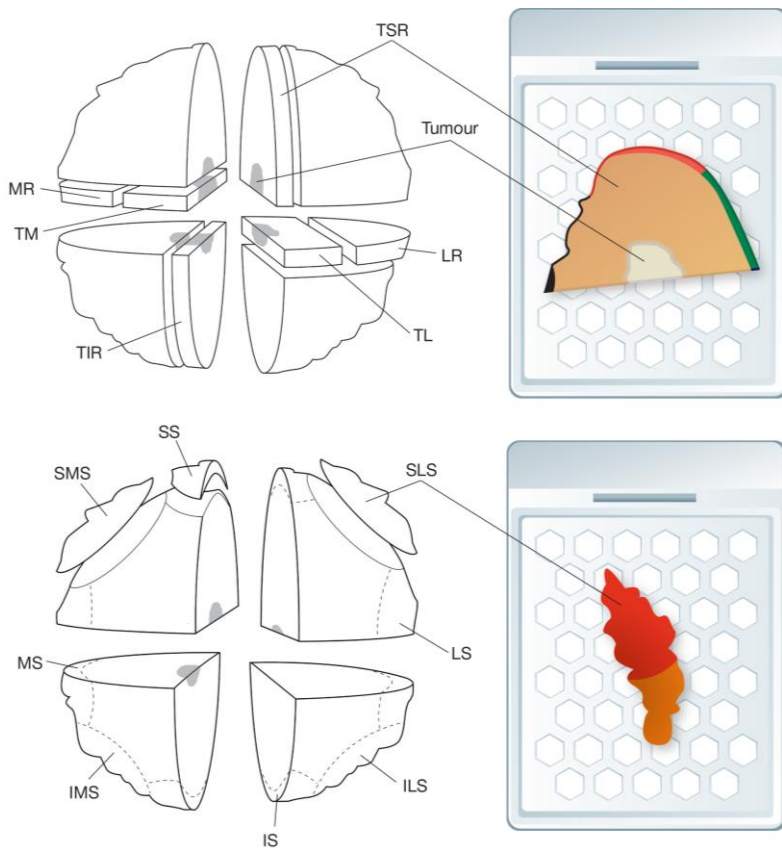


Figure 2c: Cruciate specimen incision method for block sampling indicating example radial and shave margin blocks annotated related to specimen orientation

Method 2: Serial slicing perpendicular to the medial – lateral plane (Figure 3)

- This method is commonly used for examination of impalpable lesions such as microcalcification (see section 1.6.2 below), as it enables specimen slice X-ray mapping of the specimen and provides a high level of confidence that the lesion has been accurately and adequately sampled.
- The specimen can be sliced before fixation, or after fixation and marking of the excision margins. The specimen is sliced at intervals of approximately 3–5 mm usually perpendicular to the medial/lateral axis in the anterior/posterior plane.

Method 3: Serial slicing perpendicular to the superficial – deep plane

- This is a variation of Method 2 and is particularly suitable for smaller specimens in association with large block techniques. The entire specimen can be examined as a small number of serial large sections. The technique is similar to the method currently used to examine radical prostatectomy specimens in many centres.

For all methods

Details of the macroscopic appearances of the specimen should be recorded including:

- tumour size in three dimensions
- distances to all margins.

The method use (see above) and number of blocks taken will depend on the size of the specimen and the size of the abnormality. If the specimen is small it is best to block and examine all the tissue. It is not possible to be prescriptive but sufficient blocks of the tumour should be taken in order to accurately assess important primary characteristics, e.g. size, grade, histological type and lymphovascular invasion. The number of tumour blocks will vary with tumour size but is usually at least three. The edges of the tumour with surrounding uninvolved tissue should also be examined in all three dimensions to identify associated DCIS and peritumoural lymphovascular invasion not visible to the naked eye, and permit accurate an assessment of whole tumour size.

If therapeutic samples are sent in more than one portion, it can be extremely difficult to measure the absolute largest extent of the whole lesion present. In these cases it is appropriate to measure the maximum distance in any piece of tissue and to add the dimensions to give an estimated total size or preferably defer to the imaging size. If, however, the orientation of the specimens can be determined, the size can be ascertained more reliably.

- All surgically relevant margins of therapeutic excision specimens should be sampled. This will include all radial/circumferential margins (superior, inferior, medial, lateral and nipple margins), and the deep (posterior) and superficial (anterior) margins if dictated by local protocol. Particular attention should be paid to the margin nearest the abnormality and the margin nearest the nipple.
- The use of different colour inks/markers on an individual section can assist microscopic identification of specific margins.
- Some units use large blocks to embed the entirety of segmental excisions. This can facilitate assessment of the presence of multiple invasive foci and whole tumour size but the proper processing of these can delay the reporting of the case and storage may also be problematic; many units therefore take a pragmatic approach to the problem.

Wide local excision: sagittal slicing

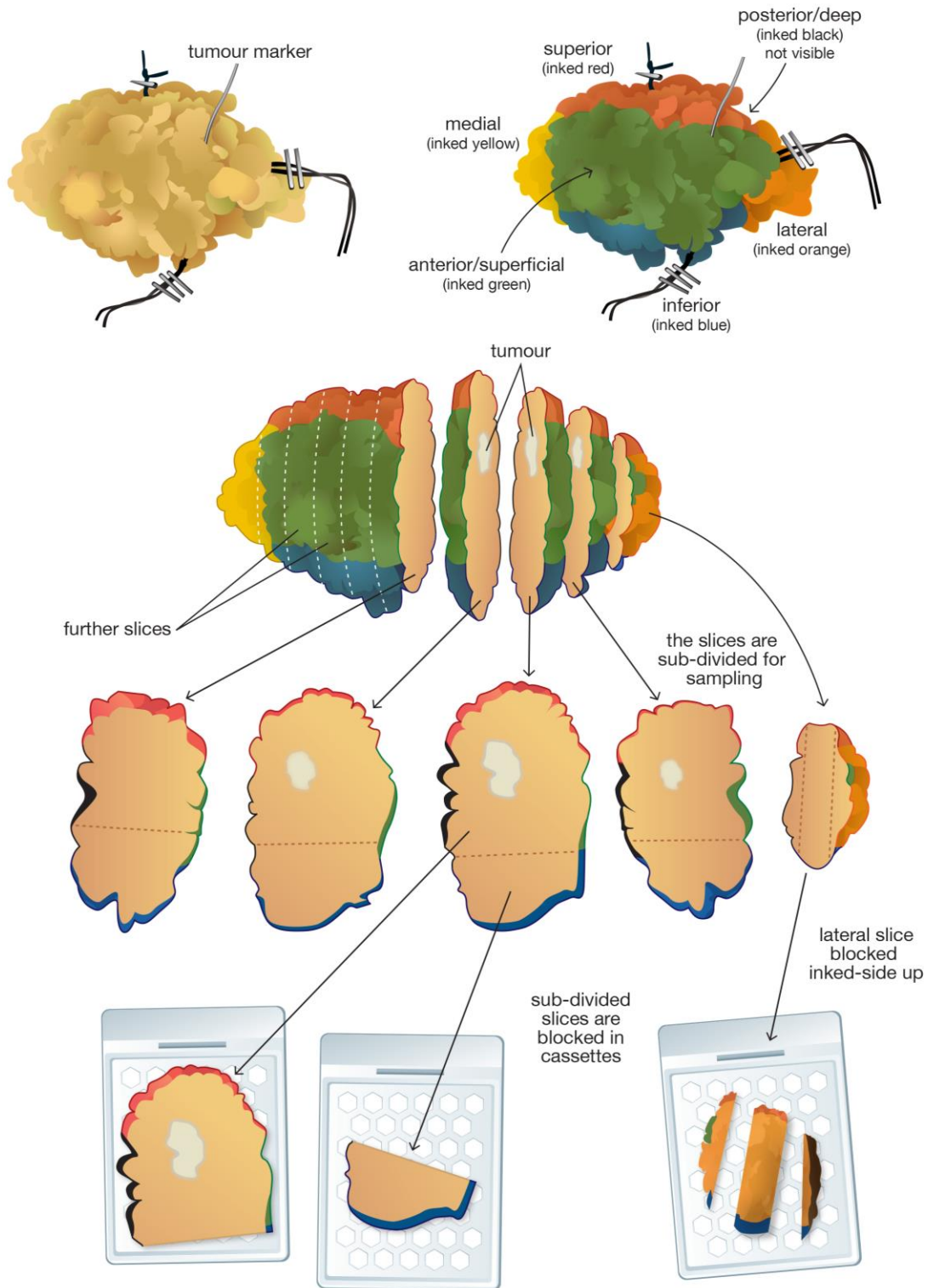


Figure 3a: Sagittal slicing specimen examination method with coloured inks used to indicate specimen orientated margins based on conventional block size

Wide local excision: sagittal slicing

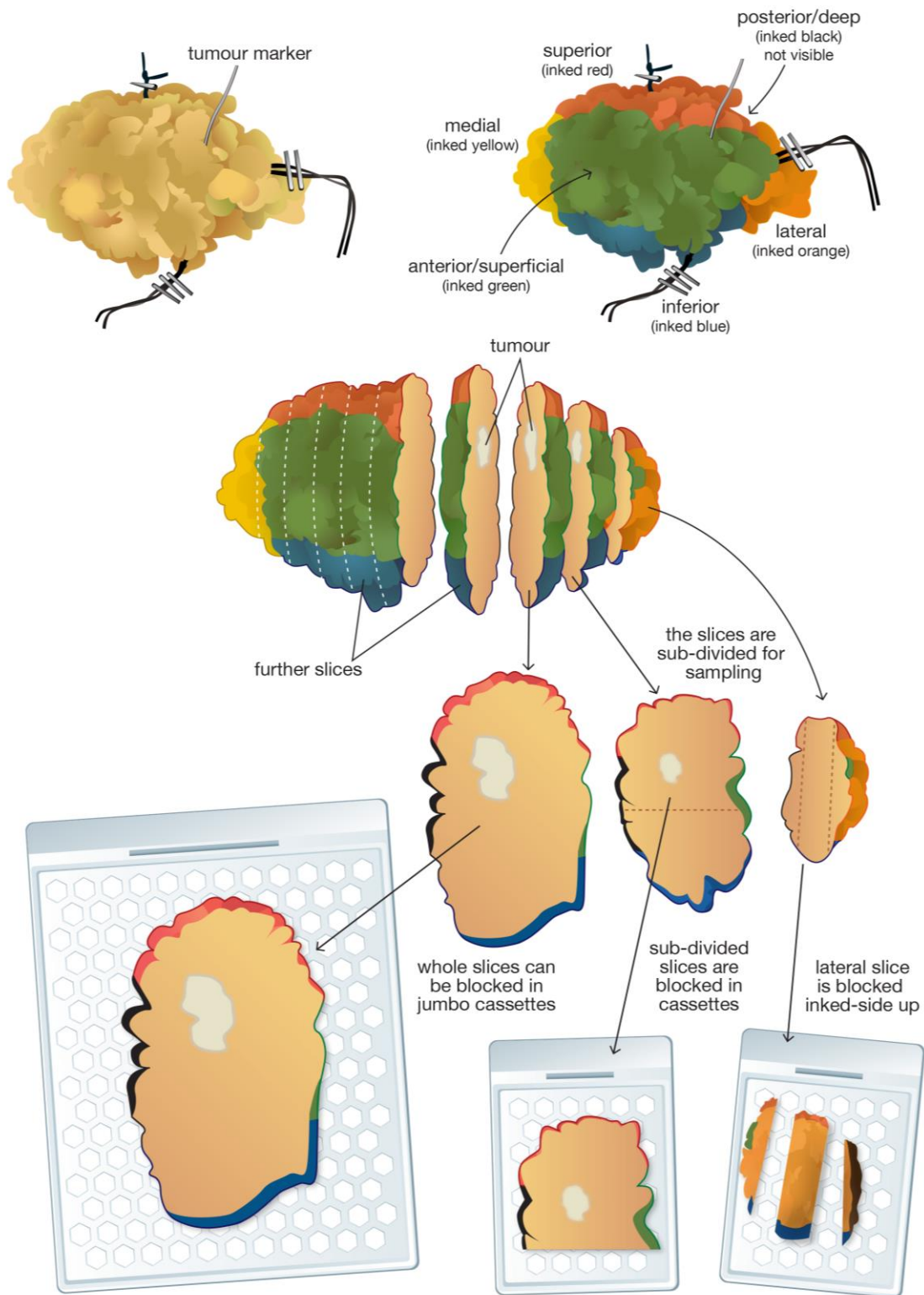


Figure 3b: Sagittal slicing specimen examination method with coloured inks used to indicate specimen orientated margins and use of large blocks

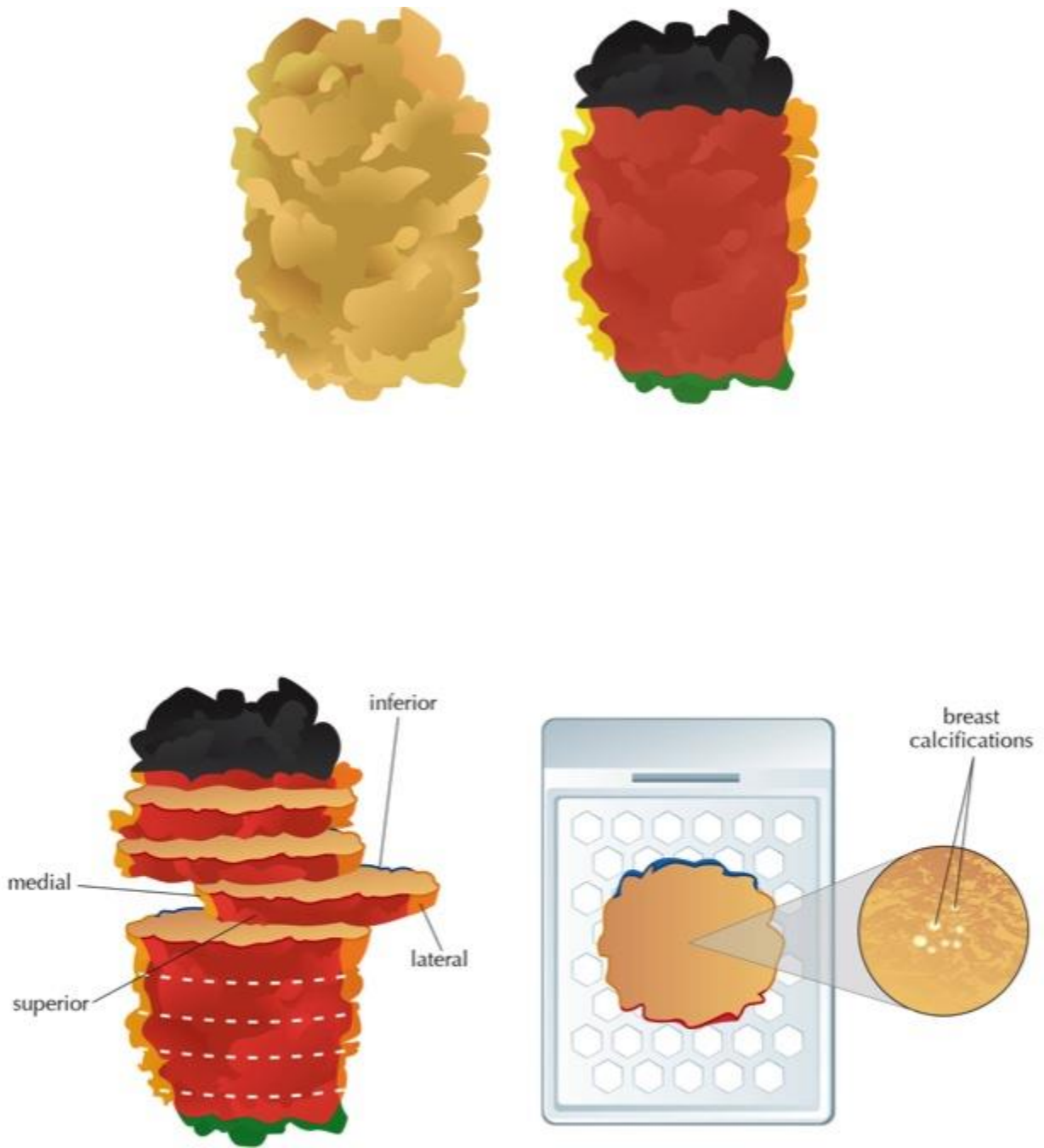


Figure 3c: Sagittal slicing specimen examination method with coloured inks used to indicate specimen orientated margins relating to an area of microcalcification

Wide local excision: coronal slicing with calcifications

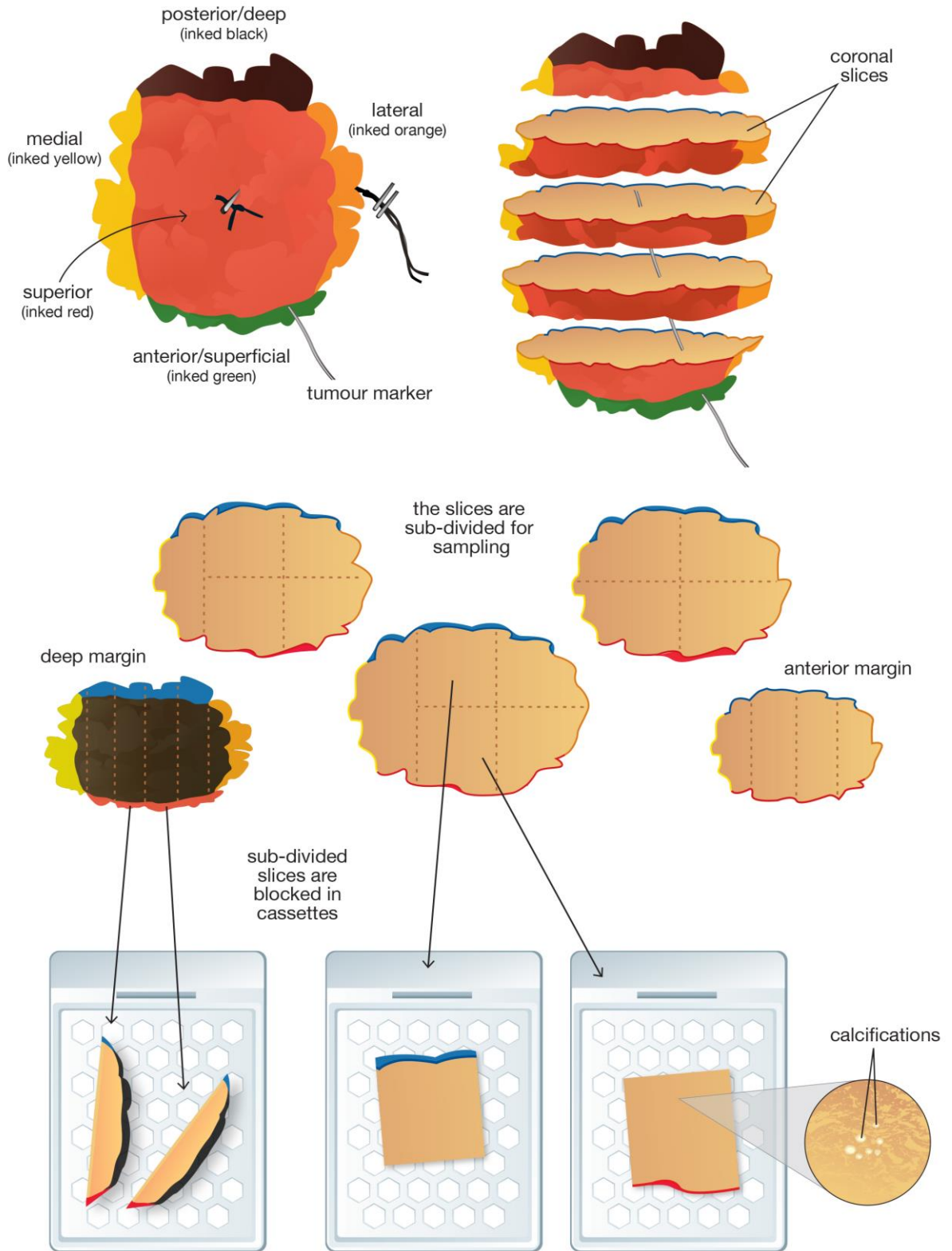


Figure 4: Diagram to illustrate the coronal slicing method with coloured inks used to indicate specimen orientated margins based on conventional block size

1.6.2 Wide local excisions for ductal carcinoma *in situ* (DCIS): presenting as mammographic calcification

- DCIS typically presents as a mammographically detected abnormality, usually calcification, which may not be visible on macroscopic examination of the sliced tissue. Specimens from patients presenting with such lesions will therefore benefit from a combined radiological-pathological approach to diagnosis.
- It is usual for the surgeon when performing a therapeutic operation to take all of the tissue from the subcutaneous aspect to the pectoral fascia.¹ It is essential that the pathologist is informed if the usual surgical protocol has not been undertaken as this will affect the optimum specimen handling methodology, e.g. central excisions, or specimens where breast tissue remains at the deep (posterior) and superficial (anterior) aspects of the excision, and the distance to these margins is thus clinically relevant.
- As noted above, the surgeon should mark the nipple duct margin; DCIS tracks towards the nipple⁴ and, in this plane in particular, can be some distance from the obvious area of microcalcification. It is helpful if the request form indicates the site of the lesion within the breast so that the margin of the specimen nearest the nipple can be identified.
- The specimen should have been X-rayed intra-operatively prior to receipt in order to confirm the presence of the lesion within the specimen. The intraoperative radiographs – whether digital or hard copy film - should be available to the pathologist who should be aware of the size and location within the specimen of the radiological abnormality
- The specimen should be weighed and measured in three dimensions.
- The specimen excision margins should be inked and the specimen can be sliced either before or after fixation. The use of different colour inks/markers on an individual section can assist microscopic identification of specific margins. Inks which are radio-opaque should ideally be avoided if applied prior to slice X-ray.
- If the specimen is large, then incision before fixation is recommended. The specimen should be sliced at intervals of approximately 3–5 mm (see Figure 3c).
- Serial slicing enables specimen slice radiographic mapping of the specimen which provides a high level of confidence that the lesion has been accurately and adequately sampled; slicing and X-raying the specimen slices enables blocks to be taken most accurately from the areas corresponding to the mammographic abnormality as well as from any other suspicious areas identified. This is essential to avoid underestimation of lesion size and overestimation of the distance to specimen margins. Sites of sampling can be annotated on the specimen radiograph for radiological-pathological correlation.
- Macrophotography or schematic diagrams may also assist in recording macroscopic findings and the block map as well as identifying individual sampled margins.
- Sampling may be facilitated by the identification of any radiological marker (e.g. clip, collagen marker or coil). Tissue changes relating to previous core biopsy are an important landmark to indicate sampling of the site of the index lesion and should be recorded in the report, particularly if the whole abnormality was removed by the cores.
- The macroscopic and or radiographic lesion should be described and its size in three dimensions and distance to margins recorded.
- The number of blocks taken will depend on the size of the specimen and the size of the abnormality. If the specimen is small, or if slice radiology unavailable, it is best to block and examine all of the tissue. Samples 30 mm or less in maximum dimension should be completely sliced, embedded and examined histologically. The site of all blocks taken should be recorded.
- For larger specimens sampling should include the extremes of the radiographic calcification and adjacent tissue in order to avoid underestimation of the size of the lesion. This is particularly important for microcalcifications associated with DCIS, as it is

recognised that mammographic size may be an underestimate of the true lesion size. Representative samples from the entire involved area should be taken. Sufficient blocks should be taken to identify associated invasive carcinoma if present. Samples should include areas of breast tissue from proximal (towards the nipple) and distal to the calcification, as DCIS extends more frequently in this plane.⁴ Defining the minimum number of blocks that should be taken remains unclear, however it is recommended that one to two block per 10 mm of the maximum dimension of the area of calcification be taken. Measurement can be made in this way from the most distal involved duct across the main area of calcification to the most proximal involved duct (see section 1.6.2).

- Many units use large blocks to embed the entirety of segmental excisions although the proper processing of these can delay the reporting of the case and storage may also be problematic; units should therefore take a pragmatic approach.
- All surgically relevant margins of therapeutic excision specimens should be sampled. This will include all radial/circumferential margins (superior, inferior, medial, lateral and nipple margins), and the deep (posterior) and superficial (anterior) if dictated by local protocol or by the surgical procedure from an individual patient. Particular attention should be paid to the margin nearest the mammographic abnormality and the margin nearest the nipple.
- If therapeutic samples are sent in more than one portion, it can be extremely difficult to measure the absolute largest extent of the whole lesion present. In these cases, it is appropriate to measure the maximum distance in any piece of tissue and to add the dimensions to give an estimated total size. If, however, the orientation of the specimens can be determined, the size can be ascertained more reliably.

1.6.3 Cavity shave/biopsy specimens

- The circumferential edge of a wide local excision specimen can be shaved and examined by the pathologist to allow more extensive examination of the relevant surgical resection margins. This is typically done after taking the radial tumour blocks. This can produce a series of additional blocks including: superior shave, supero-lateral shave, lateral shave, infero-lateral shave, inferior shave, infero-medial shave, medial shave and supero-medial shaved edge, depending on the size of the specimen. As closer margins than previously accepted as adequate are now being applied (e.g. 1mm or being considered sufficient in many Centres) it is recommended that shave margin specimens <1mm thick are sliced perpendicular to the new margin face so that the distance to margins can be recorded.
- The surgeon may provide separate cavity shaves, which may be submitted to the laboratory as 'bed biopsies'. The site of each specimen should be clearly labelled and each specimen examined separately.
- Cavity shave specimens should be distinguished from more substantive margin re-excision specimens.
- Cavity shave specimens submitted by the surgeons are generally a sheet of fibroadipose tissue with marker suture or other marking on one surface. After weighing and measuring, paying particular regard to their thickness, their new external surface should be inked, taking great care not to ink the internal margin.
- Cavity shaves should be blocked out in total where feasible. If of a larger size, such that this is impractical, they should be sliced and the densest or most suspicious areas blocked out, block sampling should focus on the new margin region. It is recommended that such specimens are sliced perpendicular to the new margin face; if the specimen is small all slices can be blocked together as one or two blocks whilst for larger specimens a representative sample of slices should be blocked.

Immediate re-excision specimens should be dealt with as described below.

1.6.4 Re-excision specimens

If a radiological abnormality extends close to a margin on an intraoperative specimen radiograph, the surgeon may undertake an immediate re-excision of that particular margin. Similarly, if there is a surgically palpable abnormality extending close to a margin intraoperatively during the operation, the surgeon may undertake an immediate re-excision of that particular aspect. A separate re-excision specimen may therefore be taken either¹ at the time of initial surgery,² subsequent to the discovery of incomplete excision in a therapeutic excision or³ following diagnostic localisation biopsy. The aim of such a procedure is to remove either all of the previous biopsy site and its margins, or one or more specific margins known, or suspected, to be involved by the disease process. Whenever re-excision has been performed, the surgeon should orientate the re-excision specimen.

- Re-excision specimens can be weighed and serially sliced at 3–5 mm.
- Blocks taken should be recorded in such a way as to permit accurate assessment of the adequacy of excision and size of any malignant lesions identified.
- It is difficult to be proscriptive regarding the extent of block sampling as the nature and size of these specimens varies; the focus should be on the new excision margin rather than exhaustive detection of residual disease.
- If re-excision specimens have been taken which contain further tumour, it can be extremely difficult to determine the absolute size of lesion. A pragmatic approach is required, and the maximum distance in each piece of tissue can be measured and added to give an approximate total size of tumour. If, however, the orientation of the specimens can be determined, the size of tumour can be ascertained more reliably.
- The pathologist should measure the distance of any additional tumour present to the new margin of excision, or to approximate the distance of the original tumour to the new margin of excision if no tumour is present.

1.7 Mastectomy specimens

1.7.1 Mastectomy specimens for invasive carcinoma: presenting as mass lesion (Figures 5a and 5b)

- Invasive carcinomas typically present as mass lesions, which may or may not be clinically palpable, and are usually visible radiologically and macroscopically in the resected tissue. The location of the tumour or tumours should be stated on the request form or indicated in a diagram.
- A method should be employed to ensure rapid fixation of the tumour and the rest of the specimen. Ideally, this will be on receipt of the fresh specimen in the pathology laboratory, allowing immediate incision of the tumour and slicing of the breast prior to placing in fixative. If resources do not permit such a procedure, then alternatives must be employed, e.g. the surgeon may incise the specimen in a controlled way as described in section 1.3. Some centres have adopted a fixative injection methodology to assist in fixation of larger mastectomy specimens. Good fixation is vital to preserve the morphological detail. Mastectomy specimens for invasive carcinoma should not be allowed to fix without prior incision of the tumour. Poor tumour preservation precludes assessment of dataset details such as histological grade and lymphovascular invasion and can result in false negative biomarker (e.g. hormone receptor) assessment. Specimens must be placed in sufficient formalin inside an appropriately sized and shaped container either before or, preferably after, receipt by the laboratory.
- Procedures for management of radioactive materials and specimens are at the sole discretion of the Local Radiation Protection Officer. However, it has been shown that from a radiation protection risk perspective, there is no reason why radiolabelled specimens in pursuit of sentinel node biopsy should not be handled and/or dissected

without any imposed delay, so low is the radiation exposure from these. Further, those who handle them do not need to be registered as Radiation Workers.² Aside from the pathology dissection issues, the local Radiation Protection Office will make stipulations about transport of specimens to the laboratory, and about discharge of radioactive material into the waste system, with which the laboratory will need to comply.

- The tumour is conventionally incised from the deep (posterior) fascial plane in the sagittal plane at a maximum of 10 mm intervals after inking, e.g. with India ink (Figure 5). Differential colour marking of anterior, posterior and radial surfaces may facilitate orientation both prior and subsequent to block taking in skin-sparing mastectomies. Slicing in the coronal plane from deep (posterior) to anterior (superficial) (Figure 6) may be appropriate in some cases, particularly where it may facilitate correlation with imaging findings.
- Alternatively, the centre of the tumour may be incised from the deep (posterior) fascial plane in a cruciate fashion allowing the tumour to be sampled as well fixed blocks, which include the anterior-posterior, medial-lateral and superior-inferior dimensions (Figures 2a and 2b).
- The apparently normal portion of the mastectomy specimens should also be sliced at 10mm intervals and examined by eye and palpation to identify any additional abnormalities. These should be described and sampled and their position relative to the main mass lesion recorded.

Details of the macroscopic appearances of the specimen should be recorded including:

- Tumour size in three dimensions
- If multiple tumours are identified, the distance between tumours should be measured and dimensions of each tumour recorded. It is recommended that the tissue between tumour deposits is sampled to ascertain if the foci are truly separate or, for example, arising within a large area of *in situ* carcinoma.
- It is not possible to be proscriptive but sufficient blocks of the tumour should be taken in order to accurately assess important primary characteristics, e.g. grade, type and presence of absence of lymphovascular invasion. The number of tumour blocks taken will vary with tumour size and relate to specimen examination method (Figures 3 or 5). The edges of the tumour with surrounding uninvolved tissue should also be examined to identify associated DCIS not visible to the naked eye and permit an assessment of whole tumour size and to search for the presence of lymphovascular invasion.
- Slice specimen radiography may be required to identify calcifying DCIS associated with small invasive carcinomas or located elsewhere in the specimen. This may have been detected preoperatively and identification may be facilitated by the presence of a radiological marker clip, collagen marker, or coil and by macroscopic changes relating to previous core biopsy.
- The number of conventionally sized blocks taken from the main tumour area per specimen will vary with tumour and specimen size.
- Large blocks may be very helpful in determining the presence of multiple invasive foci, and whole tumour size, i.e. including surrounding DCIS.
- In addition to areas corresponding to radiological or macroscopic abnormalities, the lateral end of the specimen should be examined by eye and palpation for the presence of intramammary or low axillary lymph nodes.
- The nipple should be examined macroscopically and histologically in cases with clinical evidence of Paget's disease.
- Should resources permit, representative sampling of the nipple-areolar complex can be performed to ensure adequate assessment of co-existing DCIS size and to determine the presence of occult mammary Paget's disease.

- The best method to assess nipple duct involvement by DCIS is a coronal section through the nipple which allows visualisation of all nipple ducts in one cross-section. A sagittal section through the skin of the nipple can be taken to exclude occult Paget's disease (see Figures 5a, 5b, 5c).
- Measuring the distance of the tumour from the nipple can facilitate determination of whole tumour size if the nipple ducts are subsequently found to contain DCIS.
- Any other abnormality in the background breast tissue should be sampled.
- Additional sampling of quadrants can be performed if resources permit as these can assist in the identification of occult extensive disease.
- The margins of a mastectomy specimen should be examined histologically if the tumour is very close to or abutting a margin; this includes the anterior margin of skin-sparing mastectomies.

1.7.2 Mastectomy specimens for ductal carcinoma *in situ* (DCIS) presenting as mammographic calcification

DCIS usually presents as a mammographically detected abnormality, most often calcification, which may not be visible on macroscopic examination of the sliced tissue. In mastectomy specimens from patients presenting with such lesions a combined radiological-pathological approach to diagnosis is essential.

- Some mastectomy specimens will be skin sparing procedures and include only a small amount of skin around the nipple anteriorly. All mastectomy specimens should be orientated by the surgeon, e.g. by placing a suture in the axillary tail and/or the superior edge of the skin anteriorly.
- The posterior aspect of the specimen is conventionally painted, e.g. with India ink.
- Some centres find differential colour inking of anterior, posterior and radial margins helpful to preserve orientation both before and after block taking if the mastectomy is a skin sparing procedure.
- The specimen should be incised as soon as possible after resection at approximately 10mm intervals in the sagittal plane to permit rapid fixation of the specimen and this is essential if the specimen contains a mass lesion likely to correspond to an invasive carcinoma (see above).
- Slicing in the coronal plane may be appropriate in some cases particularly where it may facilitate correlation with imaging findings.
- Removal or incision of the nipple for separate fixation prior to dissection may facilitate subsequent block taking.
- After adequate fixation, and further slicing if required, it can be very helpful to x-ray the specimen slices to facilitate identification and accurate sampling of the radiological abnormality.
- Accurate localisation of the lesion(s) may be facilitated by the presence of a radiological marker clip, collagen marker, or coil and by the identification of macroscopic changes relating to any previous core biopsy.

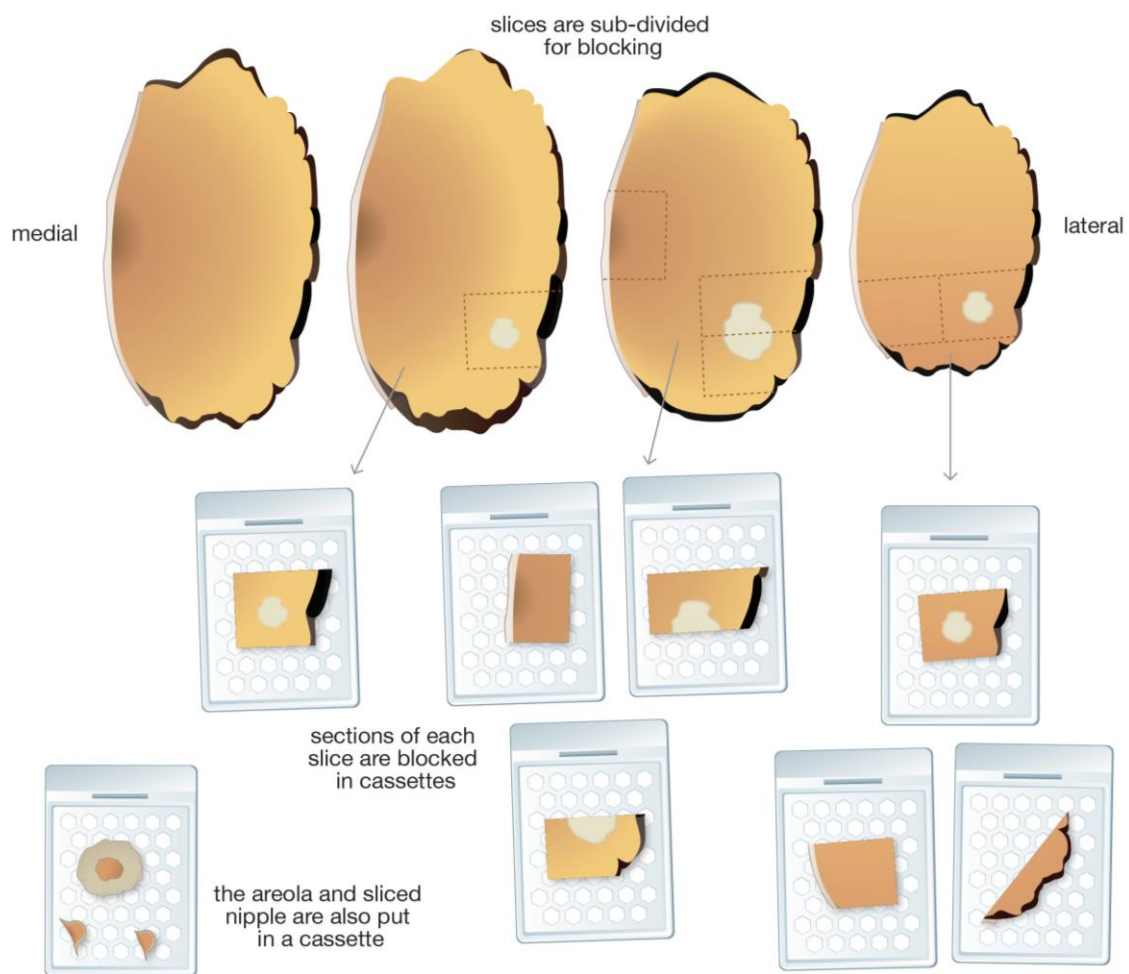
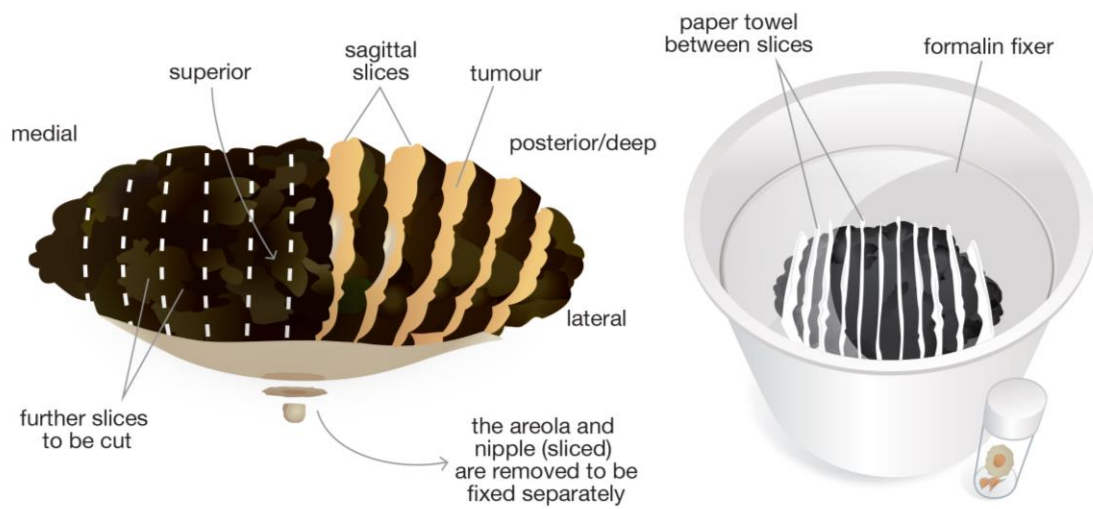


Figure 5a: Mastectomy specimen examination using sagittal slicing to assist specimen fixation and block sampling

Mastectomy (left): sagittal slicing

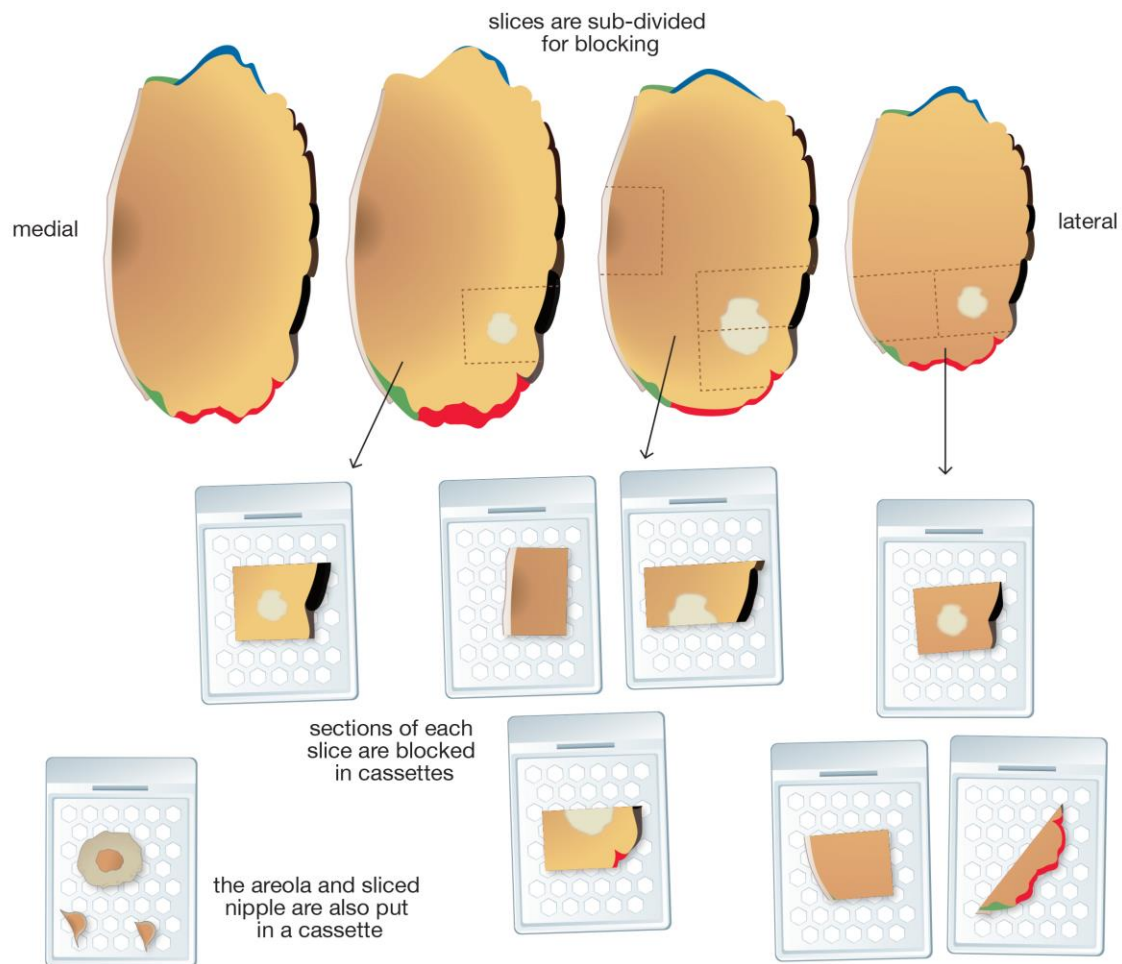
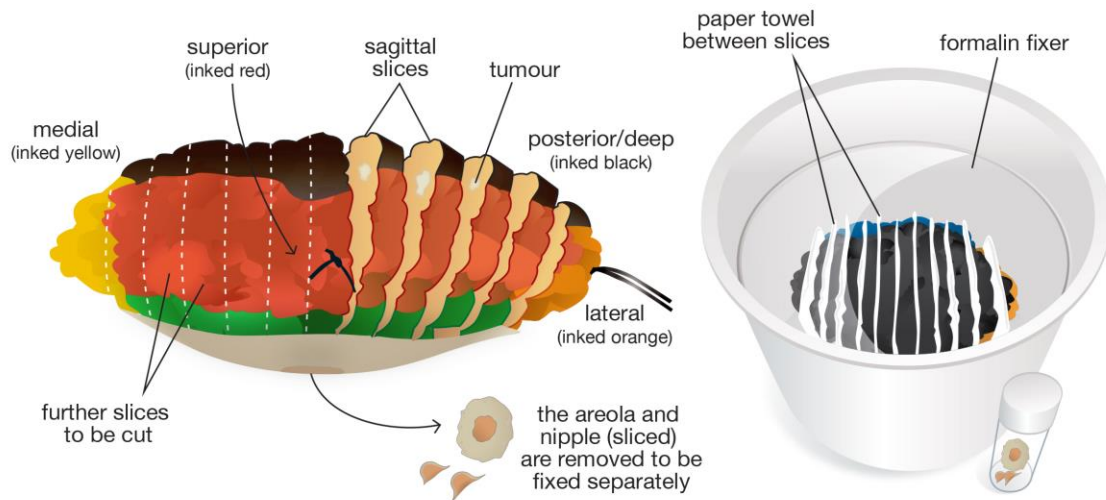


Figure 5b: Mastectomy specimen examination using sagittal slicing to assist specimen fixation and block sampling with use of ink to support specimen margin orientation if required

Mastectomy (left): coronal slicing (skin sparing)

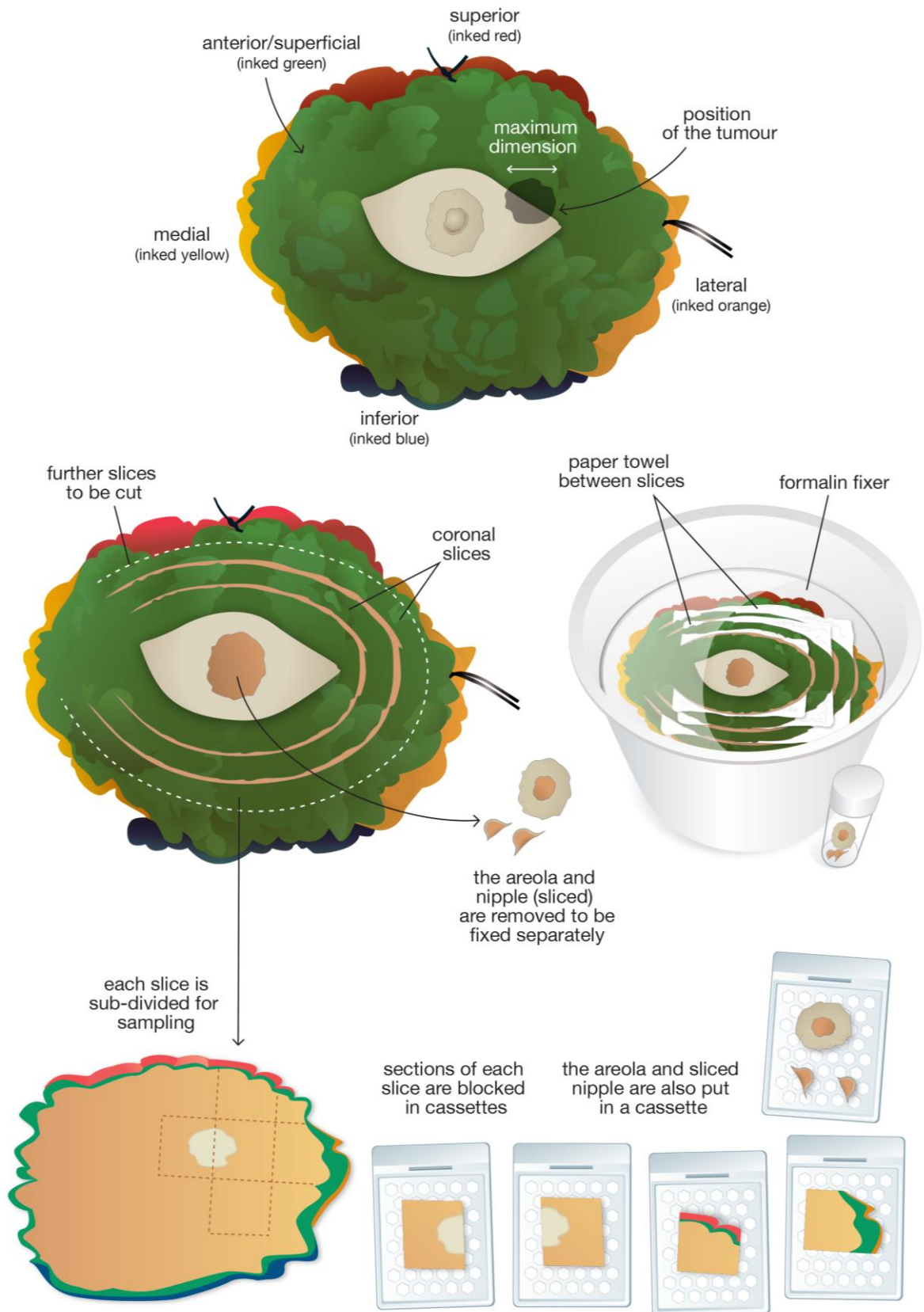


Figure 5c: Mastectomy specimen examination using coronal slicing to assist specimen fixation and block sampling with use of ink to support specimen margin orientation if required

- The extent of sampling will depend on the radiological size of the lesion. Sampling should include the extremes of the radiographic calcification and adjacent tissue in order to avoid underestimation of the size of the lesion. This is particularly important as it is recognised that mammographic size may be an underestimate of the true lesion size of DCIS. It is anticipated that patients undergoing mastectomy for DCIS will in general have larger DCIS lesions with a greater probability of occult invasive cancer being present. It is therefore suggested that a minimum of 1 to 2 conventional blocks per 10 mm of calcification be taken.
- Any mass should be sampled thoroughly to exclude an associated invasive component.
- Large blocks may be helpful in assessing large areas of DCIS and determining extent more accurately.
- In addition to areas corresponding to the radiological abnormality, the apparently normal portion of the mastectomy specimens should be sliced at 10 mm intervals and examined by eye and palpation to identify any other additional abnormalities. These should be described and sampled and their position in relation to the main lesion recorded.
- The lateral end of the specimen should be examined by eye and palpation for the presence of intramammary or low axillary lymph nodes.
- Representative sampling of the nipple-areolar complex should be performed to ensure adequate assessment of DCIS size and to determine the presence of mammary Paget's disease. This can include a coronal section through the nipple or immediately subareolar tissue to allow visualisation of all nipple ducts in one cross-section and a sagittal section through the surface skin of the nipple and subareolar tissue. Measuring the distance of the tumour from the nipple can facilitate determination of size of lesion if the nipple ducts are subsequently found to contain DCIS.
- Additional sampling of quadrants can be performed if resources permit as these can enable identification occult extensive disease.

1.7.3 Completion mastectomies (following incomplete excision in a wide local excision)

- The specimen should be fixed, inked and sliced as detailed above. The site of the previous surgery will usually be apparent as a cavity lined by haemorrhagic granulation tissue and fat necrosis or an area of scarring.
- Sections should be taken from the walls of the cavity, focussing on any margins previously identified as close/involved in previous surgical specimen(s) and any macroscopically suspicious areas. Reference to previous reports will identify close/involved margins and these areas should be particularly thoroughly sampled.
- The nipple can be sampled as described above.
- Sections from other quadrants should be taken if any suspicious areas are noted macroscopically.

1.8 Therapeutic excision and mastectomy specimens for invasive carcinoma following neoadjuvant chemotherapy: macroscopic handling

Some patients with high-grade, large, locally advanced or inflammatory breast cancers may receive chemotherapy prior to surgery. This permits an assessment of tumour responsiveness to the chemotherapy and may result in tumour down-staging, i.e. a reduction in tumour size and/or nodal involvement.

- The macroscopic handling of breast excision specimens following neoadjuvant (primary) therapies can be difficult, particularly if there has been a good, or complete, response to the systemic treatment. This is especially the case for the post-

neoadjuvant chemotherapy specimen, when the situation is more common than following primary endocrine therapy.

- The proper pathological approach to such specimens is therefore crucially dependent on knowledge of the previous clinical, imaging and pathological findings, including tumour type and grade and the location of the tumour within the breast. The difficulties in identification of the tumour bed are exacerbated if limited clinical information is provided, for example, if mastectomy is performed and details of the original location of the lesion is not provided on the request form by the surgeon. Multiple invasive foci similarly may be missed if inadequate information is given to the pathologist.
- The initial laboratory handling of post-chemotherapy specimens should be undertaken in a similar manner to wide local excision or mastectomy specimens from patients not receiving such treatment.
- Specimens from post neoadjuvant chemotherapy cases should be orientated as described above for other specimens and as per local protocol and sent to the laboratory.
- Adequate and prompt fixation is as important here as in any other breast specimen.
- A marker may be inserted into the tumour prior to starting treatment and its localisation within the excised breast tissue can help determine the site of tumour bed. In order to ensure that this tumour site is completely removed some units mark the skin to delineate the tumour size prior to treatment and this can also be helpful. In essence, for these specimens close working with the other members of the multidisciplinary team is vital.
- On palpation and slicing, a mass lesion may be obvious if there has been incomplete response to neoadjuvant therapy and the specimen can be handled as for any other primary resection specimen. When there has been a decrease in tumour size compared with original imaging, additional blocks should be taken from around the residual mass to encompass the pre-treatment area of involvement.
- If there has been a significant tumour response, the lesion may be difficult to identify, both with the naked eye and by palpation; a pale, ill-defined, soft, oedematous area of fibrosis may be all that can be detected. With a good or complete pathological response (pCR) there may only be a vague impression that the tissue architecture is abnormal (pathologically and radiologically). In such cases the marker, or residual microcalcification, can be seen in specimen X-ray and direct the attention of the pathologist to the appropriate area. Often the marker can be detected macroscopically on thin slicing of the specimen.
- The tumour bed (as identified by the location of the radiological marker, in conjunction with clinically described site and macroscopic recognition of corresponding mass or area of fibrosis) should be thoroughly sampled in order to detect residual disease and allow for assessment of the tumour bed in three dimensions.
- For large tumours where cruciate blocks cannot easily be taken, assessment of the tumour bed can be achieved by estimation of slice thickness and the number of consecutive blocks involved, along with the two dimensions seen histologically.
- A tumour that has responded to chemotherapy may regress focally and appear as multiple apparently separate foci. Blocks should therefore be taken to include the entire tumour bed as residual tumour foci may as a consequence be scattered throughout it.
- Large blocks, if available, are very useful in preserving the tissue architecture. They can facilitate the assessment of multiple foci of invasive carcinoma and the assessment of the amount of residual tumour in relation to the tumour bed, thus aiding an assessment of tumour response.
- The margins of therapeutic wide local excision specimens post neoadjuvant chemotherapy should be sampled particularly thoroughly.

- Lymph nodes should be blocked as per the guidelines for those patients who have not received neoadjuvant therapy, depending on the surgical procedure (i.e. sentinel lymph node or axillary clearance). Like the lesion in the breast, lymph nodes may also be more difficult to identify macroscopically after neoadjuvant treatment; some patients may have had a pre-treatment sentinel lymph node biopsy and others may be known to have metastatic disease (confirmed by pre-operative, pre-therapy ultrasound guided FNAC or core). In both such situations macroscopic assessment of the lymph nodes may be difficult. There is also some evidence that there is a decreased yield of nodes in patients who have received neoadjuvant chemotherapy.⁵

1.9 Oncoplastic specimens

The concept of oncoplastic surgery combines the aim of completely removing the patient's breast cancer whilst maintaining breast aesthetics by achieving a good cosmetic outcome. Whilst such surgery includes mastectomy with total reconstruction, a variety of techniques for partial reconstruction of wide excision defects can be used which allow the surgeon to remove large portions of cancer-bearing tissue without compromising cosmesis. Such wide local excision specimens may contain larger tumours than could classically be removed by complete local excision or the aim of the procedure may be to achieve wider tumour-free margins than could otherwise be obtained.

The principles of examining oncoplastic wide local excisions are the same as for conventional specimens. The carcinoma is sampled in the same way. The tumour is usually further from the margins, so that less thorough sampling of the margins is needed. Specifically, shave sections of a margin can be avoided if the lesion is more than 30 mm from that margin as it is extremely rare for disease (invasive carcinoma or DCIS) to be identified in that shaved aspect without clear evidence of multifocal or occult extensive disease identified which will be detected using radial blocks or serial slicing methods³ Similarly sampling of re-excision specimens can be limited unless the carcinoma is close to the relevant margin of the main excision specimen.

Contralateral breast reductions specimens from patients with breast cancer, and prophylactic mastectomies from those at high risk, should be sampled more thoroughly than for cosmetic breast reductions, as the likelihood of identifying a risk or precursor lesion is higher. Tissue removed from non-oncoplastic cosmetic breast procedures are generally submitted for pathology examination. It is recognised that there is a risk of identification of detection of invasive cancer, *in situ* carcinoma or atypical hyperplasia in such specimens, albeit at very low frequency. The risk of such abnormalities appears to be higher in patients over the age of 40. Such specimens should be carefully visual inspected, manually palpated and sliced at between 5 and 10 mm thickness. Abnormal areas should be sampled for pathological examination. It is recommended that a minimum of two tissue blocks is taken for histological examination. Block sampling should be targeted towards white fibrous, potentially parenchymal rich and non-fatty tissue. In patients with prominent fibrous breast tissue and those of over the age 40, additional block sampling can be considered. Recommendations on handling other breast specimens (e.g. major duct excisions) can be found in the RCPATH's tissue pathways guidance.

1.10 Pathological examination of lymph nodes

Resected lymph nodes, usually axillary and occasionally internal mammary, should be submitted for microscopic examination. These specimens may take the form of axillary clearance specimens, axillary lymph node samples or sentinel lymph node biopsies.

1.10.1 Sentinel lymph node and lymph node sample specimens

- Designated individual lymph node specimens should be identified separately from the breast sample and placed in clearly labelled specimen containers for routine fixation.

- Each lymph node identified should be examined and blocked independently for histological examination.
- If surrounding fat is removed prior to slicing, care should be taken not to damage the capsule or slice into nodal tissue leading to overestimation of the number of lymph nodes present.
- The method used should provide the highest chance of finding metastatic disease by conventional microscopic examination of haematoxylin and eosin (H&E) stained tissue sections.
- A representative complete section of any grossly involved lymph node is adequate.
- Lymph nodes greater than 4 mm in maximum size should be sliced at intervals of 2 mm or less perpendicular to the long axis; this is an effective and simpler alternative to serial sectioning to detect small metastatic deposits in lymph nodes (Figure 6).
- All of the tissue blocks prepared should be embedded and examined histologically; for larger lymph nodes, this may necessitate examination as more than one paraffin block.
- Lymph nodes less than 4 mm should ideally be bisected, and blocked in their entirety.
- Examination of levels is not routinely necessary. It may be performed if small groups of worrisome cells are identified, if initial sections do not achieve a full-face section, and to determine the maximum size of any metastatic deposits.
- Immunohistochemistry may be helpful if there are cells suspicious of carcinoma seen in the H&E section. Immunohistochemistry for broad spectrum cytokeratins, clone AE1/AE3, is currently recommended.⁶ Reactivity of dendritic reticulum cells and some lymphoid cells may lead to false positive results when using some cytokeratin antibodies and assessment must therefore be based on immunoreactivity and morphological correlation (see Appendix G).

Sentinel Lymph Node: slicing perpendicular to the long axis

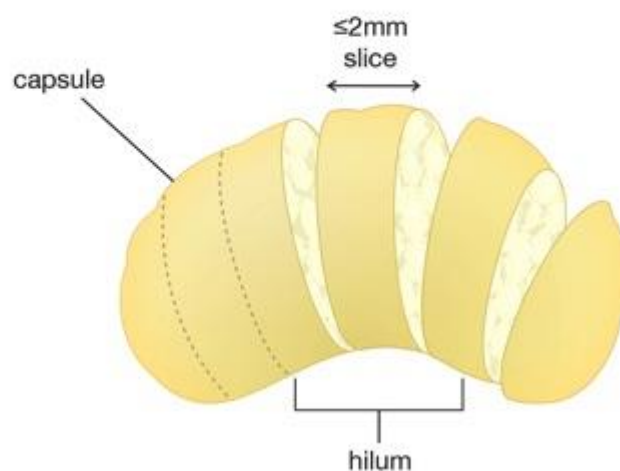


Figure 6: Diagram to illustrate lymph node slicing perpendicular to the long axis

1.10.2 Axillary clearance specimens

- Histopathological examination should be performed on all lymph nodes received, and the report should state the total number of lymph nodes and the total number containing metastasis.
- Axillary clearance specimens should be placed in clearly labelled containers with sufficient formalin for routine fixation.

- Axillary node specimens received with mastectomy or surgical excision specimens should be examined carefully to maximise lymph node yield. This is usually achieved by manual dissection of fixed axillary tissue with careful examination by inspection and palpation. The yield of lymph nodes may be high in such samples. The use of clearing agents or Bouin's solution may increase lymph node yield; however, this is time consuming and expensive and is not regarded as essential.
- Axillary lymph nodes may be softer and more difficult to palpate in post chemotherapy specimens and lymph node yields may be lower.⁵
- An axillary clearance specimen can be divided into three levels if the surgeon has marked the specimen appropriately.
- The apical lymph node should be separately examined, if identified surgically.

Tissue blocks

a) Minimum standard method

- every lymph node identified should be examined histologically
- the method should ensure that the total number of lymph nodes should be assessable; this necessitates a minimum examination of at least one slice of tissue from each node
- this minimum standard allows examination of multiple lymph nodes as composite blocks.

b) Ideal methodology

- each lymph node should be blocked and examined as described above in section 1.10.1 for sentinel lymph node and axillary lymph node samples.

1.10.3 Intraoperative examination of lymph nodes

Intraoperative assessment of lymph nodes is not regarded as routine but is undertaken in some centres to identify patients with metastasis in sentinel lymph nodes who may thus have axillary node clearance as a single operative procedure. A number of methodologies can be employed including frozen section, imprint cytology and molecular techniques.

The future role and value of intraoperative assessment has, to some extent, been influenced by the results of, and clinical questions raised by, the American College of Surgeons Oncology Group Z0011 trial.⁷ Although the histopathological assessment of lymph nodes, as well as other pathological features, of patients included in this trial is poorly described/missing (as an example 28% of those patients in the sentinel lymph node biopsy arm had unknown histological grade and 7% in this arm were actually node negative), clinicians in the UK are questioning the need for axillary clearance in those patients with low volume nodal metastatic disease in particular. For this reason, and because of the success of ultrasound-guided sampling of abnormal axillary lymph nodes, there may be less demand for intraoperative detection of micrometastatic disease in lymph nodes in the future.

1.10.3.1 Frozen section examination and touch imprint cytology

Frozen section examination of lymph nodes for metastatic carcinoma detects about 70% of metastases (about 90% of macrometastases and 40% of micrometastases).⁸ Meta-analysis of touch imprint cytology shows an overall sensitivity of 63%. However, not surprisingly, the sensitivity for detection of micrometastases is 22%, compared to that for macrometastasis of 81%.⁹

One particular circumstance in which intraoperative assessment is reasonable is when a sentinel node has a macroscopic appearance highly suspicious of metastatic carcinoma.

1.10.3.2 Molecular techniques

Two molecular assays have been widely tested, but only one of these, one-step nucleic acid amplification (OSNA), is still commercially available.¹⁰ Conventional histology has excellent specificity, but may miss small metastases. OSNA has about 96% agreement with alternate slice histology. The OSNA assay was formally approved by NICE in August 2013. NICE stated: “Whole lymph node analysis using the RD-100i OSNA system is recommended as an option for detecting sentinel lymph node metastases in people with early invasive breast cancer who have a sentinel lymph node biopsy and in whom axillary lymph node dissection will be considered. The accuracy of histopathology in any setting could not be 100% because time and resources did not allow every slice of a node to be analysed for metastases. Whole node analysis should be fully implemented in local clinical practice to reduce the risk of tissue allocation bias.”

After intraoperative assessment, any residual sentinel lymph node should be examined as in section 1.10.1, above.

2 Classifying benign lesions

This section should be used to classify benign lesions identified in excision specimens. Most pathologists do not sub-classify and report benign conditions co-existing with established *in situ* or invasive carcinoma unless directly relevant (for example as explanation of radiological abnormality).

2.1 Solitary cyst

This term should be used when the abnormality appears to be a solitary cyst (Figure 7, top left). The size is usually greater than 10 mm and the lining attenuated or apocrine in type. The latter may show papillary apocrine change, which should be indexed separately under epithelial proliferation of appropriate type. If multiple cysts are present, it is better to use the term ‘fibrocystic change’ (see below). Papillary lesions associated with cystic change should not be entered here but under papilloma or carcinoma.

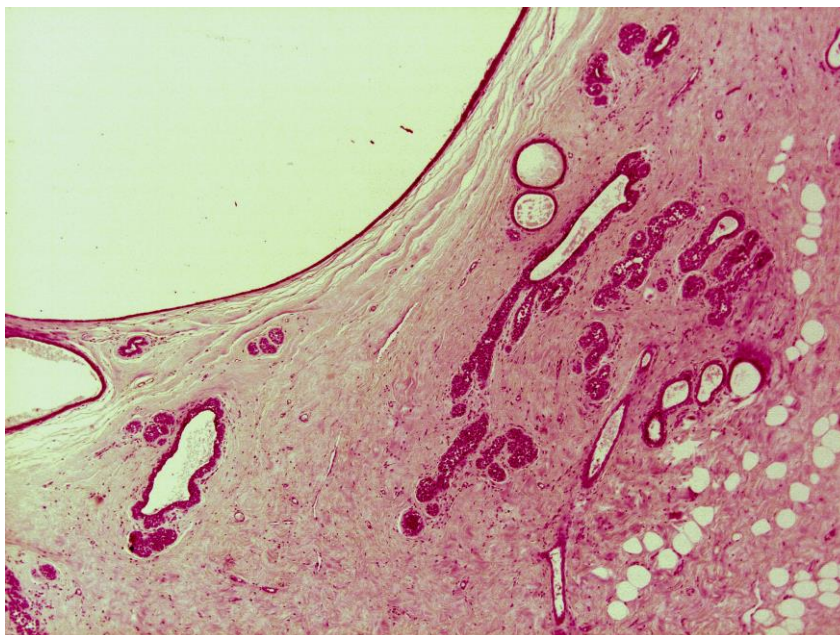


Figure 7: A benign simple cyst with mild atypical lobular hyperplasia found as an incidental finding in the adjacent breast tissue

2.2 Fibrocystic change (Figures 8a, 8b, 8c and 8d)

This term is used for cases with a constellation of benign features including cysts, some of which may be lined by apocrine epithelium, fibrosis, usual epithelial hyperplasia, and columnar cell change. The term is not intended for use with minimal alterations such as fibrosis, microscopic dilatation of acini or ducts, lobular involution and minor degrees of columnar cell change. These changes should be indexed as normal.

It is not intended that cystic change or apocrine metaplasia occurring within other lesions such as fibroadenomata, papillomata or sclerosing lesions should be coded here.

Apocrine metaplasia occurring in lobules without cystic change may produce a worrisome appearance, occasionally mistaken for carcinoma. This change should be specified as 'apocrine adenosis' under other benign lesions. Apocrine adenosis is used to refer to apocrine change within sclerosing adenosis.

Papillary apocrine hyperplasia (Figures 8c and 8d) should be indexed separately under epithelial proliferation with or without atypia, depending on its appearance. Apocrine epithelium lining cysts may show a variety of architectural patterns: simple, complex (with small papillae) or highly complex (with interconnecting bars and bridges). It should be noted that apocrine cells often exhibit a degree of pleomorphism greater than is seen in normal breast cells. Hyperplasia should therefore be regarded as atypical only when the cytological changes are significantly more pronounced than usual with a greater than three fold variation in nuclear size. If atypia is deemed sufficient to warrant a diagnosis of atypical apocrine hyperplasia (record as atypical ductal hyperplasia) or apocrine DCIS (record as DCIS), this should be recorded separately on the screening form.

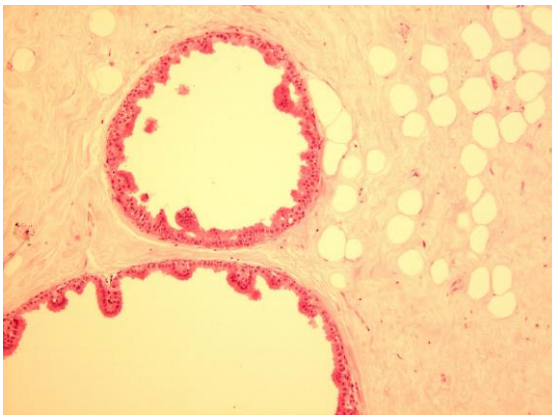


Figure 8a: Simple benign apocrine change

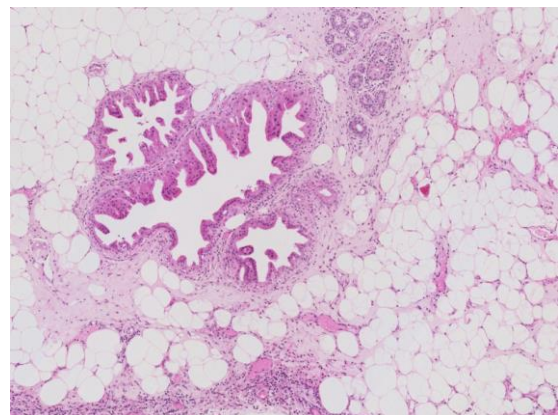


Figure 8b: Papillary apocrine change

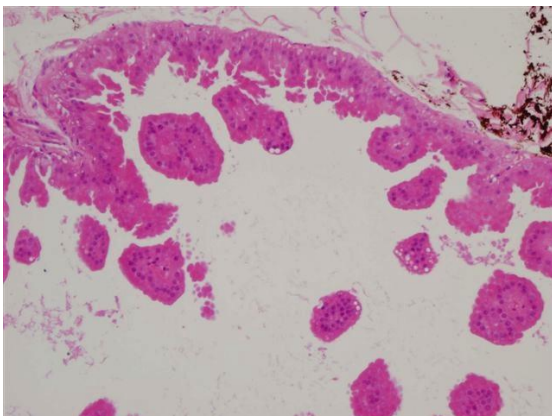


Figure 8c: Apocrine change in a benign complex papilloma

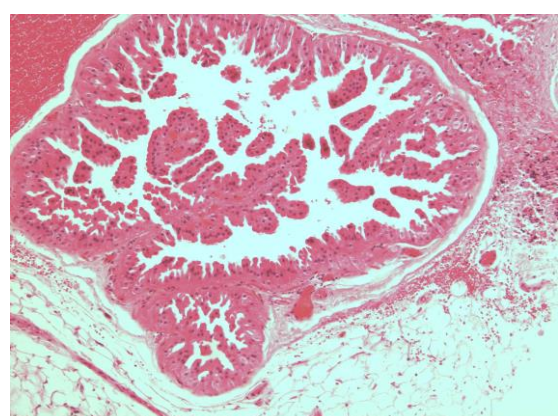


Figure 8d: Florid benign micropapillary hyperplasia

2.3 Columnar cell change without atypia (see Figures 17a, 17b, 17c and 17d)

Columnar cell change represents a spectrum, ranging from bland columnar cell change, through columnar cell hyperplasia to flat epithelial atypia and flat high-grade DCIS^{11,12}. These lesions are increasingly identified as a result of extensive investigations of radiological microcalcification¹³ (see also section 4.3). These lesions are described elsewhere (see section 4.3.3) and are dealt with in the previously published monograph in Appendix I.

2.4 Fibroadenoma

A benign lesion composed of connective tissue and epithelium exhibiting a pericanalicular and/or intracanalicular growth pattern (Figures 9a and 9b). The connective tissue is generally composed of spindle cells but may rarely also contain other mesenchymal elements such as fat, smooth muscle, osteoid or bone. Myxoid change may be marked. The epithelium is characteristically bi-layered but some changes commonly seen in lobular epithelium elsewhere in the breast (e.g. apocrine metaplasia, sclerosing adenosis, blunt duct adenosis, hyperplasia of usual type) may occur in fibroadenomas. These need not be recorded separately unless they amount to atypical hyperplasia or *in situ* carcinoma.

Sometimes individual lobules may exhibit increased stroma producing a fibroadenomatous appearance and occasionally such lobules may be loosely coalescent. These changes are often called fibroadenomatoid hyperplasia or change but may be recorded as fibroadenoma on the reporting form if they produce a macroscopically visible or palpable mass. Consequently, fibroadenomas need not be perfectly circumscribed.

Old lesions may show hyalinisation and calcification (and less frequently ossification) of stroma and atrophy of epithelium. Calcified fibroadenomas may present as areas of indeterminate calcification in the screening programme. Fibroadenomas are occasionally multiple.

For the purposes of the screening form, tubular adenomas can be included with fibroadenomas.

Malignant change occurs rarely in the epithelial component. This usually takes the form of carcinoma *in situ*, more frequently lobular than ductal.

Fibroadenomas should be distinguished from phyllodes tumours (Figures 10). Malignant phyllodes tumours are easily identified by their cellular highly atypical sarcoma-like stroma (or less, commonly truly sarcomatous elements, see liposarcoma in Figure 10a) (Figures 10a and 10b). Benign and borderline variants are more difficult to diagnose but the main feature is the more cellular stroma (see Table 1). Phyllodes tumours may also exhibit an enhanced intracanalicular growth pattern with club-like projections into cystic spaces and there is often overgrowth of stroma at the expense of the epithelium. Adequate sampling is important as the characteristic stromal features may be seen only in parts of the lesion. Although phyllodes tumours are generally larger than fibroadenomas, size is not an acceptable criterion for diagnosis; fibroadenomas may be very large and phyllodes tumours small. For purposes of convenience, benign and borderline phyllodes tumours should be specified under 'other benign lesions' and malignant phyllodes tumours (Figures 10a and 10b) under 'other malignant tumour' although it is recognised that histological appearance is often not a good predictor of behaviour.

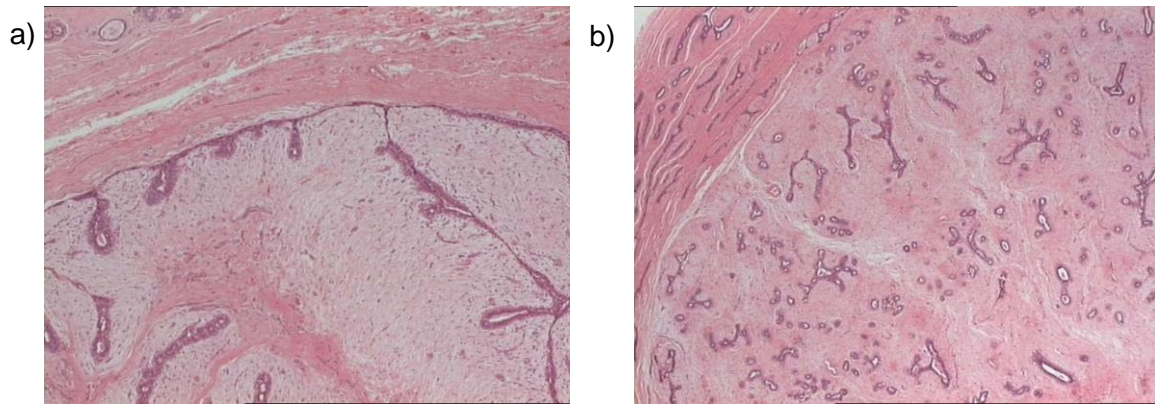


Figure 9: Examples of benign fibroadenomas of intracannalicular (a) and pericanalicular (b) types

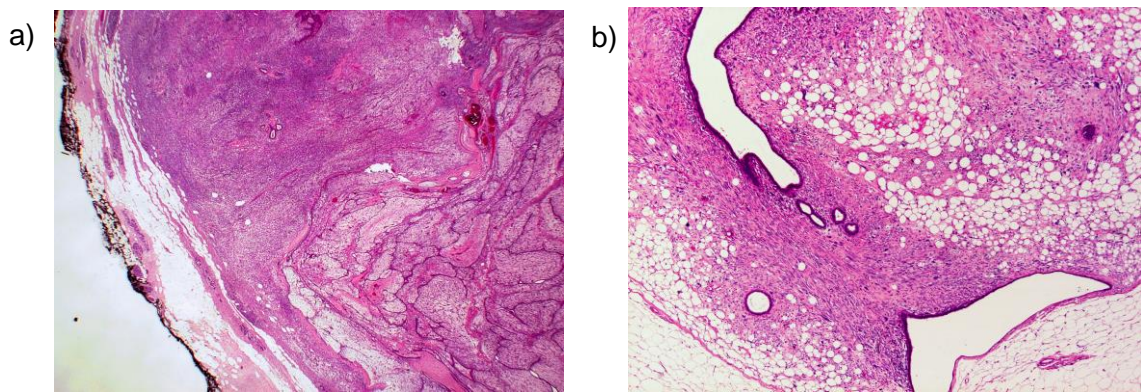


Figure 10: Examples of malignant phyllodes tumours with stromal liposarcoma like differentiation (a) and high-grade spindle cell stromal differentiation (b)

Table 1: Histological features of benign, borderline and malignant phyllodes tumours⁹⁴

Feature	Benign	Borderline	Malignant
Border	Well defined	May be focally infiltrative	Infiltrative
Stromal cellularity	Greater than in fibroadenoma but usually mild, may be non-uniform. Sub-epithelial accentuation may be seen	Cellular, usually moderate, may be non-uniform	Cellular, usually markedly so
Mitoses	<5 per 10 high power fields	5–9 per 10 high power fields	Usually 10 or more per 10 high power fields
Stromal cell atypia	None or mild	Mild or moderate	May be marked
Stromal overgrowth	Absent	Absent or focal	Often present
Malignant heterologous elements	Absent	Absent	Uncommon but if present diagnostic.

2.5 Papilloma

A papilloma is defined as a tumour with an arborescent, fibrovascular stroma covered by an inner myoepithelial and outer epithelial layer (Figure 11a). Epithelial hyperplasia without cytological atypia is often present and should not be recorded separately (Figure 11b). Atypical hyperplasia is rarely seen and, when present, should be recorded separately under 'Epithelial Proliferation' see also section 4.4. Use of the term atypical papilloma is discouraged. Epithelial nuclei are usually vesicular with delicate nuclear membranes and inconspicuous nucleoli. Apocrine metaplasia is frequently observed but should not be recorded separately on the reporting form (see Table 2). Squamous metaplasia is sometimes seen, particularly near areas of infarction. Sclerosis and haemorrhage are not uncommon and where the former involves the periphery of the lesion, it may give rise to epithelial entrapment with the false impression of invasion. The benign cytological features of such areas should enable the correct diagnosis to be made.

The term 'intracystic papilloma' is sometimes used by radiologists to describe a papilloma in a widely dilated duct. These lesions should simply be classified as papilloma on the form. These tumours should be differentiated from an encysted papillary carcinoma.¹⁴ For distinction from encysted papillary carcinoma, see Table 2, section 5.3 and Figures 27b to 27d).

Papillomas may be solitary or multiple. The former usually occurs centrally in sub-areolar ducts whereas the latter are more likely to be peripheral and involve terminal duct lobular units. The distinction is important as the multiple form is more frequently associated with atypical hyperplasia and ductal carcinoma *in situ*, the latter usually of low grade, which should be recorded separately (see section 4). This malignant change may be focal within the lesion and therefore extensive sampling may be required. Some sub-areolar papillomas causing nipple discharge may be very small and extensive sampling may be required to detect them.

Lesions termed ductal adenoma (sclerosed duct papilloma) exhibit a variable appearance, which overlap with other benign breast lesions. They may resemble papillomas except that they exhibit an adenomatous rather than a papillary growth pattern. These cases should be grouped under papilloma on the form. Indeed, some tumours may exhibit both papillary and adenomatous features. Some ductal adenomas may show pronounced central and/or peripheral fibrosis and overlap with complex sclerosing lesions (see 3.7) and some use the term complex sclerosing papillary lesion for these entities.

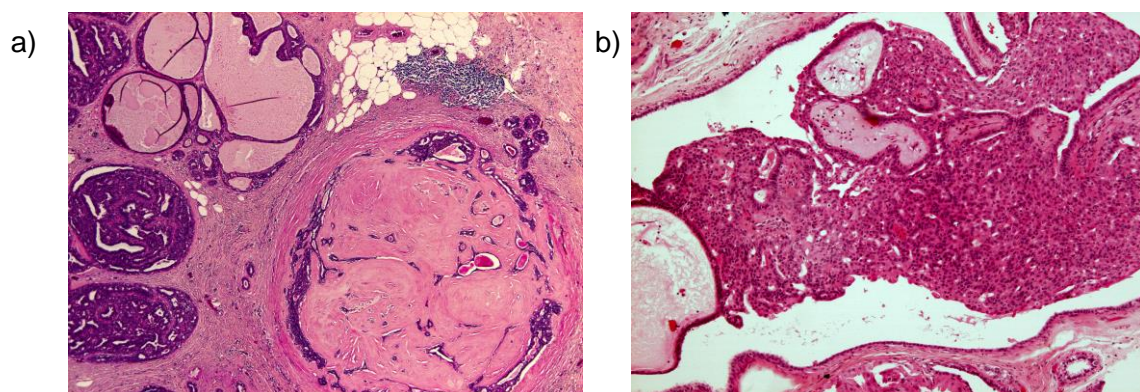


Figure 11: Examples of a benign sclerosed papillary lesion at low magnification (a) and with florid associated usual type epithelial hyperplasia (b)

Table 2: Distinction of papilloma from papillary carcinoma in situ and encysted papillary carcinoma (All the features of a lesion should be taken into account when making a diagnosis. No criterion is reliable alone.)

Features	Papilloma	Papillary carcinoma <i>in situ</i> and encysted papillary carcinoma
Fibrovascular cores	Usually broad and extend throughout lesion	Very variable, usually fine. May be lacking in at least part of the lesion
Cells covering papillae	Myoepithelial layer always present. Single layer of regular luminal epithelium OR features of regular usual type hyperplasia.	Myoepithelial cells usually absent, but when present may form a discontinuous layer. Cells often taller and more monotonous with oval nuclei, the long axes of which lie perpendicular to the stromal core of the papillae. Nuclei may be hyperchromatic. Epithelial multilayering frequent, often producing cribriform and micropapillary patterns overlying the papillae or lining the wall.
Mitoses	Infrequent, no abnormal forms	More frequent, abnormal forms may be seen
Apocrine metaplasia	Common	Rare
Surrounding tissue	Benign changes may be present, including usual epithelial hyperplasia	Surrounding ducts may bear DCIS
Necrosis and haemorrhage	May occur in either lesion, not helpful in discrimination	
Periductal and intra-lesional fibrosis	May occur in either lesion, not helpful in discrimination	

The condition of adenoma of the nipple (Figures 12a and 12b) should not be classified as papilloma in the screening form but specified under 'Benign Lesions, Other'. This should be distinguished from the rare syringomatous adenoma of the nipple composed of ducts and tubules with an apparent infiltrative pattern.

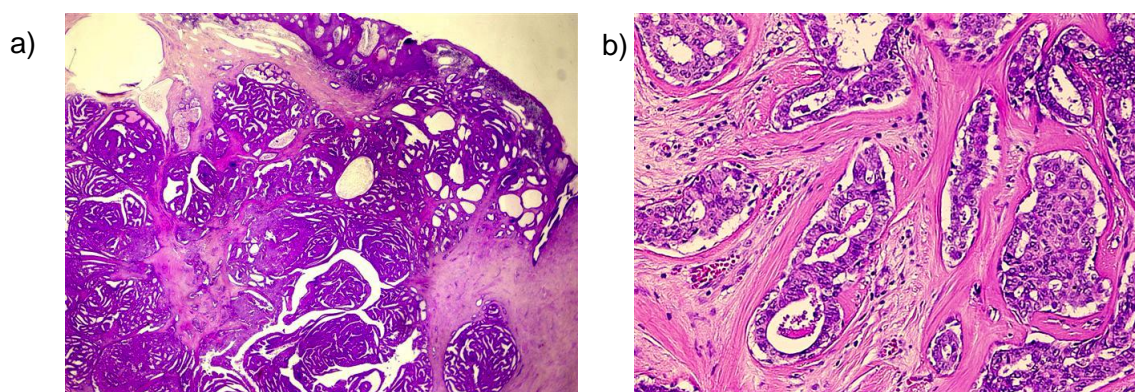


Figure 12: Example of a benign nipple adenoma at low (a) and high (b) magnification

2.6 Sclerosing adenosis

Sclerosing adenosis is an organoid lobular enlargement in which increased numbers of acinar structures exhibit elongation and distortion (Figures 13a, b and c). The normal two-cell lining is retained but there is myoepithelial and stromal hyperplasia. The acinar structures may infiltrate adjacent connective tissue and occasionally nerves and blood vessels, which can lead to an erroneous diagnosis of malignancy. Early lesions of sclerosing adenosis are more cellular and later ones more sclerotic. Calcification may be present.

There may be coalescence of adjacent lobules of sclerosing adenosis to form a mass detectable by mammography or macroscopic examination. The term 'nodular sclerosing adenosis' or 'adenosis tumour' has been used to describe such lesions. It is recommended that sclerosing adenosis is not entered on the screening form if it is a minor change detectable only on histological examination. Although sclerosing adenosis often accompanies fibrocystic change (see below), this is not always the case and the two changes should be recorded separately.

Occasionally apocrine metaplasia is seen in areas of sclerosing adenosis ('apocrine adenosis'), with or without cytological atypia (Figure 13d). It can produce a worrying appearance and should not be mistaken for malignancy. This has a lobular architecture at low power and there are usually adjacent benign changes with sclerosing adenosis and apocrine metaplasia. Rarely, the epithelium in sclerosing adenosis may show atypical hyperplasia or *in situ* carcinoma. In such cases, these changes should be recorded separately on the reporting form.

The differential diagnosis of sclerosing adenosis includes tubular carcinoma (Figures 32a to 32e), microglandular adenosis (Figures 13e to 13g) and radial scar (Figure 14).¹⁵ In tubular carcinoma, the infiltrating tubules exhibit cytological atypia and lack a myoepithelial layer and a lobular organoid growth pattern; ductal carcinoma *in situ* (DCIS) is a frequent accompaniment. Microglandular adenosis (Figures 13e to 13g) differs from sclerosing adenosis in lacking the lobular organoid growth pattern and being composed of rounded tubules lined by a single layer of cells lacking cytological atypia. The glandular distortion of sclerosing adenosis is lacking. Radial scar is distinguished from sclerosing adenosis by its characteristic floret-type growth pattern with ducto-lobular structures radiating out from a central zone of dense fibro-elastotic tissue. Immunohistochemistry for myoepithelial markers (e.g. p63, smooth muscle myosin heavy chain, see Appendix G) will show the presence of a myoepithelial marker in the above benign conditions (sclerosing adenosis, radial scar/complex sclerosing lesion) with the exception of microglandular adenosis (see Figure 13f) and an absence of a myoepithelial layer in tubular carcinomas.

2.7 Sclerosing lesions (complex sclerosing lesion/radial scar)

The term complex sclerosing lesion/radial scar includes those sclerosing lesions with a pseudoinfiltrative growth pattern. A radial scar is defined as being 10 mm or less in diameter and consists of a central fibro-elastic zone from which radiate out tubular structures that are two-layered and may exhibit intra-luminal proliferation. Tubules entrapped within the central zone of fibro-elastosis exhibit a more random, non-organoid arrangement (Figure 14). Lesions greater than 10 mm are generally termed complex sclerosing lesions. They have all the features of radial scars and, in addition to their greater size, exhibit more disturbance of structure, often with nodular masses around the periphery. Changes such as papilloma formation, apocrine metaplasia and sclerosing adenosis may be superimposed on the main lesion. Some complex sclerosing lesions give the impression of being formed by coalescence of several adjacent sclerosing lesions. There is a degree of morphological overlap with some forms of ductal adenoma.

If the intra-luminal proliferation exhibits atypia or amounts to *in situ* carcinoma, it should be recorded separately under the appropriate heading on the screening form.

The main differential diagnosis is carcinoma of tubular or low-grade 'ductal' type. The major distinguishing features are the presence of myoepithelium and basement membrane around the tubules of the sclerosing lesions. Immunocytochemical studies for myoepithelial cells (e.g. p63, smooth muscle myosin – heavy chain) are useful, see Appendix G. Cytological atypia is also lacking and any intra-tubular proliferation resembles hyperplasia of usual type unless atypical hyperplasia and/or *in situ* carcinoma are superimposed (see above). Tubular carcinomas generally lack the characteristic architecture of sclerosing lesions.

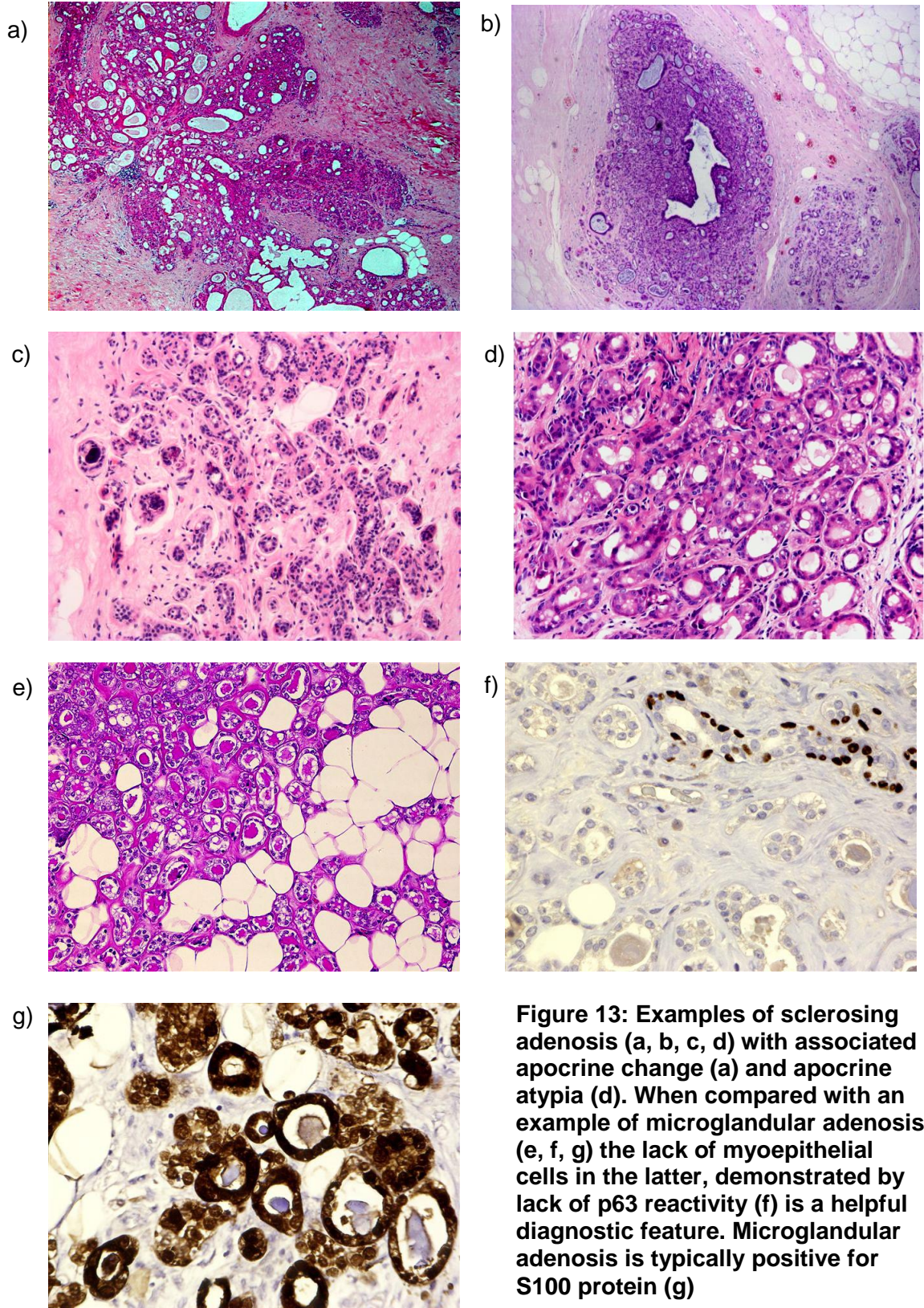


Figure 13: Examples of sclerosing adenosis (a, b, c, d) with associated apocrine change (a) and apocrine atypia (d). When compared with an example of microglandular adenosis (e, f, g) the lack of myoepithelial cells in the latter, demonstrated by lack of p63 reactivity (f) is a helpful diagnostic feature. Microglandular adenosis is typically positive for S100 protein (g)

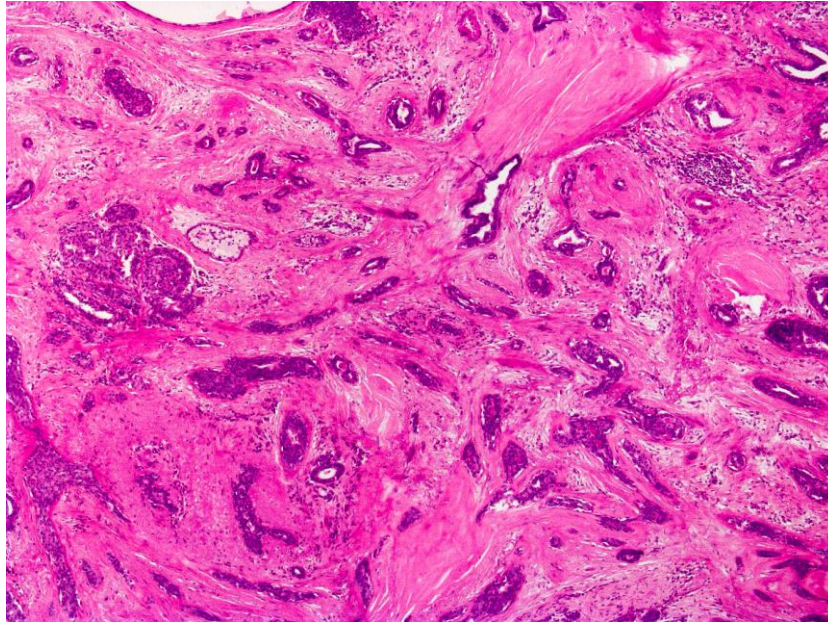


Figure 14: An example of a radial scar

2.8 Periductal mastitis/duct ectasia (plasma cell mastitis)

This process involves larger and intermediate size ducts, generally in a sub-areolar location. The ducts are lined by normal or attenuated epithelium, filled with amorphous, eosinophilic material and/or foam cells and exhibit marked periductal chronic inflammation, often with large numbers of plasma cells (periductal mastitis). There may be pronounced periductal fibrosis. The inflammatory infiltrate may contain large numbers of histiocytes giving a granulomatous appearance. Calcification may be present. The process may ultimately lead to obliteration of ducts leaving dense fibrous masses. Persistence of small tubules of epithelium around the periphery of an obliterated duct results in a characteristic garland pattern. Duct ectasia is often associated with nipple discharge or retraction.

Cysts are distinguished from duct ectasia by their rounded rather than elongated shape, tendency to cluster, lack of stromal elastin, frequent presence of apocrine metaplasia and less frequent presence of eosinophilic material or foam cells in the lumina.

2.9 Mastitis and mammary duct fistula (recurring sub-areolar abscess)

Other inflammatory breast conditions such as mastitis, mammary duct fistula, lymphocytic lobulitis, specific infections and granulomatous mastitis should be coded under 'Benign, Other'.

2.10 Reaction to breast implants

Most implants have an associated fibrous capsule, often with scattered chronic inflammatory cells. There may be a pseudosynovial reaction on the surface. Silicone that has leaked from the implant is seen as clear spaces, typically of variable size, with associated macrophages, foreign body giant cells and lymphocytes. A similar reaction to silicone may be seen in the regional lymph nodes.

2.11 Other (specify)

This category is intended for use with less common conditions which form acceptable entities but cannot be entered into the categories above, e.g. fat necrosis, lipoma, adenoma of nipple, benign and borderline phyllodes tumours. The index at the end of the booklet should help as

a reference for lesions difficult to place in any of the above categories. The national computer breast screening database will not accept an entry under this heading unless a specific diagnosis is given. Specific rare inflammatory and infectious conditions fall in this category and include, for example, parasitic infections – dirofilariasis, hydatid cyst, cysticercosis and sparganosis; fungal infections – chronic mycoses, e.g. cryptococcal and coccidiomycotic granulomas; leishmaniasis in lymph node; tuberculosis; myospherulosis (following previous surgery).

2.12 Benign lesions in male breast including gynaecomastia (Figures 15a and 15b)

The principal benign condition for which male breast tissue is excised is gynaecomastia. This may be of two types:¹ the florid type, where ducts are abundant and may be lined by extremely hyperplastic epithelium and² the fibrous type, where ducts are relatively normal but are surrounded by plentiful periductal fibrous tissue. In both types, the cellularity of the fibrous tissue may vary. In the florid type, it is important to be aware that the hyperplasia can be marked, and can produce papillary projections, which may mimic micropapillary DCIS (fig 15b), although the projections in gynaecomastia do not have the bulbous tips are found in micropapillary DCIS. As in the female breast, in diagnostically difficult cases the algorithm of assessment of CK5, CK14 and ER may be helpful, see Appendix G. While rarely ADH and DCIS can occur in male breast, it is important to have a high threshold for such diagnoses, due to the range of florid hyperplastic features that can be seen in gynaecomastia.

Lobules are not usually seen in male breast, they can very occasionally be found in gynaecomastia. Fibroadenomas, which are considered to be derived from lobules, can occasionally present in the male breast. Other conditions such as pseudoangiomatous stromal hyperplasia (PASH) and myofibroblastomas also occur in the male breast.

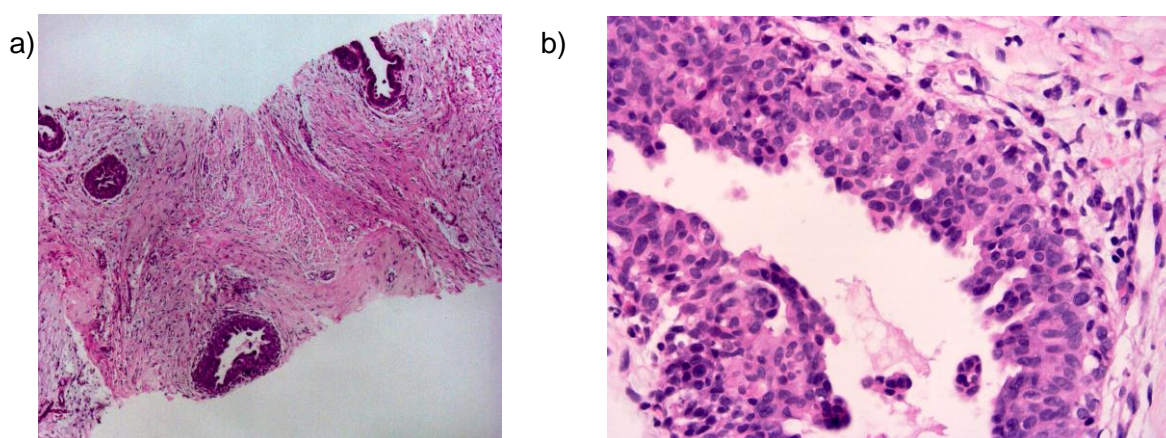


Figure 15: An example of benign gynaecomastia at low magnification (a) and at high magnification (b) to illustrate benign epithelial hyperplasia

3 Classifying epithelial proliferations

This section should be used to record the presence of intraluminal epithelial proliferation in terminal duct lobular units or interlobular ducts.

3.1 Epithelial proliferation – not present

This should be ticked if there is no epithelial multilayering (apart from that ascribed to cross-cutting).

3.2 Epithelial proliferation – present without atypia

This term should be used to describe all cases of intraluminal proliferation, most commonly usual type epithelial hyperplasia, showing no or only minimal atypia (not amounting to atypical ductal hyperplasia or flat epithelial atypia). The proliferation may vary from mild (up to four cell layers thick) to florid usual epithelial hyperplasia. The changes may involve terminal duct lobular units or interlobular ducts.

3.2.1 Usual epithelial hyperplasia (Figures 16a, 16b and 16c, Table 3, and Table 3 accompanying figure)

The major features of usual epithelial hyperplasia are:

- A mixed cell population comprising (luminal) epithelial cells, basal/myoepithelial cells
- Immunoreactivity for luminal epithelial cytokeratins (CK8, 18, 19) and basal intermediate epithelial cytokeratins (CK5, 5/6, 14) may be helpful in confirming the mixed cell population in usual epithelial hyperplasia (see Appendix G and Figure 16c).
- Oestrogen receptor positivity may also be of value; usual epithelial hyperplasia most frequently shows a range of intensity of expression from negative to strong positive cells whilst low-grade clonal epithelial proliferations (ADH, low-grade DCIS and lobular *in situ* neoplasia) are uniformly strongly ER positive (see Appendix G).
- Cells of basal intermediate type are absent in columnar cell lesions (which are typically ER positive) and apocrine proliferations (ER negative).
- Irregular, slit-like and peripheral lumina (Table 3 and Table 3 accompanying figure)
- Streaming epithelial bridges
- Infrequent mitoses, with no abnormal forms.

The distinctions from atypical ductal hyperplasia and low-grade DCIS are summarised in Table 3.

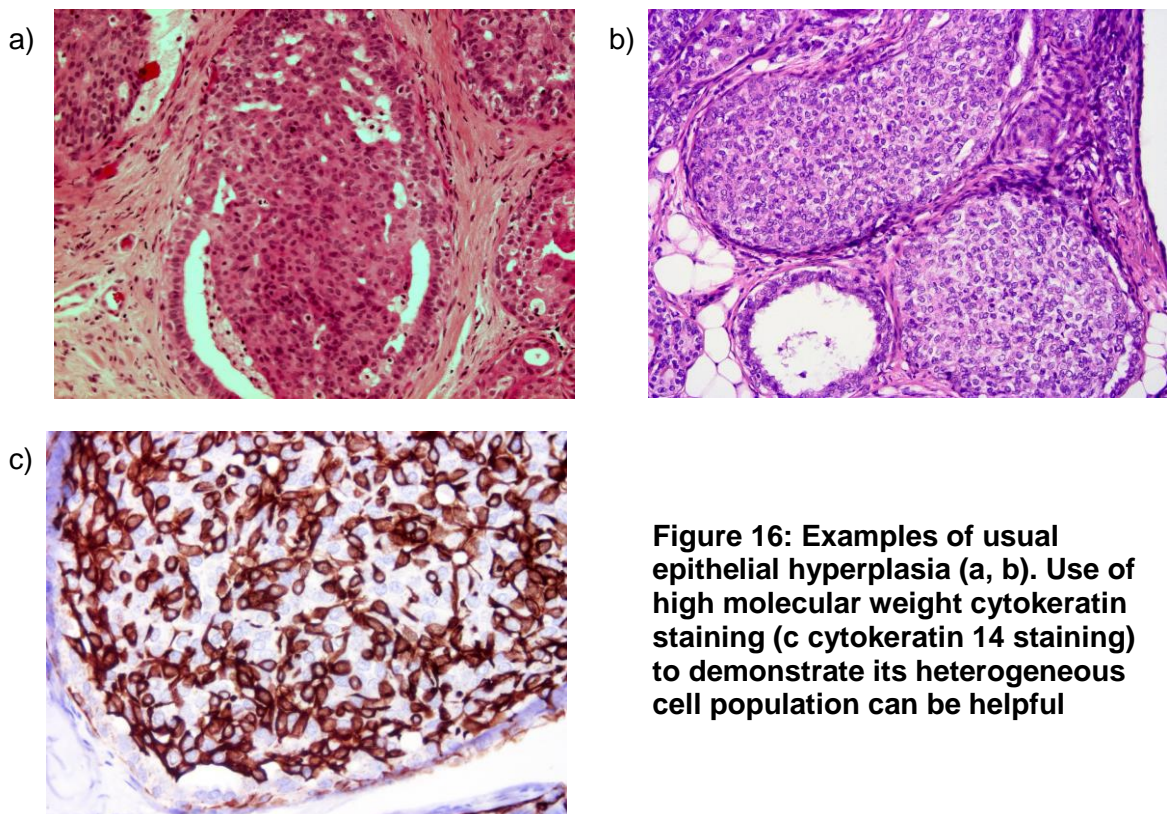


Figure 16: Examples of usual epithelial hyperplasia (a, b). Use of high molecular weight cytokeratin staining (c cytokeratin 14 staining) to demonstrate its heterogeneous cell population can be helpful

Table 3: Comparison of histological features of ductal hyperplasia and ductal carcinoma *in situ* (DCIS)

Histological features	Usual type hyperplasia	Atypical ductal hyperplasia	Low nuclear grade DCIS
Size	Variable size but rarely extensive unless associated with other benign processes such as papilloma or radial scar	Usually small (< 2–3 mm)	Rarely less than 2–3 mm and may be very extensive
Cellular composition	Mixed epithelial cell and spindle shaped cells* present. Lymphocytes and macrophages may also be present. Myoepithelial hyperplasia may rarely occur around the periphery	A uniform cell population, which may merge with areas of usual type hyperplasia within the same duct space.	Single uniform cell population.
Architecture	Variable	Micropapillary, cribriform or solid pattern.	Well developed micropapillary, cribriform or solid patterns
Lumina	Irregular, often ill defined peripheral slit like spaces are common and a useful distinguishing feature	May be distinct, well formed rounded spaces in cribriform type. Irregular, ill defined lumina may also be present	Well delineated, regular punched out lumina in cribriform type. Micropapillae are of classical appearance, with thinner necks and more bulbous tips.
Cell orientation	Often a streaming pattern with the long axes of nuclei arranged in parallel to direction of cellular bridges, which often have a 'tapering' appearance	Cell nuclei may be at right angles to bridges in cribriform type, forming 'rigid' structures	Micropapillary structures with indiscernible fibrovascular cores or smooth, well delineated geometric spaces. Cell bridges 'rigid' in cribriform type with nuclei orientated towards the luminal space
Nuclear spacing	Uneven	Even	Even
Epithelial/tumour cell character	Small and ovoid, but showing variation in shape	Small uniform or medium sized monotonous population present at least focally	Small uniform monotonous population
Nucleoli	Indistinct	Single small	Single small
Mitoses	Infrequent; no abnormal forms	Infrequent; abnormal forms rare	Infrequent; abnormal forms rare
Necrosis	Rare	Rare	If present, confined to small particulate debris/secretion in cribriform and/or luminal spaces
Immunohistochemistry ER High MW cyto-keratins (e.g. CK5, 5/6,14,17)	Heterogeneous/mosaic Heterogeneous/mosaic	Homogeneous usually strong Negative	Homogeneous usually strong Negative

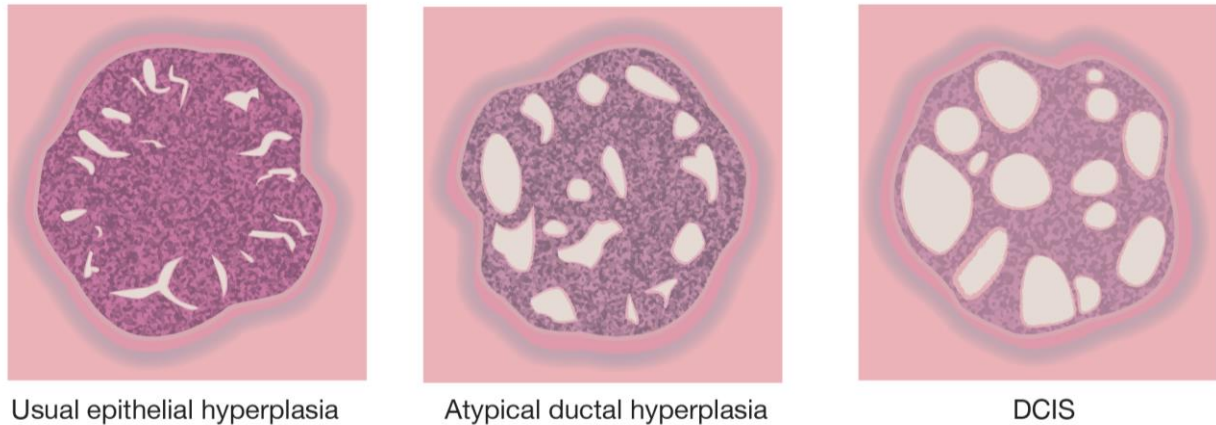


Table 3 Accompanying figure

3.3 Columnar cell lesions

Columnar cell lesions (synonyms: blunt duct adenosis, columnar cell change, columnar cell hyperplasia, unfolded lobule, columnar alterations with prominent snouts and secretions (CAPSS)), in broad terms include the spectrum of changes ranging from bland columnar cell change (see section 3.3) through columnar cell hyperplasia to flat epithelial atypia.¹¹ They have become increasingly identified clinically as a consequence of more rigorous investigation of radiological calcification.

3.3.1 Categorisation and recording of columnar cell lesions

- Columnar cell change.
- Columnar cell hyperplasia.
- Flat epithelial atypia.
- Flat high-grade *in situ* carcinoma.

These should be recorded on the breast screening form according to their broad category:

- benign columnar alterations without atypia, or with minor degrees of atypia, as columnar cell change
- columnar cell change with architectural atypia as atypical ductal hyperplasia (epithelial proliferation with atypia – ductal) or low-grade DCIS, according to extent (see sections 4.4 and 5.1.4)
- flat epithelial atypia should be categorised as epithelial proliferation with atypia – ductal
- lesions with marked atypia as flat high-grade DCIS (see section 5.1.2).

3.3.2 Columnar cell change and columnar cell hyperplasia (see also section 3.3 and Figures 17a, b, c and d)

Classical columnar cell change is comprised of lobular acini lined by epithelial cells that are tall and snouted in a manner similar to that observed in tubular carcinoma (Figure 17a and 17b). Commonly this is associated with luminal secretions and/or microcalcifications. If there is a piling up of several layers the term '*columnar cell hyperplasia*' is used (Figure 17c), assuming that the stratification is real, as opposed to artefactual as a consequence of cross-cutting. There is morphological diversity within these groups, for example the hyperchromasia of the nuclei can vary, as well as nuclear shape and the 'tallness' of the cells; thus in some cases some lesions are more cuboidal than columnar (Figure 17d). Table 4 shows features of assistance in categorisation of the columnar cell lesions and distinguishing these from

atypical ductal hyperplasia. In columnar cell change, lobules are often dilated and are lined by epithelial cells with a columnar morphology. Other features include increased cytoplasm and apical snouts. The associated luminal secretions often undergo calcification. A single layer of columnar epithelial cells is the norm, although minor multilayering and tufting may be present. If a greater degree of multilayering of the epithelial cells is seen, the process is classified as columnar cell hyperplasia. At present, this is considered to be equivalent to usual epithelial hyperplasia.

As noted above, columnar cell change and hyperplasia should be classified as a variant of fibrocystic change, and should be recorded on the NHS BSP breast pathology data form as columnar cell change.

True micropapillary structures and rigid epithelial bridges are not seen in columnar cell change or columnar cell hyperplasia. If such architectural atypia, usually in the form of bulbous micropapillary structures, is identified, the lesion should be assessed for degree within the membrane-bound spaces and overall extent, and classified as atypical ductal hyperplasia or low-grade DCIS accordingly. See sections 4.4 and 5.1.4. As well as ADH/low-grade DCIS, other epithelial proliferations may merge, or be associated, with columnar cell hyperplasia, including atypical lobular hyperplasia, lobular carcinoma *in situ* (LCIS) and invasive carcinoma, often of low-grade tubular or tubulo-lobular type.

The presence of such associations should be recorded as fibrocystic change plus the additional type or types of lesion.

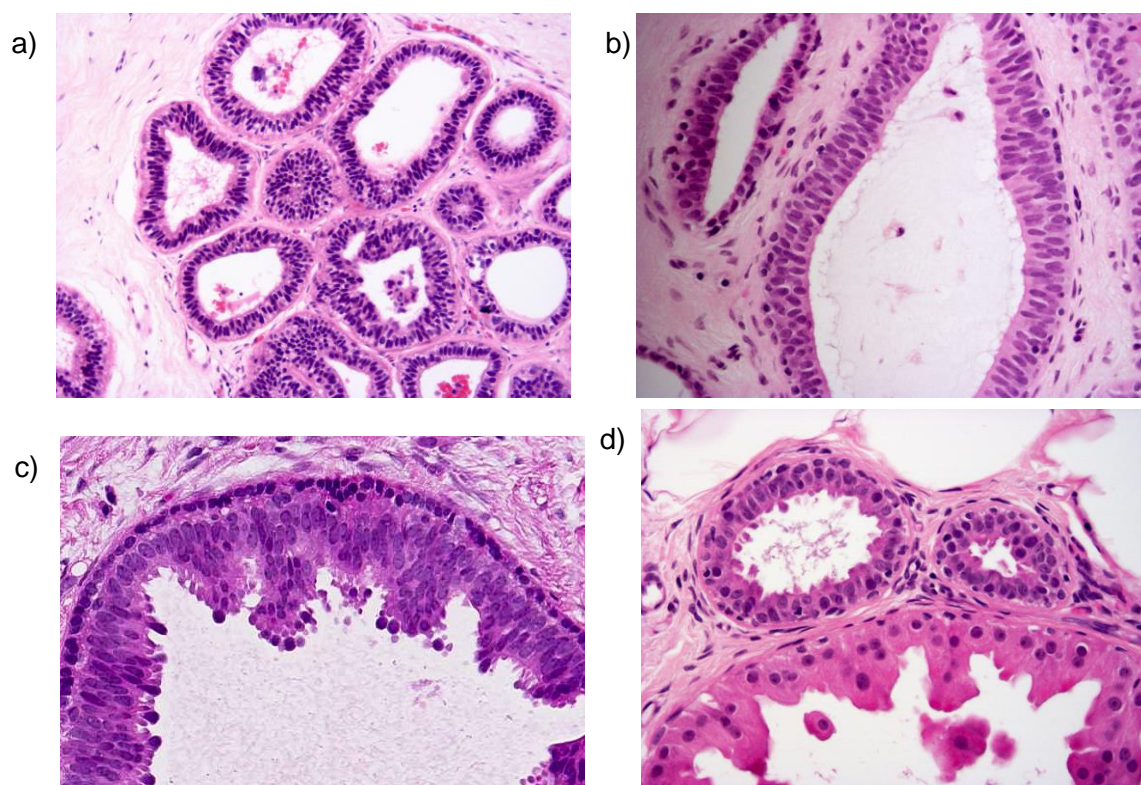


Figure 17: Examples of columnar cell change (a, b, c, d)

3.3.3 Flat epithelial atypia (Figures 18a, 18b and 18c)

If superimposed mild cytological atypia is seen within the columnar cell change in the terminal duct-lobular unit (Figure 18a), the lesion is classified as flat epithelial atypia. In this lesion the cells are morphologically similar to those of atypical ductal hyperplasia/low-grade DCIS but are present, typically in a single layer lining round, mildly dilated acini (Figure 18b). The nuclei are typically round or oval and evenly spaced (Figures 18b and 18c). The cells may have clumped chromatin or vesicular nuclei or prominent multiple nucleoli. Mitoses are

infrequent. If there is marked cytological atypia is seen the lesion is regarded as flat high-grade *in situ* carcinoma. See section 5.1.2.

It should be noted that the columnar cell epithelial cell proliferation may show homogeneous oestrogen receptor positivity and similarly does not show the heterogeneity of cytokeratin expression of classic usual epithelial hyperplasia, as described in Appendix G.

At present the entity of flat epithelial atypia diagnosed in excision specimens is accepted as a lesion not associated with a significant risk of future development of cancer and therefore does not merit inclusion in the category of 'epithelial proliferation – present with atypia (ductal)'.

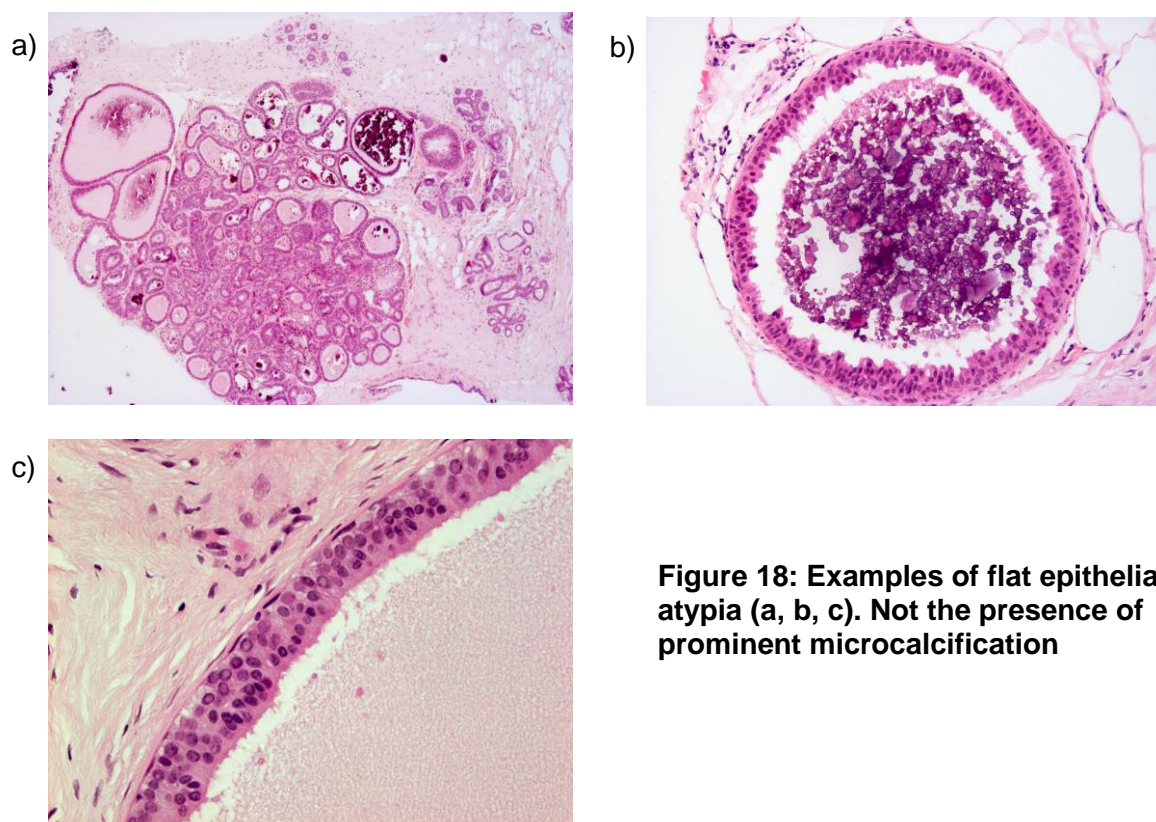


Figure 18: Examples of flat epithelial atypia (a, b, c). Not the presence of prominent microcalcification

3.4 Epithelial proliferation – present with atypia (ductal)

See also section 3.3.3 above. At present, the entity of flat epithelial atypia diagnosed in excision specimens is accepted as a lesion not associated with a significant risk of future development of cancer and therefore does not merit inclusion in the category of 'epithelial proliferation – present with atypia (ductal)'.

3.4.1 Atypical ductal hyperplasia (Figures 19a to 19d, Table 3 and Table 3 accompanying figure)

Atypical ductal hyperplasia (ADH) is a rare lesion. Its current definition rests on identification of some but not all features of DCIS. Difficulties are encountered mainly in distinguishing ADH from the low-grade variants of DCIS. The diagnosis of ADH is based on both a *qualitative* and *quantitative* assessment of the lesion.¹⁶

The *qualitative* assessment is based on cytological features and architectural growth pattern. These include:

- a uniform monomorphic luminal epithelial cell population (ER, CK8, 18, 19 positive, CK5, 5/6, 14 negative; see Appendix G and Figures 19a, 19b, 19c and 19d)

- even spacing of the nuclei
- secondary lumina, some of which are rigid whereas others are tapering (Table 3 and Table 3 accompanying figure)
- hyperchromatic nuclei
- cribriform, micropapillary or solid growth pattern.

The *quantitative* assessment is based on assessment of lesion size:

- areas of ADH are usually microfocal/small, not exceeding 2–3 mm in size/involve less than two complete membrane-bound spaces.

Proliferations with high-grade cytology qualify as DCIS, regardless of the size or quantity of epithelial proliferation.

The diagnosis of ADH is made in those cases in which a diagnosis of **low-grade** DCIS is seriously considered but where the architectural, cytological and quantitative features do not amount to a confident diagnosis of DCIS. If a diagnosis of ADH is contemplated, extensive sampling and/or levels should be undertaken to search for more evidence to establish an unequivocal diagnosis of DCIS.

Table 3 provides details of features to help distinguish ADH from usual type hyperplasia and DCIS and Table 4 shows features to help distinguishing ADH from columnar cell lesions.

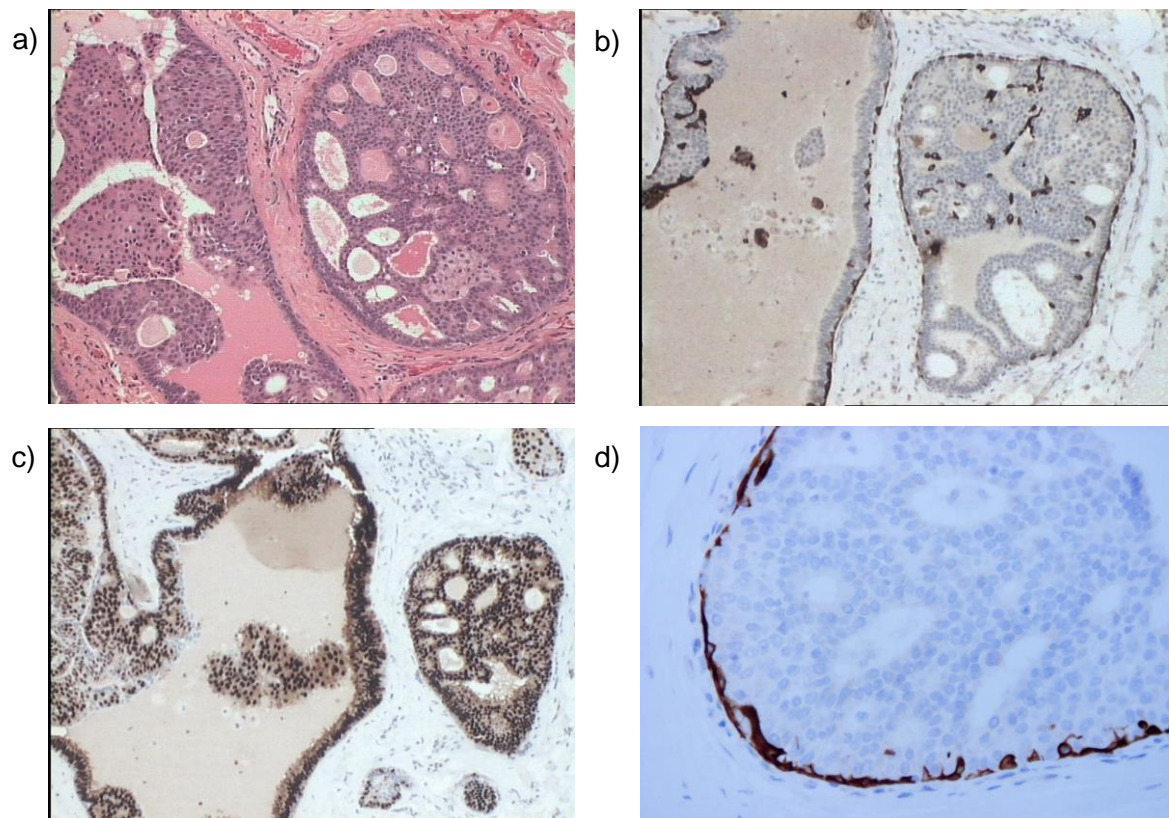


Figure 19: An example of atypical ductal hyperplasia. Note incomplete duct involvement apart from one duct space (a). Low-grade DCIS and ADH are typically composed of a uniform luminal epithelial cell population which lacks high molecular weight cytokeratin expression (b, cytokeratin 5/6; d, cytokeratin 14) and exhibits strong uniform oestrogen receptor staining (c)

Table 4: Features of help in distinguishing the columnar cell lesions and atypical ductal hyperplasia (TDLUs: terminal duct lobular units)

Columnar cell change	Columnar cell hyperplasia	Flat epithelial atypia	Atypical ductal hyperplasia
TDLUs with variably, usually mildly, dilated acini. Irregular internal contour	TDLUs with variably dilated, usually irregularly shaped, acinar contour	TDLUs dilated. Usually bluer than normal at low power. Typically smooth internal contour to acini	TDLUs may be dilated. Usually bluer than normal at low power due to increased cell numbers
Acini lined by one to two cell layers	Acini lined by more than 2 layers of cells; may form tufts, but no complex architectural patterns	Acini lined by one or more layers of cells with a flat growth pattern (no complex architectural patterns)	Acini lined by one or more layers of cells. Complex architectural pattern
Lining cells bland, columnar in shape, with uniform ovoid to elongated nuclei oriented perpendicular to basement membrane	Lining cells bland, columnar in shape, similar to those in columnar cell change, with uniform ovoid to elongated nuclei oriented perpendicular to basement membrane. Nuclei may appear crowded and overlap	Acini lined by cells with low-grade (monomorphic) cytological atypia; cells most often resemble those seen in low-grade DCIS. Nuclei typically round, but may be ovoid in some cases	Low-grade (monomorphic) cytological atypia. Nuclei typically round, evenly-spaced
Normal nuclear to cytoplasmic ratio	Normal nuclear to cytoplasmic ratio	Increased nuclear to cytoplasmic ratio	Increased nuclear to cytoplasmic ratio
Nucleoli absent or inconspicuous	Nucleoli absent or inconspicuous	Nucleoli may or may not be prominent	
Cells polarised	Cells polarised	Cells typically lack polarity, not regularly oriented perpendicular to basement membrane; however, in some cases, stratified, atypical, ovoid nuclei are arranged perpendicular to basement membrane (resembling pattern seen in colonic adenomas)	Cells polarised around architecturally atypical features, such as micropapillae
Luminal secretions may be present but are usually not prominent. Calcifications may be present	Luminal secretions may be present and prominent; calcifications often present may be psammomatous	Luminal secretions may be present and prominent; calcifications often present may be psammomatous	Luminal secretions may be present but are usually not prominent. Calcifications may be present
Mitoses infrequent	Mitoses infrequent	Mitoses infrequent	

3.4.2 Useful rules of thumb to distinguish ADH from DCIS

- Restrict diagnosis of ADH to those cases in which DCIS is seriously considered but where the features are not sufficiently developed to make a confident diagnosis.
- DCIS usually extends to involve multiple duct spaces. If a lesion with features of ADH extends widely, the diagnosis of ADH should be questioned.

3.5 Epithelial proliferation – present with atypia (lobular)

3.5.1 Atypical lobular hyperplasia and classical lobular carcinoma *in situ* (*in situ* lobular neoplasia) (Figure 7, 20a-20e and 21a)

Atypical lobular hyperplasia (ALH) (Figures 7 and 20a) and lobular carcinoma *in situ* (LCIS) (Figures 20d, 20e and 21a) have traditionally been separated as distinct entities based on cytological and quantitative features relating to the extent of lobular involvement.¹⁷ The justification for separating the entities is the differing risks of subsequent invasive cancer shown in long-term follow-up series, but molecular analysis suggests that biologically the two appear to be essentially similar and that these are neoplastic processes. In view of the subjective nature of separating ALH from LCIS and the similar molecular profiles, some experts have suggested that the two forms should be grouped together as 'lobular neoplasia' (*in situ* lobular neoplasia). However, for the purposes of recording risk of subsequent invasive carcinoma and for Cancer Registry recording, when the degree and extent can be assessed, for example in excision specimens, it is recommended that these are reported as separate entities. However, very mild forms of ALH (Figure 20a) can be found in association with fibrocystic change, involution and otherwise normal breast tissue. No attributable risk has been shown for these mild forms and such lesions are often disregarded.

In cytological terms, the two forms of the lesion are identical; *in situ* lobular neoplasia is characterised by proliferation within terminal duct lobular units of characteristic cells. The defining cell type is discohesive, round, cuboidal or polygonal with clear or light cytoplasm. Nuclei are small to moderate in size, round to oval and cytologically bland, with an occasional small inconspicuous nucleolus. The nucleus may be indented by an intracytoplasmic vacuole containing mucin (Figure 20b, shown in pagetoid spread, and 20d). The cells have a high nuclear to cytoplasmic ratio. Mitotic figures and hyperchromatism are not often seen. There is an even distribution of cells and cellular monotony is the rule. Cytoplasmic clear vacuoles are often, although not invariably, present, sometimes having a central mucin blob. Pagetoid spread of cells may be present when the proliferation of neoplastic cells above the basement membrane undermines the normal lining epithelial cells (Figure 20b).

The distension of lobular units may be variable from mild to gross, resulting in either patent lumina or complete obliteration. In atypical lobular hyperplasia there is minimal extension of less than half of the acini (Figure 7, 20a), whilst in lobular carcinoma *in situ* more than half of the acini within the TDLU are distended by an expansion of the typical cells (8 or more cells across each acinus) (Figure 20d).

Particularly in some more extensive lesions, distinction between *in situ* lobular neoplasia and DCIS may be difficult. For example, on occasions, a regular, evenly spaced monotonous population is seen within both ducts and lobules. E-cadherin membrane reactivity (Figure 20c) may be useful in such cases in distinguishing *in situ* lobular neoplasia from DCIS as the latter typically shows strong membrane positivity, whilst in the former expression is absent or weak (see Appendix G). However, this marker can also be non-contributory or show varied levels within a case. Thus if both ducts and lobules contain epithelial proliferation of this type, particularly if E-cadherin is heterogeneous, categorisation as both LCIS and DCIS is recommended to imply the precursor risk of DCIS and the bilateral cancer risk of *in situ* lobular neoplasia. Such cases should also be recorded as DCIS and LCIS on the reporting form.

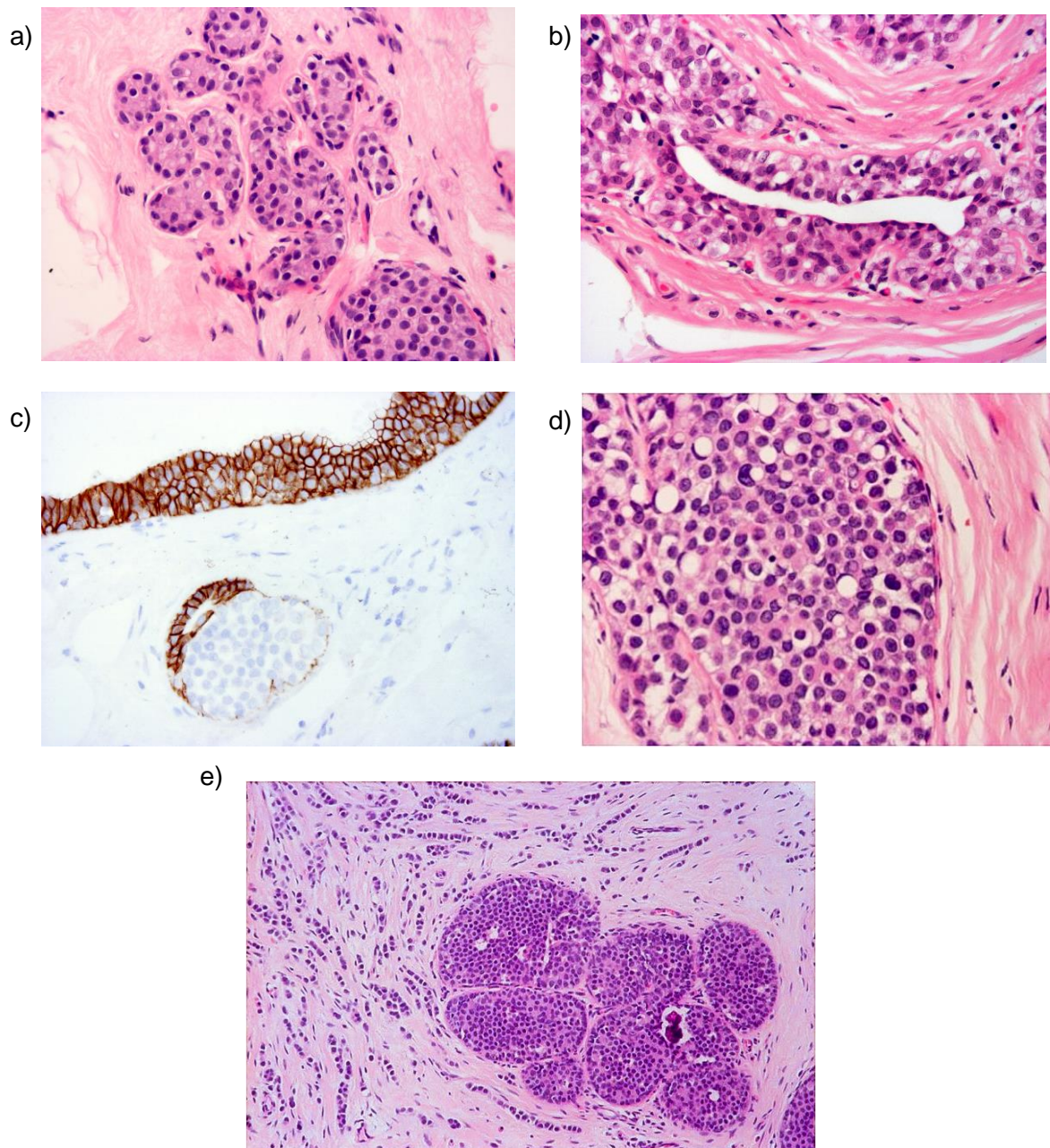


Figure 20: Examples of atypical lobular hyperplasia and LCIS, showing mild ALH (a), ALH with pagetoid duct involvement (b), lack of E Cadherin expression (c), LCIS (d) and LCIS with associated invasive lobular carcinoma (e)

Table 5 illustrates the differences between DCIS and *in situ* lobular neoplasia.

3.5.2 Pleomorphic variant of lobular carcinoma *in situ* (figures 21a and 21b)

Variants, particularly the pleomorphic subtype of lobular carcinoma *in situ*, are recognised. The discohesion and architecture of the classical form is present but the cells are larger and pleomorphic (cytonuclear grade 3, see Figure 21a) with more abundant cytoplasm. Central necrosis and calcification are often seen (Figure 21b). Mitoses may be seen, although uncommon in the classical form, and atypical forms may be noted. Pleomorphic LCIS is less frequently ER positive than classical forms and more often expresses HER2 oncoprotein. There is a paucity of information available on the clinical behaviour of pleomorphic LCIS, but

it is widely regarded as a more aggressive form of the disease, which should be managed akin to DCIS rather than classical LCIS, based on its biological and molecular profile.

Table 5: Distinction of ductal carcinoma *in situ* (DCIS) from lobular *in situ* neoplasia (ALH/LCIS)

Histological features	DCIS	Classical type <i>in situ</i> lobular neoplasia
Cells	Variable, depending on nuclear grade	Small, rounded with granular or hyperchromatic nuclei, inconspicuous nucleoli and high nuclear–cytoplasmic ratio
Intracytoplasmic lumina	Rare	Common
Growth pattern	Very variable, e.g. solid, comedo, papillary, cribriform	Diffuse monotonous with complete luminal obliteration
Cell cohesion	Usually good	Usually poor
Degree of distension of involved structures	Moderate to great	Slight to moderate
Pagetoid spread into interlobular ducts	Rare	Often present
E Cadherin	Positive	Usually negative or abnormal (see Appendix G)

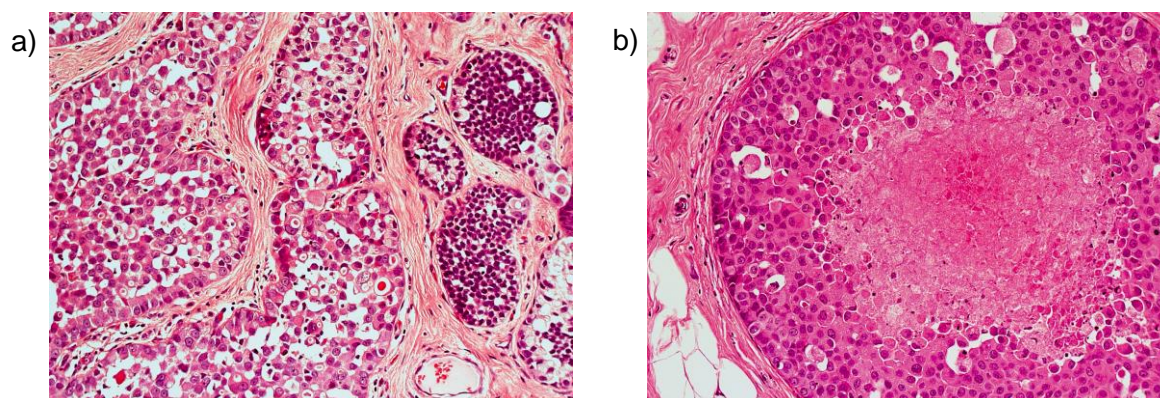


Figure 21: Examples of pleomorphic LCIS; comparison with classical LCIS (right) (a) and to show similarity of appearance to high-grade DCIS with associated central comedo-type necrosis (b)

3.5.3 Extensive and mass forming classical LCIS with necrosis

This variant of LCIS has classical cytology with central necrosis in distended acini. The degree of atypia is not sufficient for a diagnosis of pleomorphic LCIS. This variant is uncommon and the clinical behaviour is not well established.¹⁸

In many centres both of the above entities are regarded as established forms of *in situ* carcinoma requiring therapeutic excision, equivalent to ductal carcinoma *in situ* (DCIS).

4 Classifying malignant non-invasive lesions

4.1 Ductal carcinoma *in situ*

Ductal carcinoma *in situ* (DCIS) is, in the vast majority of cases, a unicentric (involving a single duct system)^{19,20} proliferation of epithelial cells with cytological features of malignancy within parenchymal structures of the breast. It is distinguished from invasive carcinoma by the absence of stromal invasion across the basement membrane, which can be confirmed by immunostaining for myoepithelial makers. Despite the name, most DCIS is generally considered to arise from the terminal duct lobular units. The main points of distinction from lobular neoplasia are described in Table 5. Features in favour of DCIS are the greater cellular cohesion and readily visible cell membranes, slightly larger cell size, cribriform or micropapillary architecture, cytoplasmic basophilia, variation in cellular arrangement and size, and lack of intracytoplasmic lumina.

DCIS varies in cell appearance, growth pattern and extent of disease and is now considered to represent a heterogeneous group of *in situ* neoplastic processes. Classification has historically been according to growth pattern, but this has been carried out with little enthusiasm owing to the variability seen within an individual case, perceived lack of reproducibility and lack of clinical relevance. The cytonuclear features are less frequently variable within a lesion²¹ and show an association with clinical outcome; lesions of high nuclear grade are recognised to be clinically more aggressive. Distinguishing between subtypes of DCIS is also of value for correlating pathological and radiological appearances, improving diagnostic consistency, assessing the likelihood of associated invasion as well as determining the probability of local recurrence. Various systems have been described, based on combinations of cell morphology, architecture (including polarisation of cells) and the presence of comedo-type necrosis. Necrosis can be identified by the presence of cell ghosts and is eosinophilic and granular in nature. Karyorrhectic debris is seen. The definition of necrosis does not include single apoptotic individual cells.

A high power lens (40x) should be used to compare the size of tumour cell nuclei with normal epithelial nuclear size and/or red blood cell size,²² as for the atypia/pleomorphism score of invasive carcinoma.

Other features such as mitotic count, presence of prominent nucleoli and polarisation of nuclei may be helpful in assigning grade. In particular, a high mitotic count is very rare in DCIS not of high histological grade.

4.1.1 High nuclear grade DCIS (Figures 22a, 22b and 22c)

Cells have pleomorphic, irregularly spaced and, usually, large nuclei exhibiting marked variation in size with irregular nuclear contours, coarse chromatin and prominent nucleoli. Nuclei are typically large and greater than three times the size of erythrocytes. Mitoses are usually frequent and abnormal forms may be seen. If mitoses are prominent, there is a high likelihood that a case is of high grade. High-grade DCIS may exhibit several growth patterns. It is often solid with comedo-type central necrosis, which frequently contains deposits of amorphous calcification. Sometimes, a solid proliferation of malignant cells fills the duct without necrosis, but this is relatively uncommon and may be confined to nipple/lactiferous ducts in cases presenting with Paget's disease of the nipple. High nuclear grade DCIS may also exhibit micropapillary and cribriform patterns frequently associated with central comedo type necrosis. 'Comedo DCIS' is thus not considered to represent an architecture or 'type' of DCIS as comedo necrosis may be seen in DCIS of differing architectures and even in non-high-grade disease. Unlike low nuclear grade DCIS, there is rarely any polarisation of cells covering the micropapillae or lining the intercellular spaces in high-grade lesions.

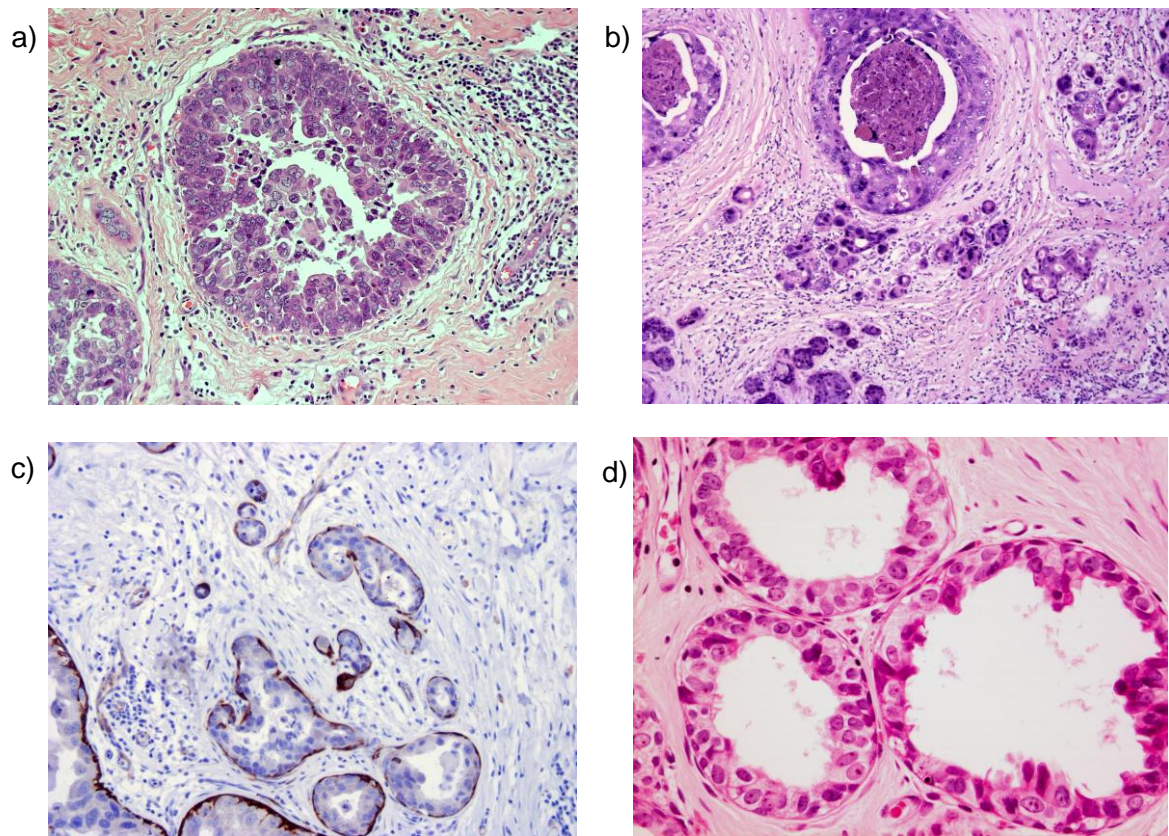


Figure 22: Examples of high-grade DCIS (a, b) with cancerisation of lobules (b) and of flat type (d). Use of myoepithelial stains can be useful (c) to demonstrate the preservation of myoepithelial cells and help confirm the diagnosis should there be concern about coexisting invasion

4.1.2 Flat high-grade DCIS (Figure 22d)

This lesion is becoming increasingly recognised as an entity, although uncommon in frequency. It is related to the spectrum of columnar cell alterations and, as such, presents particular problems of recognition and definition. This range of columnar cell alterations (see sections 3.3 and 4.3) extends from common forms of columnar cell change through columnar cell hyperplasia and flat epithelial atypia (i.e. a low cytonuclear grade lesion) through to a cytologically high-grade process classified as flat high-grade DCIS (Figure 22d). These lesions are usually HER2 positive.

4.1.3 Intermediate nuclear grade DCIS (Figure 23)

These types cannot be assigned readily to the high or low nuclear grade categories. The nuclei show moderate pleomorphism, less than that seen in the high-grade disease, but lack the monotony of the small cell type (Figure 23a). The nuclei are typically larger than those seen in low-grade DCIS and are between two and three times the size of an erythrocyte. The nuclear to cytoplasmic ratio is often high, and one or two nucleoli may be identified. The growth pattern may be solid, cribriform or micropapillary (Figure 23b), and the cells usually exhibit some degree of polarisation covering papillary processes or lining intercellular lumina. Clear cell or apocrine types often fall into this category.

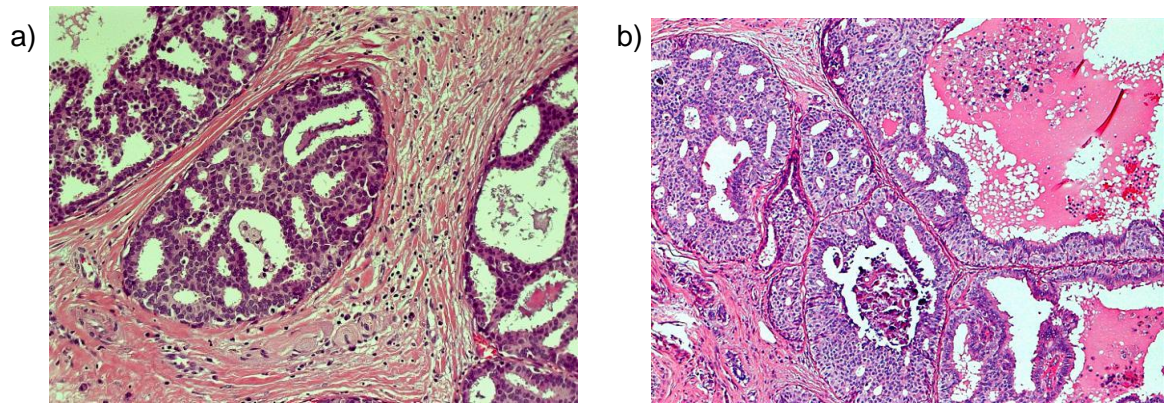


Figure 23: Examples of intermediate grade DCIS

4.1.4 Low nuclear grade DCIS (Figures 24a and b, Table 3 and Table 3 accompanying figure)

Low-grade DCIS is composed of monomorphic, evenly spaced cells with rounded, centrally placed nuclei and inconspicuous nucleoli (Figure 24a). The nuclei are usually, but not invariably, small and are typically one to two times the size of an erythrocyte. Mitoses are few and there is rarely individual cell necrosis. These cells are generally arranged in micropapillary and cribriform patterns (Figure 24b). Both architectures are frequently present within the same lesion, although the cribriform pattern is more common and tends to predominate (Table 3 and Table 3 accompanying figure). There is usually polarisation of cells covering the micropapillae or lining the intercellular lumina. Less frequently, low-grade DCIS has a solid pattern. Low-grade DCIS is distinguished from atypical ductal hyperplasia largely based on extent of the lesion (see section 4.4).

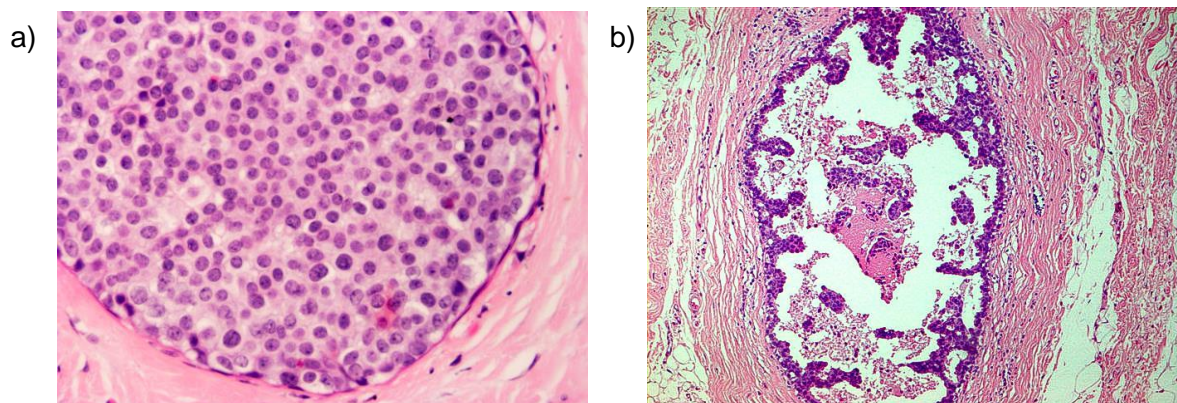


Figure 24: Examples of low-grade DCIS of solid (a) and micropapillary (b) types

4.1.5 Mixed types of DCIS

A small proportion of cases of DCIS exhibit features of differing nuclear grades. If present, the case should be classified by the highest nuclear grade present.

4.2 Rarer subtypes of DCIS

Other rare, but morphologically distinct, subtypes of DCIS are recognised. There is, however, no firm evidence to support the distinction of these uncommon special DCIS types from commoner DCIS forms with regard to clinical presentation and/or behaviour, with the exception of encysted papillary carcinoma.

4.2.1 Apocrine DCIS (Figures 25a, b and c)

The tumour cells show abundant granular cytoplasm, often moderate to severe cytological atypia (Figure 25a) and central necrosis.²³ Apical snouting (cytoplasmic protrusions) are not always seen. In some cases, no necrosis may be evident. However, the suggested diagnosis of apocrine DCIS should be made with caution, particularly in the absence of marked pleomorphism, conspicuous mitoses and comedo type necrosis (i.e. if not high grade) (Figure 25b).^{23, 24} It may be extremely difficult to distinguish atypical apocrine hyperplasia from low-grade apocrine DCIS. The degree of cytonuclear atypia, the extent of the lesion and altered architectural growth pattern are helpful features used to make this decision. Mitoses are a useful feature as these are very infrequent or absent in atypical apocrine proliferations. Convincing membrane HER2 positivity may also be helpful (Figure 25c).

Benign apocrine change is, of course, frequent in breast biopsy material and is recognised to show nuclear variability, which should not be interpreted as DCIS. Atypical apocrine change, for example within sclerosing adenosis, may also mimic apocrine DCIS or even invasive apocrine carcinoma. Identification of mitoses, periductal inflammation and fibrosis may be helpful as they are rarely seen in atypical apocrine hyperplasia or apocrine proliferations other than DCIS.

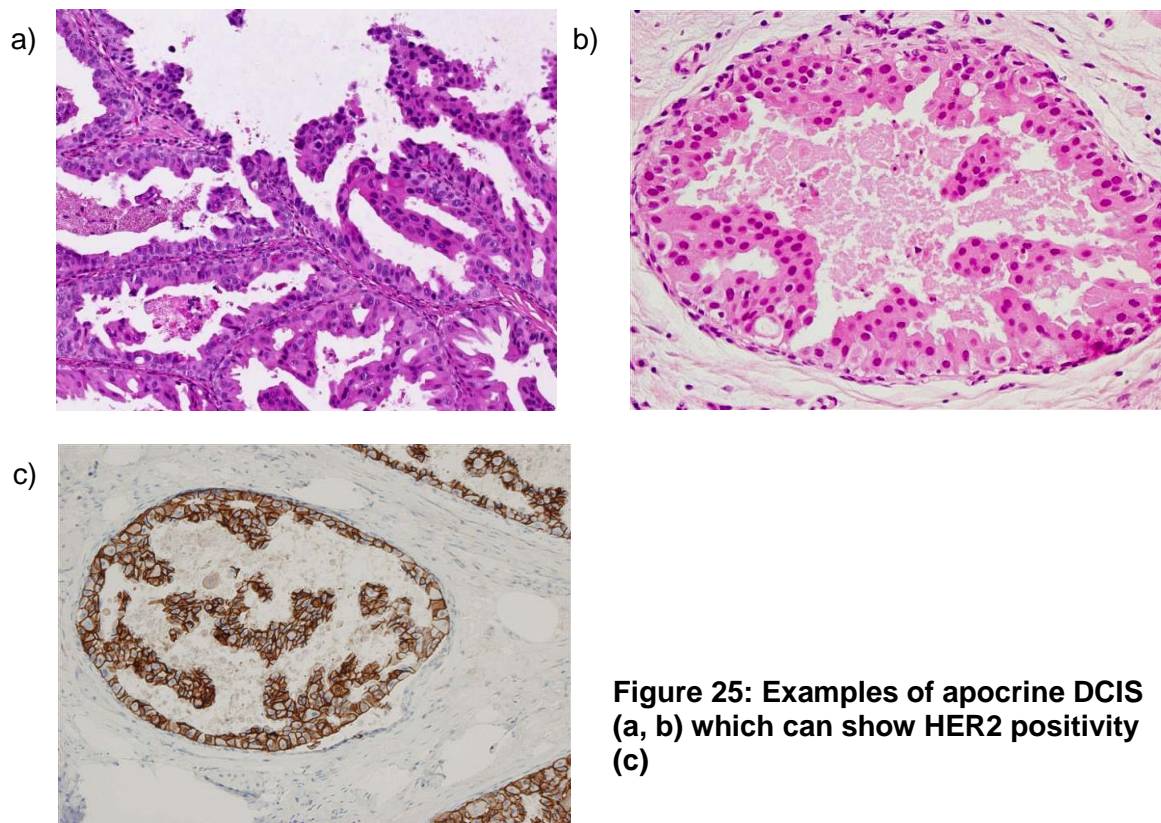


Figure 25: Examples of apocrine DCIS (a, b) which can show HER2 positivity (c)

4.2.2 Clear cell DCIS

This is an intraductal proliferation of neoplastic cells with optically clear cytoplasm and distinct cell margins forming cribriform and solid structures. Central necrosis may be present. This may be mimicked by poor fixation in other forms of DCIS and care should be taken to achieve optimum fixation of all breast samples, as noted above.

4.2.3 Signet ring DCIS

This is a very rare variant characterised by the proliferation of signet ring cells in solid or papillary growth patterns.²⁵ The cytoplasm stains positive with diastase resistant periodic acid–Schiff (PAS) or Alcian blue.

4.2.4 Neuroendocrine DCIS (Figure 26)

The lesion has an organoid appearance with prominent argyrophilia, resembling a carcinoid tumour. The neoplastic cells may be arranged in a solid pattern or may form tubules, pseudorosettes, palisades or ribbons. Where solid, the proliferation is nearly always punctuated by fine fibrovascular cores giving a solid papillary pattern, which distend and dilates duct spaces. This pattern often co-exists with adjacent more typical non-papillary DCIS. An eosinophilic cytoplasmic granularity or organoid spindle morphology are all supportive of the neuroendocrine phenotype. The latter may mimic the streaming seen in usual epithelial hyperplasia.²⁶ Immunohistochemical stains for neuroendocrine markers (chromogranin, PGP9.5, synaptophysin) may be helpful in diagnosis of this subtype of DCIS,²⁷ which also typically strongly and uniformly expresses oestrogen receptor. Because of the lack of microcalcification, these tumours tend to present symptomatically, most commonly in elderly patients with blood stained nipple discharge.

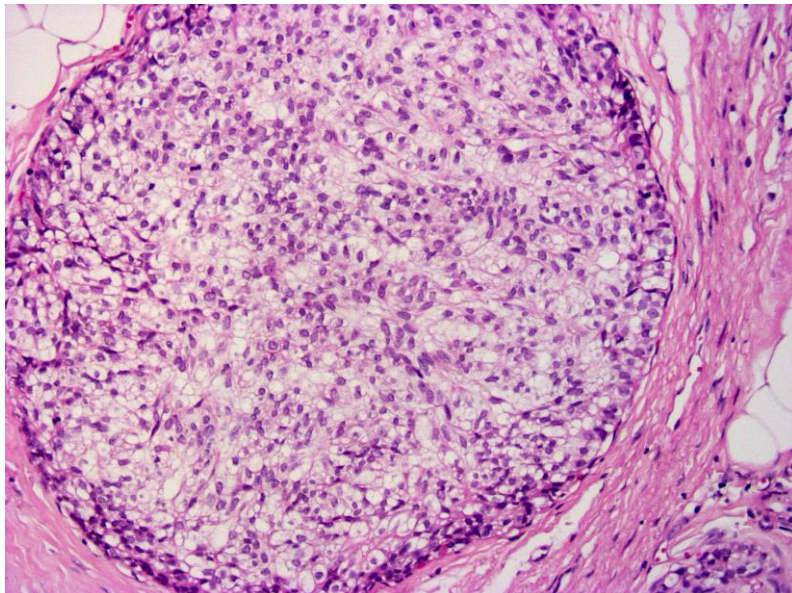


Figure 26: An example of neuroendocrine DCIS with clear cell features

4.2.5 Cystic hypersecretory DCIS and mucocoele-like DCIS

These uncommon types of DCIS are variants of micropapillary DCIS. The cells produce mucinous secretions, which distend involved duct spaces, thereby giving a cystic appearance.²⁸ Microcalcifications are often a very prominent feature.

4.3 DCIS within a papilloma, papillary carcinoma *in situ* and encysted/encapsulated papillary carcinoma

4.3.1 DCIS in papilloma

Benign papillomas often bear an associated epithelial proliferation. In such cases the underlying architecture and assessment of the immunohistochemical profile confirms that the fibrovascular fronds are typically wide. There is a myoepithelial layer between the epithelium

and the stroma, unlike papillary carcinoma *in situ* (see below). Assessment of the epithelial proliferation should be undertaken as for intraductal epithelial proliferation, as above. Most commonly the appearances will be those of usual epithelial hyperplasia, often with apocrine change also present. However, if the epithelial proliferation is of low-grade, clonal appearance, the extent of the atypical epithelial proliferation should be ascertained and the lesion categorised as atypia within a papilloma if less than 3 mm, or as DCIS within a papilloma if more than 3 mm in extent.²⁹ Such lesions can be distinguished separately from papillary carcinoma *in situ* and categorised as either ADH or DCIS within in papilloma, as appropriate. The term atypical papilloma is not recommended.

4.3.2 Papillary carcinoma *in situ* (Figure 27a)

Papillary carcinoma *in situ* represents a distinct lesion with a papillary structure with, typically thin, fibrovascular cores; however, these may be absent in at least part of the lesion. There is an absence of the myoepithelial population between the fibro-vascular core and the overlying epithelial portion of the tumour. This absence can be confirmed with immunohistochemistry for smooth muscle myosin heavy chain and p63 (see Appendix G). The neoplastic epithelium is often of columnar morphology and aligned perpendicular to the fibrovascular core. It may be single layered although often crowding and multilayering may be present. These lesions are mostly commonly of intermediate cytonuclear grade.

4.3.3 Encysted/encapsulated papillary carcinoma (Figure 27b, 27c, 27d)

Encysted/encapsulated papillary carcinoma should be recorded when a lesion with the central appearance of papillary carcinoma *in situ* is, in addition, surrounded by a hyalinised fibrous wall, giving an encysted (intracystic/encapsulated) appearance. Adjacent to the fibrous capsule, haemosiderin (or haematoidin) pigment and a lymphocytic population are often seen (Figure 27b). There is, at present, a debate regarding the correct classification of encysted papillary carcinoma. Although the absence of a myoepithelial component within the central portion of the papillary lesion itself is one of the diagnostic criteria, it has been now recognised that a proportion of encysted papillary carcinomas also lack a myoepithelial cell population around the mass itself (Figure 27c) as well as within the fibrovascular cores (Figure 27d).^{30,14} This can be used to distinguish unequivocal papillary carcinoma *in situ*, which can be shown to lie within a duct structure with a surrounding myoepithelial population, from the encysted variant. The absence of myoepithelial cells on the inner aspect of the fibroblastic wall of, at least some of, the encysted forms has led some experts to suggest that these are in fact an indolent form of invasive breast carcinoma, albeit with a behaviour akin to DCIS. Thus encysted/encapsulated papillary carcinoma is a rare but distinctive lesion, which is more common in older women. It carries an excellent prognosis³¹, although the presence of associated DCIS in the surrounding tissue is recognised to be of significance regarding local recurrence and should be recorded.³²

Distinction between encysted/encapsulated papillary and solid papillary carcinoma (Figure 27e) is recommended, as the frequency of co-existing conventional invasive carcinoma is higher in the latter. Lesions of both types are currently classified as *in situ* carcinoma for management and coding purposes, unless conventional invasion is present.

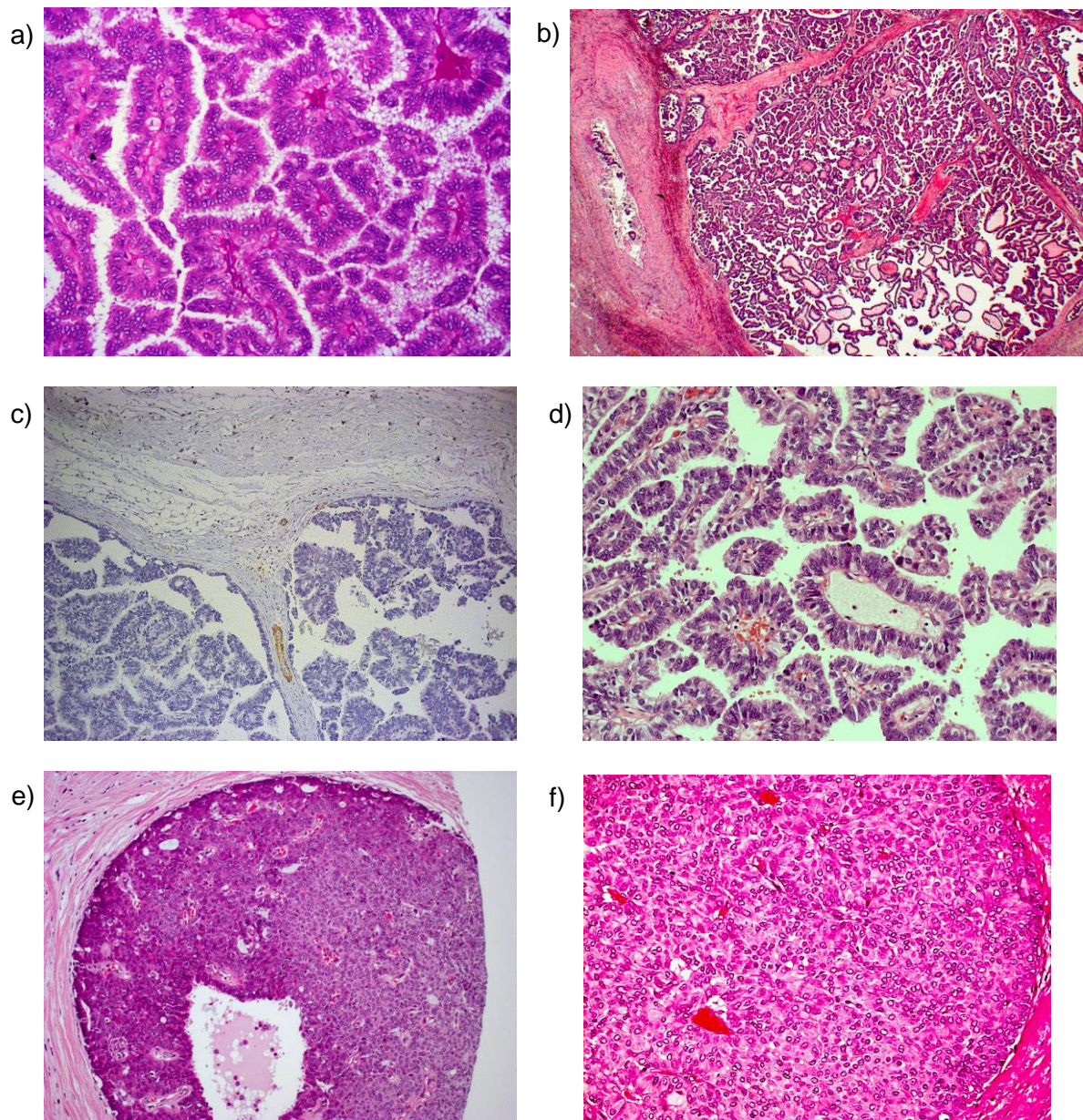


Figure 27: Examples of papillary carcinoma, of encysted/encapsulated (a, b, d) and solid (e, f) types. Note the lack of myoepithelial cells throughout (c, smooth muscle myosin staining). Some forms of solid papillary DCIS may demonstrate neuroendocrine differentiation with granular cytoplasm (f)

4.4 Paget's disease of the nipple (Figures 28a and 28b)

In this condition, there are adenocarcinoma cells within the epidermis of the nipple (Figure 28a). The carcinoma cells are typically high grade and cam 5.2 and HER2 positive (see Appendix G for immunohistochemical guidance and Figure 28b). Epidermal invasion by tumour infiltrating the skin is excluded. Paget's disease of the nipple should be reported regardless of whether or not the underlying *in situ* or invasive carcinoma is identified. The underlying carcinoma should be recorded separately. Distinction from intraepidermal squamous cell carcinoma and melanoma can be made on the basis of morphological and immunocytochemical features (see Appendix G).

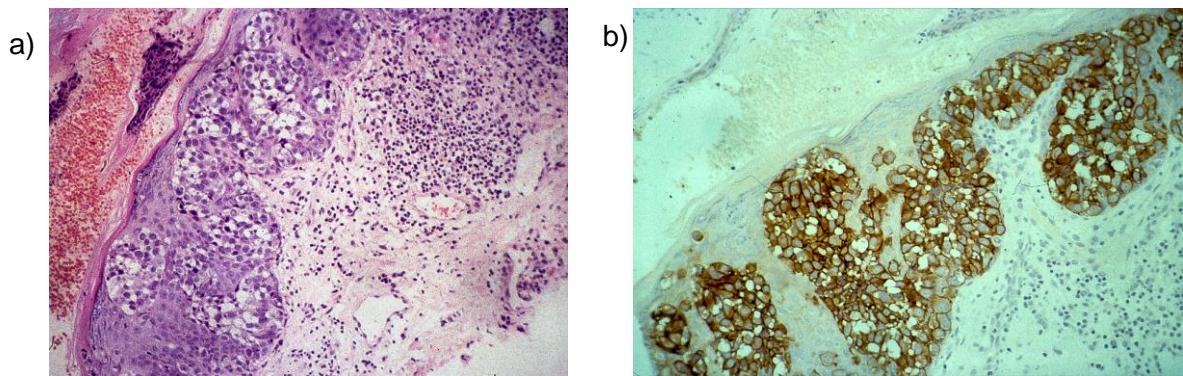


Figure 28: An example of Paget's disease of the nipple (a) which typically is associated with underlying high-grade DCIS and shows HER2 positivity (b)

4.5 Microinvasive carcinoma (Figures 29a, 29b and 29c)

This is typically a dominant, and often extensive, DCIS lesion with one or more clearly separate foci of invasion into the stromal tissue, none of which measures more than 1 mm in diameter. Fulfilling these criteria is a very uncommon finding, particularly if further levels are examined. If there is doubt about the presence of invasion the case should be classified as pure DCIS only. Microinvasion is very rare in DCIS types other than high nuclear grade, and is rare even in the setting of high-grade disease. Microinvasive lobular carcinoma can occur but is exceptionally rare. Cases of pure high cytonuclear grade DCIS, especially if large, should be thoroughly and extensively sampled to exclude microinvasion or larger (> 1 mm) foci of established invasion. However, care should be taken to avoid overdiagnosis of cancerisation of lobules as microinvasive carcinoma (see Figure 22b). The organoid appearance of cancerisation of lobules should be sought and deeper H&E sections from the paraffin block are often more helpful than immunohistochemical examination. However, stains that label myoepithelial cells (e.g. smooth muscle myosin heavy chain and p63) (Figure 29c) or the basement membrane (laminin and collagen IV) may assist in the diagnosis (Appendix G).

4.6 Epithelial displacement in breast tissue following needle/core biopsy

Seeding of needle tract by benign, hyperplastic and/or malignant epithelial cells may be seen along FNA, core biopsy or VACB tracts and cause diagnostic problems in subsequent surgical excision specimens. Lesions most commonly associated with such phenomenon are papillary lesions, including ductal papilloma and encysted papillary carcinoma.³³ However, other lesions such as radial scar³⁴ and even male gynaecomastia following liposuction³⁵ have been reported to show similar changes. Immunohistochemistry for myoepithelial cells is no value since these groups will lack a myoepithelial layer. Differentiation from true invasive carcinoma depends on careful consideration of history of previous biopsy, assessment of cellular changes and most importantly the presence of such seedlings along needle tract as judged by presence of haemorrhage, fibroblastic proliferation, fat necrosis and macrophages in the area affected. Diagnostic difficulty may arise when the displaced epithelial cells are noted within lymphovascular spaces. These may occur in the initial core biopsy for ductal carcinoma *in situ* where the presence of malignant cells within lymphovascular spaces may not represent true lymphovascular invasion.³⁶ Pre-Sentinel lymph node breast massage has been implicated as a mode of benign mechanical transport of epithelial cells to sentinel lymph nodes.³⁷

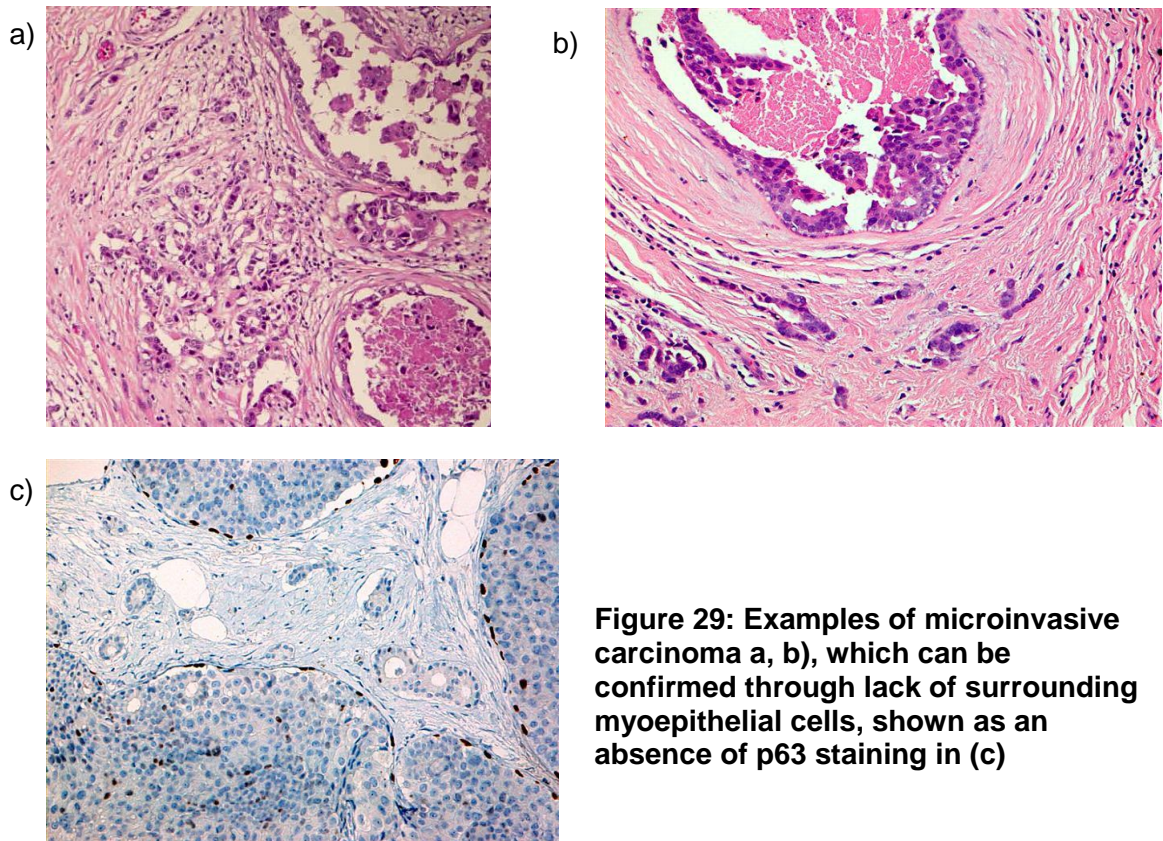


Figure 29: Examples of microinvasive carcinoma a, b), which can be confirmed through lack of surrounding myoepithelial cells, shown as an absence of p63 staining in (c)

5 Classifying invasive carcinoma

Typing invasive carcinomas has prognostic value and provides information on pattern of metastatic spread and behaviour. For example, pure grade 1 tubular carcinoma has an exceptionally good long-term prognosis when compared with other grade 1 invasive carcinomas. Caution should be exercised in typing carcinomas in poorly fixed specimens or if they have been removed from patients who have been treated by neoadjuvant chemotherapy or radiotherapy prior to surgery.

Typing of breast carcinomas has been shown in the NHSBSP EQA scheme to be relatively poorly reproducible and the system has been revised with emphasis on concordance and recognition of pure special types.

5.1 Tumour type categories

5.1.1 Pure special type

A pure special type invasive tumour is a classical example of a particular tumour type, showing the hallmark histological features, and one that other Histopathologists would recognise as such. The definition requires 90% of the tumour to show the classical features (e.g. a tumour showing 90% mucinous features is classified as being of pure mucinous carcinoma type, etc). Special type tumours in general have characteristic, usually favourable, clinical prognostic characteristics, as described below.

5.1.2 Invasive carcinoma of no special type

The invasive tumour shows none, or less than 50%, of special type tumour morphology. This is the commonest category of invasive breast cancer and is often described as invasive ductal carcinoma. However, in view of the lack of specific defining histological characteristics the

term invasive carcinoma, no special type or no specific type (NST) is preferred (see section 6.2.1 below).

5.1.3 Mixed invasive tumour

This is a relatively common pattern of invasive breast carcinoma. The tumour may be heterogeneous in morphology with some characteristic special type areas (more than 50% but less than 90%). For example, there may be areas of pure tubular differentiation within a tumour otherwise showing no special type features. Alternatively, there may be or one or more characteristics of a special type but the full combination of features required for pure special type designation are not present, such as a distinctive lobular infiltrative growth pattern with non-lobular cell morphology; of note, this is different from pleomorphic lobular carcinoma and is also different from tumours that include a mixture of specific lobular subtypes (such as mixed solid and classical lobular architectures). In mixed invasive carcinomas the special type characteristic should be identified as an additional feature in the histology report.

5.1.4 Other primary breast carcinoma

Other primary breast carcinomas should be entered under this heading and include variants such as carcinoma with apocrine differentiation, carcinoma with neuroendocrine differentiation, salivary gland type tumours (e.g. adenoid cystic carcinoma), secretory carcinoma, etc.

5.1.5 Other malignant tumour

Non-epithelial tumours and secondary malignancies are included in this category. For purposes of convenience, malignant phyllodes tumours should be recorded here.

5.1.6 Not assessable

This category should be ticked only if an invasive carcinoma cannot be assigned to any of the previous groups for technical reasons, e.g. the specimen is too small or poorly preserved.

5.2 Morphological types of invasive breast cancer

The more common types are described below.

5.2.1 Invasive carcinoma of no special type (NST) (Figures 30a and 30b and 41)

This group includes invasive carcinomas that cannot be entered into any other category on the form, or classified as any of the less common variants of invasive breast carcinoma. The tumour shows less than 50% special type characteristics.

Invasive carcinomas of no special type are the most common invasive breast carcinomas, accounting for up to 75% in published series. They constitute a heterogeneous group in terms of morphological appearance including tumour margin, cytonuclear appearances and growth pattern, presence or absence of a lymphoid reaction, histopathological prognostic parameters and tumour marker biology. Some high-grade NST invasive carcinomas display medullary type features (see below, section 6.2.6). Rare variants of invasive carcinoma NST include pleomorphic carcinoma and carcinoma with osteoclast-like giant cells.

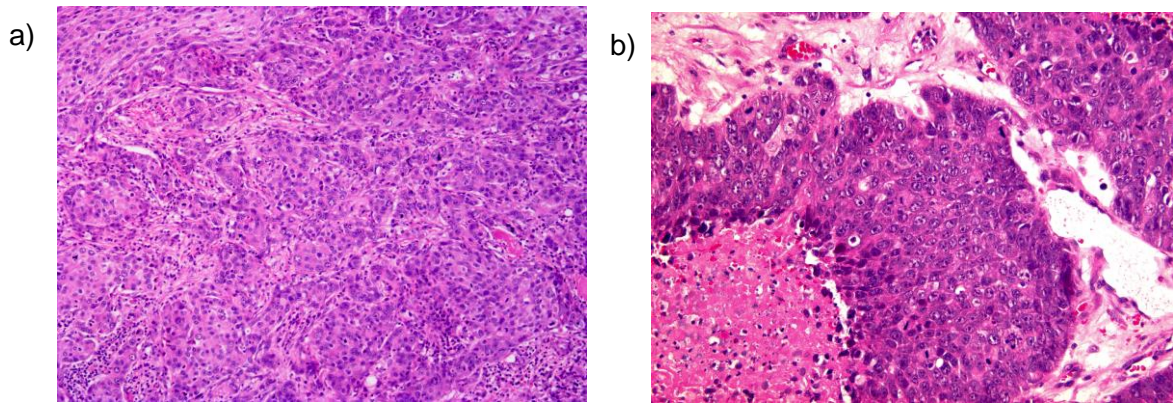


Figure 30: Examples of invasive carcinoma of no special type

5.2.2 Invasive lobular carcinoma (Figures 20e and 31)

Invasive lobular carcinoma is composed of small regular cells identical to those seen lobular *in situ* neoplasia. The cells frequently contain intracytoplasmic lumina although this finding is not specific to lobular carcinoma. Mitoses are infrequent. In classical invasive lobular carcinoma the cells are dissociated from each other or form single files or targetoid patterns around uninvolved ducts. Several variants have been identified in addition to this classical form:

- a) the alveolar variant exhibits small aggregates of 20 or more cells
- b) the solid variant consists of sheets of cells with little stroma. Mitotic activity is more frequent than that seen in classical invasive lobular carcinoma
- c) the tubulo-lobular type exhibits microtubule formation as part of the classical pattern. Tumours that show mixtures of typical tubular and classical lobular carcinoma are classified as mixed (see below)
- d) the pleomorphic variant is uncommon and exhibits the growth pattern of classical lobular carcinoma throughout but the cytological appearances, although retaining lobular characteristics, are more pleomorphic than those seen in classical invasive lobular carcinoma. Apocrine or histiocytoid differentiation may be seen in this variant. Pleomorphic invasive lobular carcinoma may also be accompanied by pleomorphic lobular carcinoma *in situ* (see section 4.5.2)
- e) lobular mixed type lesions consist of mixtures of the above subtypes of lobular carcinoma.

At least 90% of the tumour should exhibit one or more of the above patterns to be classified as invasive lobular carcinoma.

The majority of invasive lobular carcinomas are E-cadherin negative. However, 10–20% of cases express E-cadherin³⁸, such that positive staining, albeit weak or aberrant, should not be used to re-classify a tumour considered to be a typical invasive lobular carcinoma on H&E.

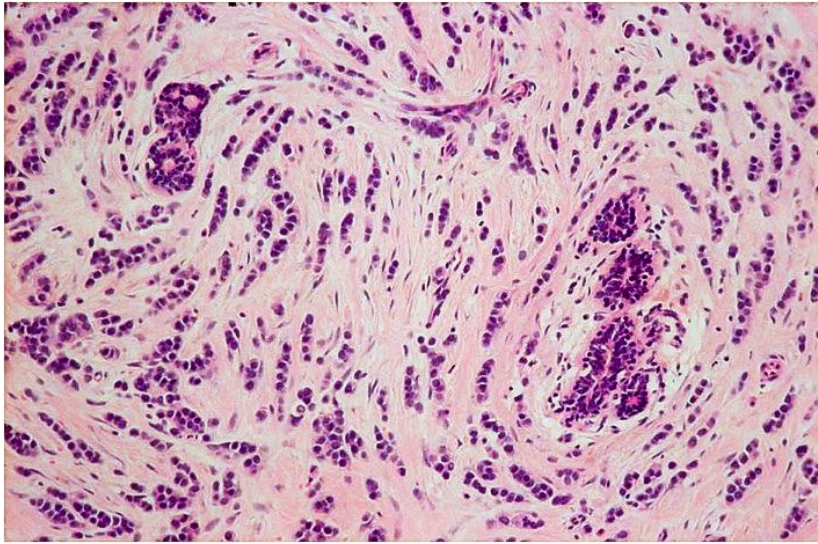


Figure 31: An example of classical invasive lobular carcinoma

5.2.3 Tubular carcinoma (Figures 32a to 32e)

Tubular carcinoma is composed of round, ovoid, or angulated single layered tubules, haphazardly distributed in a cellular fibrous or fibro-elastotic stroma. The neoplastic cells are small, uniform and may show cytoplasmic apical snouting. Nuclei should not show high-grade degrees of atypia. Neoplastic tubules typically infiltrate fat peripherally. Tubular carcinoma may co-exist with flat epithelial atypia, low-grade ductal carcinoma *in situ* and lobular neoplasia (so called low-grade neoplasia family). At least 90% of the tumour should exhibit the classical growth pattern to be classified as tubular. However, if the co-existent carcinoma is solely of the invasive cribriform type then the tumour should be typed as tubular if the tubular pattern forms over 50% of the lesion.

5.2.4 Invasive cribriform carcinoma

Invasive cribriform carcinoma is composed of masses of small regular cells as seen in tubular carcinoma. The invasive islands, however, exhibit a cribriform rather than a tubular appearance. Apical snouting is often present. Lumina may contain mucin with accompanying microcalcifications. Nuclei should not show high-grade degrees of atypia. In a rare variant of invasive cribriform carcinoma the stroma contains haemosiderin and osteoclast-like giant cells are seen in association with the tumour cells.

More than 90% of the tumour should exhibit the cribriform appearance except in cases where the only co-existent pattern is tubular carcinoma when over 50% must be of the cribriform appearance in order to be classified as invasive cribriform type.

If a diagnosis of invasive cribriform carcinoma is preferred, the 'tubular' box should be ticked and appropriate comment made under 'Comments/Additional Information'.

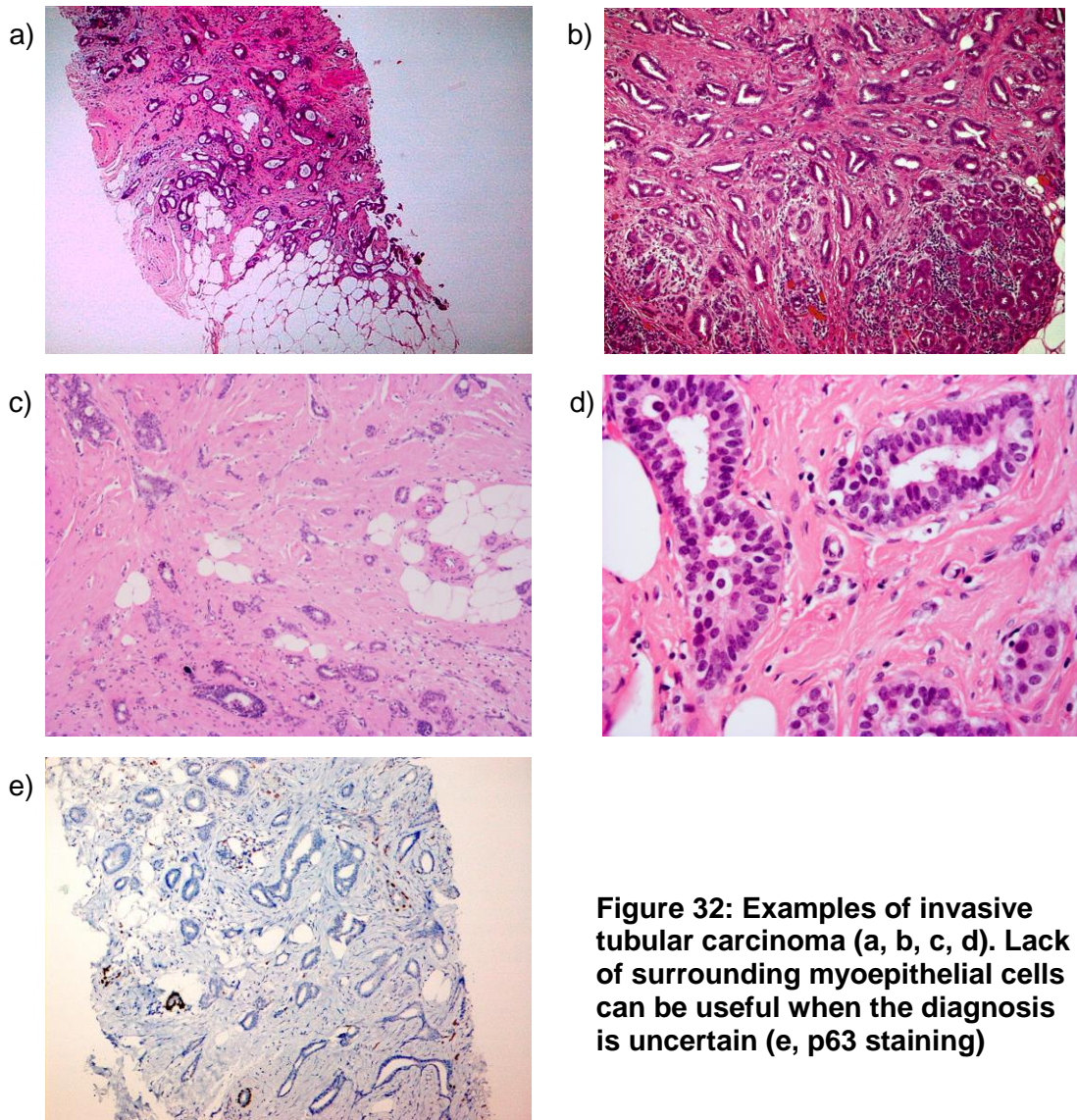


Figure 32: Examples of invasive tubular carcinoma (a, b, c, d). Lack of surrounding myoepithelial cells can be useful when the diagnosis is uncertain (e, p63 staining)

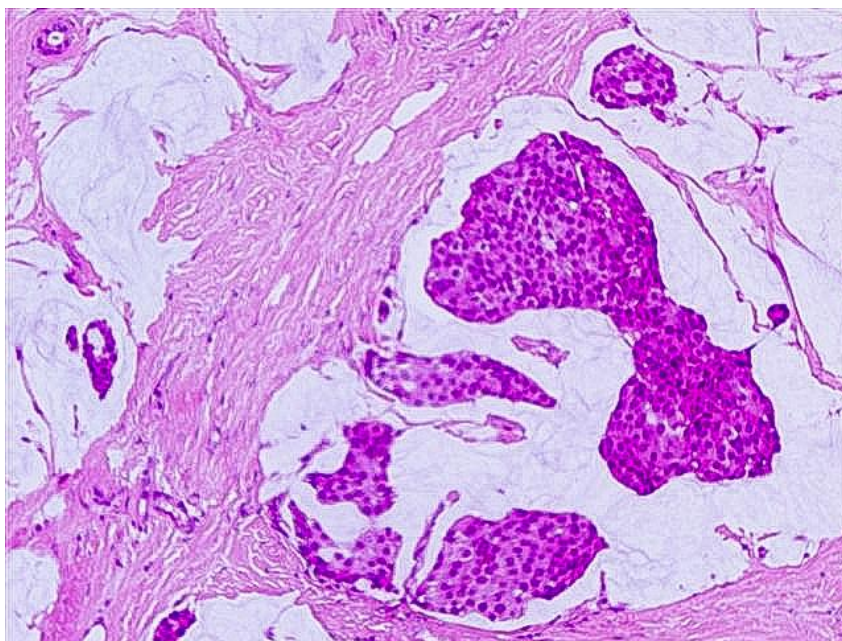


Figure 33: An example of a mucinous carcinoma

5.2.6 Invasive carcinoma with medullary features (medullary-like) (Figure 34)

The collective term of invasive carcinoma with medullary features (medullary-like) is now preferred for tumours considered to represent classical medullary, atypical medullary and the subset of invasive carcinoma NST with medullary characteristics with a relaxation of the strict rules described below for some of these entities, particularly pure medullary carcinoma. These tumours demonstrate all or some of the following features: a circumscribed or pushing border, a syncytial growth pattern, cells with high-grade nuclei, and prominent lymphoid infiltration.

Classical medullary carcinoma is uncommon and requires a circumscribed or pushing margin, a syncytial growth pattern in 75% of the tumour, grade 3 vesicular nuclei with prominent nucleoli, a prominent tumour lymphoplasmacytic infiltrate, and absence of tubular structures (Figure 34). Surrounding *in situ* elements are rare. These features must be present in 90% or more of the tumour. The term atypical medullary carcinoma refers to tumours that display some but not all of the above features. The atypical medullary group has been defined by both Fisher *et al*³⁹ and Ridolfi *et al*⁴⁰. These tumours may show less lymphoid infiltration, less circumscription or areas of dense fibrosis, while still having the other features of a medullary carcinoma. A well-circumscribed tumour may be classified as atypical medullary if up to 25% is composed of 'NST' type and the rest comprises classical medullary carcinoma. If in doubt the tumour should be classified as 'invasive carcinoma, NST'.

A subset of invasive carcinoma NST with medullary features (high nuclear grade, circumscribed/pushing margin, lymphocyte-rich stroma) has been observed, most frequently in patients with inherited BRCA1 gene mutations. The tumours cross the spectrum of classical medullary, atypical medullary and invasive carcinoma NST with a lymphocyte rich stroma. Their identification has called into question the value of the traditional definitions of medullary and atypical medullary carcinoma and has highlighted the difficulty in consistently applying the proposed diagnostic criteria. Of all histological tumour types medullary carcinoma has the worst concordance in the EQA scheme. As a result of these considerations the collective term of invasive carcinoma with medullary features (medullary-like) is now preferred for tumours considered to represent classical medullary, atypical medullary and the subset of invasive carcinoma NST with medullary characteristics.

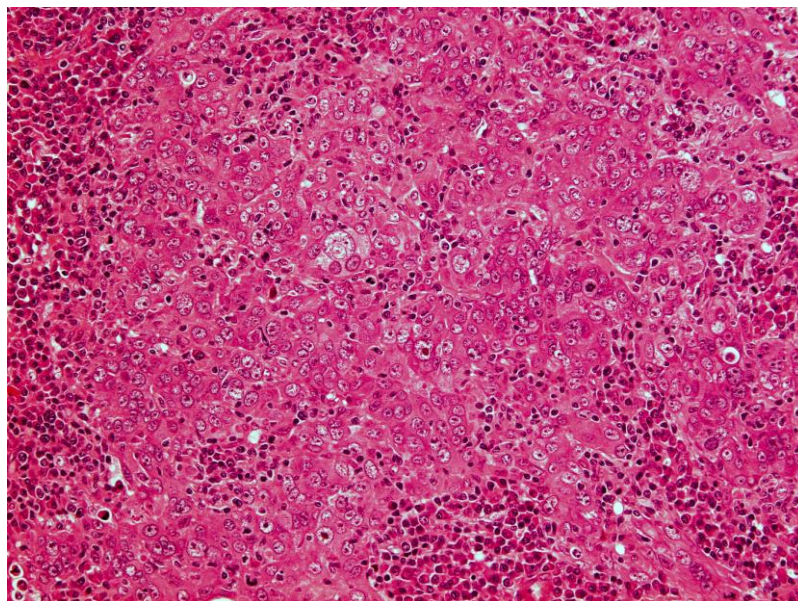


Figure 34: An example of medullary-like carcinoma. Note the syncytial sheet tumour cell structure

5.2.7 Invasive micropapillary carcinoma (Figure 35)

Invasive micropapillary carcinoma is composed of aggregates of cuboidal to columnar neoplastic cells that are 'hollow' and devoid of fibrovascular cores, and are surrounded by empty stromal spaces (Figure 35). These may give the impression of vascular spaces at low power but the spaces are not lined by endothelial cells. The neoplastic cells display reverse polarity such that the apical pole of the cell faces out to the stromal space rather than in to the central hollow or lumen. This can be demonstrated using epithelial membrane antigen immunohistochemistry. These tumours are usually grade 2 or 3 and have a propensity for lymphovascular invasion.⁴¹

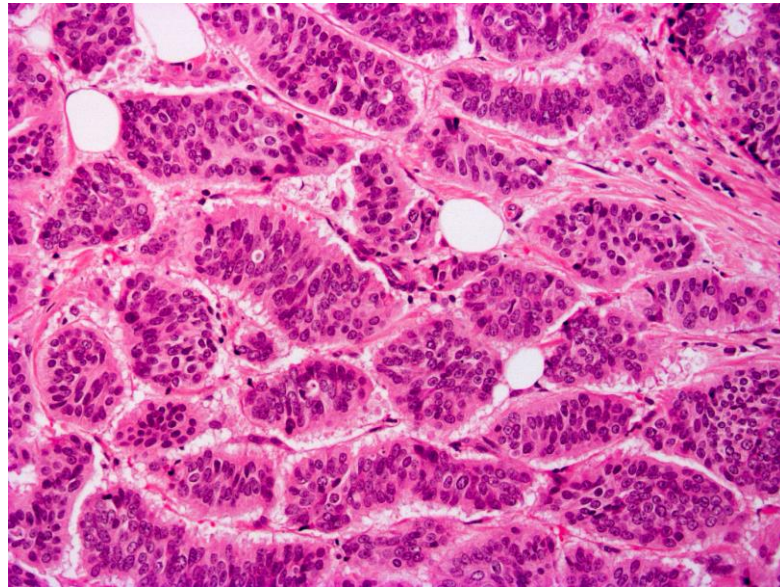


Figure 35: An example of invasive micropapillary carcinoma

5.2.8 Invasive papillary carcinoma

This is an uncommon tumour characterised by papillae formed by malignant epithelial cells related to fibrovascular cores. The tumour has an infiltrative edge in contrast to the rounded contour observed in encysted papillary carcinoma (see section 5.3).

5.2.9 Metaplastic carcinoma

Metaplastic carcinoma is a collective term for a heterogeneous group of tumours showing differentiation of malignant epithelium into squamous or mesenchymal elements, e.g. spindle, chondroid, osseous cells. These tumours may be entirely composed of metaplastic elements or may be a mixture of metaplastic elements and conventional invasive carcinoma NST including DCIS. Variants of metaplastic carcinoma include squamous cell carcinoma, low-grade adenosquamous carcinoma, fibromatosis-like carcinoma (Figure 36a), spindle cell carcinoma including myoepithelial carcinoma (Figure 36b), and metaplastic carcinoma with mesenchymal differentiation.

Metaplastic squamous cell carcinoma usually derives from a cystic lesion lined by atypical squamous cells. The cells infiltrating the underlying stroma tend to show squamous and spindle cell morphology, and an accompanying inflammatory reaction. Metaplastic squamous cell carcinoma may be pure or admixed with conventional carcinoma NST. Care should be taken to distinguish these from metastatic squamous carcinomas and infiltration by primary skin squamous cell carcinoma.

Low-grade adenosquamous carcinoma comprises a mixture of well-formed glandular structures and solid nests of squamous cells with a background population of spindle cells.^{42–45}

Fibromatosis-like metaplastic carcinoma (Figure 36a) is composed of bland spindle cells with minimal atypia and low mitotic activity.⁴⁶ Squamous differentiation and collections of epithelioid cells may be observed. Due to the lack of cytological atypia and low mitotic activity this tumour may be misdiagnosed as benign. Cytokeratin immunohistochemistry is useful in confirming the diagnosis (see Appendix G).

Spindle cell carcinoma shows a greater degree of cytological atypia than that seen in fibromatosis-like metaplastic carcinoma and has a more aggressive behaviour.⁴⁷ Areas of conventional carcinoma NST, foci of ductal carcinoma *in situ*, and squamous differentiation may be identified. A peripheral inflammatory infiltrate is frequently present. Myoepithelial carcinoma is included in this category.

Metaplastic carcinoma with mesenchymal differentiation is usually composed of mesenchymal elements, e.g. osteoid, chondroid, and areas of recognisable carcinoma. The mesenchymal elements show varying degrees of differentiation and may appear frankly sarcomatous. Thorough sampling may be required to demonstrate the carcinomatous component. In rare cases carcinomatous elements cannot be identified and high molecular weight cytokeratin immunohistochemistry may facilitate the diagnosis.

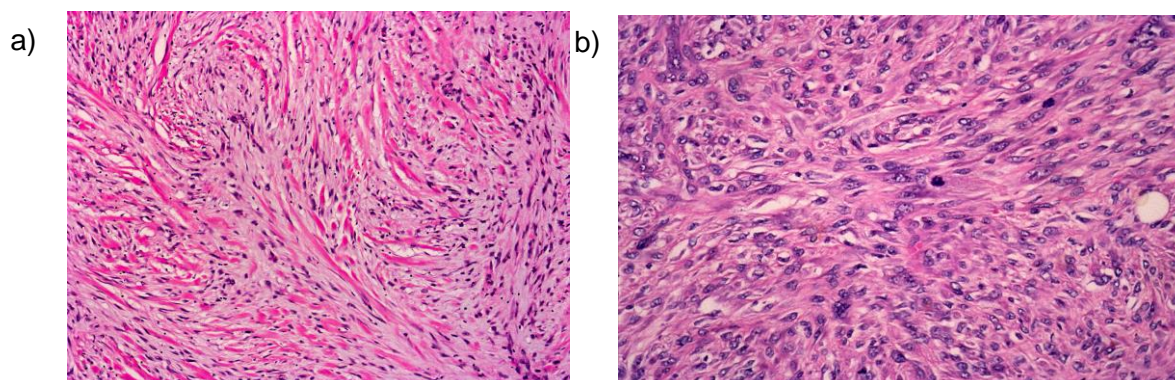


Figure 36: Examples of metaplastic spindle cell carcinoma of low-grade fibromatosis-like type (a) and high-grade metaplastic breast carcinoma type (b)

6 RCPATH core data items

6.1 Basic data items

6.1.1 Side

Indicate left or right breast. For specimens from both sides, or from different sites within one breast, a separate form should be completed for each.

6.1.2 Pathologist

The name of the reporting pathologist(s) should be recorded. In breast screening related cases the consultant histopathologist must be registered at the breast screening office, otherwise their name will not be recognised by the computer.

6.1.3 Date

Record date of surgery, date of receipt by laboratory and date of authorisation.

6.1.4 Specimen radiograph seen

Indicate if you have seen a specimen radiograph.

6.1.5 Mammographic abnormality present

Are you satisfied that the mammographic abnormality is present in the specimen? This may necessitate consultation with the radiologist responsible for examining the specimen radiograph. It is worth remembering that breast calcification may be due to calcium oxalate salts (Weddelite), which can be detected optimally in histological sections using polarised light.

6.1.6 Histological calcification

If considered appropriate use this box to indicate if calcification observed radiologically was seen on histological sections and, if so, whether it is present in benign or malignant changes, or both.

6.1.7 Specimen type

- Therapeutic wide local excision (wire-guided or palpable)
- Excision biopsy
- Diagnostic localisation specimen
- Segmental excision (to include wedge excisions, partial mastectomy and re-excision specimens for clearance of margins)
- Mastectomy (to include completion, risk-reducing, skin-sparing)
- Subcutaneous mastectomy
- Re-excision specimens
- Further margins (including cavity shaves/bed biopsies)
- Duct excision specimens, to include microdochectomy/microductectomy/Hadfield's procedure/total duct excision
- Sentinel lymph node
- Axillary sampling
- Axillary lymph node clearance (level I, II or III)
- Vacuum-assisted core excisions.

6.1.8 Specimen weight

Record the weight of all surgical excision specimens, including shave and re-excision specimens. Weight is more reproducible than three-dimensional measurement to determine volume, even taking into account the different densities of fat and fibrous tissue, which vary in proportion in breast specimens. Specimen weight is also used as the means of determining the likely cosmetic disadvantage to women undergoing benign biopsy in the NHS BSP.

[Level of evidence – GPP.]

6.1.9 Benign/malignant lesion present

Tick the appropriate 'Yes' box if any benign or malignant lesion is present and 'No' if none is identified. Both benign and malignant may be ticked as 'Yes'.

6.2 Tumour classification and prognostic factors

6.2.1 Tumour size

The accurate measurement of tumour size is important as it is a component of prognostic indices and informs the T stage. Accurate identification of the tumour boundary is also a prerequisite for valid assessment of resection margin clearances. Experience from the NHS BSP EQA scheme shows frequent poor concordance on tumour size, not explicable by slide-to slide variation. As such poor concordance is on ready-prepared slides, the potential to arrive at an inaccurate size measurement when one takes into account the additional difficulties of specimen dissection must be even greater. What follows therefore includes some practical suggestions on ways of arriving at accurate size measurements.

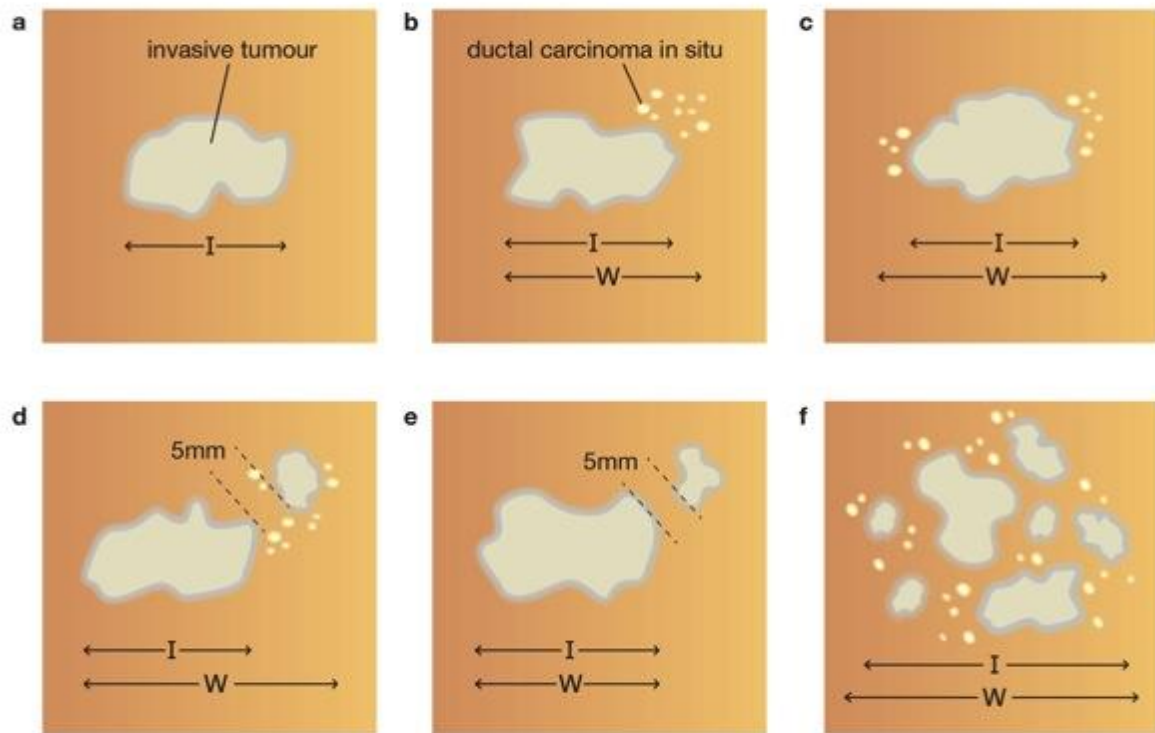
6.2.1.1 Invasive tumour size

This section should refer to the maximum dimension of the invasive tumour (see Figure 37). The maximum dimension of any invasive tumour should be measured in the fresh and/or fixed state macroscopically. Care should be taken in the case of ovoid tumours that the largest dimension is measured and blocked, bearing in mind that this may not be the plane initially incised, nor precisely in any one of the medial/lateral, superior/inferior or deep (posterior)/superficial (anterior) directions. If a specimen radiograph is available then the plane of maximum dimension can be assessed before slicing. It is recognised that for circumscribed tumours, the macroscopic measurement may be accurate if measured to the nearest millimetre but for diffuse tumours it may be more problematic to define the precise borders of the tumour.

Tumour size should be measured in millimetres and the invasive tumour size entered in the field 'MAXIMUM DIMENSION (invasive component).....' on the reporting form. Satellite lesions should not be included in the measurement of the maximum invasive tumour dimension, nor should foci of lymphovascular invasion. On occasions it may be difficult to be certain whether foci of invasive carcinoma close to each other within a section represent (a) the main mass in continuity but out of the plane of the histological section or (b) a satellite focus separate from the main mass. Features that may be of assistance include the presence of normal breast parenchymal structures between the two deposits and the distance between the foci. It is impossible to define strictly a distance between the foci that can be used to decide whether one is a satellite deposit from another. If, however, the foci are 5 mm or more apart the chances of the deposits representing one tumour appearing as separate foci due to plane of slicing are low.

Pathology measurement of tumour size is considered the 'gold standard', however a pragmatic approach must be taken to measurement of invasive tumour size and common sense applied when definitive size measurement cannot be given. Where accurate measurement is not feasible then the tumour size identified by imaging, based on ultrasound, mammographic or MRI, should be used as the best available record of true tumour size and should replace pathological size assessment. Finally (and least accurately), clinical size can be compared.

Measurement of carcinomas with an invasive component



I = invasive tumour measurement W = whole tumour measurement

In e, the satellite focus of invasive tumour is not included in the measurement.

In f, the best estimate of the total size of the invasive component is given.

Figure 37: Illustrations of how to measure invasive and whole tumour sizes in various scenarios

Please note that d and e illustrate examples of multiple invasive foci where the invasive foci are 5 mm or more distant (see section 6.2.1.4: Disease extent)

Where there is a discrepancy between the macroscopic size and the microscopic size then the latter should be recorded provided it is certain that the true plane of maximum dimension has been included in the slide or slides. For example, an ovoid tumour 11 x 8 x 8mm may be underestimated histologically as 8 mm if the plane of block selection is through the centre rather than the long axis.

To assist accurate size measurement, one simple option is to dot the periphery of the tumour on the slide under the microscope (taking care to include the most peripheral cells or the furthest points of any stellate spurs of tumour protruding into the parenchyma) with a marker pen (Figure 38) and then measuring the greatest distance between the points with a clear ruler, a piece of metric graph paper photocopied at 1:1 on to acetate sheet or using a dome magnifier with measuring reticule (Figure 39) applied directly over the histological slide. Measurement of histological size from the tissue sections can also be made using the Vernier stage micrometer. Care should be taken not to involve the microscope magnification in the measurement – the diameter is that actually demonstrated on the slide. Importantly, the slide must be placed at the appropriate angle on the microscope stage so that the largest dimension is determined. Some pathologists use measuring callipers or dial callipers. Some photomicrography systems allow digital measurement of linear distance between two points clicked on by a mouse – the measurement is likely to be accurate provided that the system is calibrated for each objective and that the digital system detects or is told which objective is in use.

[Level of evidence – A. Invasive tumour size is a recognised important prognostic factor which is used in treatment planning, for staging purposes (TNM) and as a quality target in the NHSBSP. Accurate size measurement is expected.]

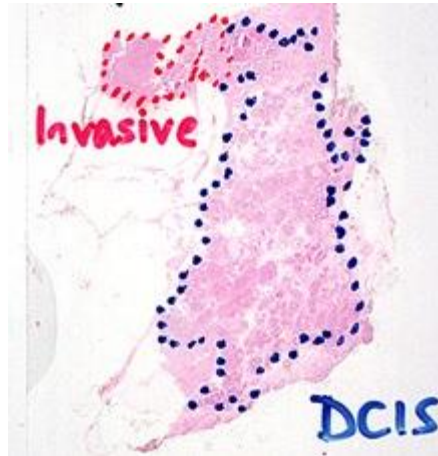


Figure 38: Marking the microscope slide can aid size measurement




Figure 39: A simple lens measuring device can aid size measurement

6.2.1.2 Whole tumour size – invasive tumour and surrounding DCIS

The largest dimension of the whole tumour to include the invasive and *in situ* (DCIS or pleomorphic lobular carcinoma *in situ*, but not classical LCIS) should be included in this section (see Figure 37).

There is no internationally recognised definition of extensive ductal carcinoma *in situ*, but it has been reported that, on excision of an invasive carcinoma with a small margin of normal tissue, surrounding extensive DCIS is associated with increased risk of local recurrence. Where more extensive excision is performed, however, the significance of this factor is markedly reduced. This problem relates to adequate excision of tumour with associated *in situ* component and is considered to be the same problem as evaluating complete excision of pure DCIS.

The invasive tumour should be measured, as above, but the assessment of the whole tumour size including *in situ* carcinoma (DCIS or, rarely pleomorphic LCIS) presents the same

problems as in the previous section (see Figure 37). The measurement of DCIS associated with invasive carcinoma should be recorded in the whole tumour size field on the reporting form, including tumours which are predominantly composed of DCIS but have multiple foci of invasion. Measurement of the invasive component in this latter case can be problematic and the best estimate of the invasive tumour burden should be given in the size of invasive tumour field. It is recommended that pathologists take blocks from macroscopically normal tissue between an excised tumour and the excision margins in all three planes of section. Slice specimen radiography may help in this assessment.

If a tumour is insufficiently delineated to be measured accurately, a comment should be made in the Comments/Additional information field on the reporting form.

[Level of evidence – B. Whole tumour size is used in treatment planning. Accurate size measurement is expected.]

6.2.1.3 *In situ* carcinoma size

This section should be completed for pure DCIS or pleomorphic lobular *in situ* lesions where no invasive disease is seen. Lobular *in situ* neoplasia of classical type is generally multifocal and measurement of the extent of this disease is unreliable, unnecessary and unhelpful. Because it is becoming apparent that pleomorphic lobular carcinoma *in situ* has a high incidence of giving rise to local ipsilateral invasive carcinoma, and may be less likely to be multifocal/bilateral, i.e. it behaves more like DCIS, it is recommended that pleomorphic lobular carcinoma *in situ* be measured as for DCIS, and the resection margin clearances for it quoted. Undoubtedly, however, the measurement of DCIS in two-dimensional slides is at best an underestimate of the total size of the *in situ* change. The tree-like branching structure of normal breast ducts means that ductal carcinoma *in situ* rarely forms a rounded mass and ramifies within the affected duct system. Of especial note is the extension of the *in situ* tumour into the major ducts running towards the nipple.

Large blocks can help to delineate *in-situ* disease. The two dimensional nature of slides may not give the true extent of disease and block taking and measurement should be correlated with the specimen radiograph. Where the size measured is less than the size on the radiograph then further blocks should be taken to identify the limit of the calcification seen on radiography.

The measurement of the size of pure DCIS lesions (or pleomorphic or DCIS like LCIS) should be recorded on the reporting form in the field under non-invasive tumour 'SIZE (ductal only), **not** in the whole tumour size field under invasive carcinoma.

[Level of evidence – A. DCIS size is a recognised predictive factor for local recurrence which is used in treatment planning. Accurate size measurement is expected.]

6.2.1.4 Disease extent

The fields for disease extent on the form have been a source of confusion in the past due to debates about the definition of multicentric or multifocal. The fields are now given as localised or multiple invasive foci. The field is present to record the presence or absence of multiple foci of invasive tumour within the specimen, clearly separate from each other and not connected by associated DCIS.

It is not intended that a tumour with multiple areas of invasion within extensive DCIS be classified as multiple (see figure 37 f).

It should be noted that DCIS is a unifocal disease although it may be extensive.^{19, 20}

The designation of multiple foci should be reserved for multiple separate areas of invasive tumour, such as occurs with invasive lobular carcinoma or tumours with extensive lymphovascular invasion where there are multiple areas of invasive tumour due to extravasation of tumour cells from lymphatics and establishment of separate satellite invasive tumour foci. As noted above (in tumour size section) it can be difficult, if not impossible, on rare occasions to determine whether two adjacent foci represent satellite foci or one lesion mimicking this process due to plane of sectioning. A pragmatic approach is required; the presence of intervening normal tissue and increasing distance between foci are features that indicate that these are more likely to be multiple foci than a localised process. A distance of 5 mm or greater is often used to define a separate focus (see Figure 37 d, e).

Multiple synchronous primary tumours of different types should be categorised as multiple. It is recognised that this may be difficult to assess and so a 'Not assessable' box is included on the form for cases where there is doubt.

[Level of evidence – B. Tumour extent and presence of multiple invasive foci has important implications for treatment planning. Accurate assessment is expected.]

6.2.2 Histological grade (see Appendix I)

Histological grading provides powerful prognostic information.^{48,49} It requires some commitment and strict adherence to the accepted protocol. The method used is that described originally by Elston and Ellis⁵⁰ and involves the assessment of three components of tumour morphology: tubule/acinar/glandular formation, nuclear atypia/pleomorphism and frequency of mitoses. Each is scored from 1 to 3 (see Appendix I). Adding the scores gives the overall histological grade, as shown below.

Some degree of variation in appearance from one part of a tumour to another undoubtedly occurs; this is particularly true of tumours of mixed type. Assessment of tubular differentiation is made on the overall appearances of the tumour and so account is taken of any variation. Nuclear appearances are evaluated at the periphery and/or least differentiated area of the tumour to obviate differences between the growing edge and the less active centre.

Do not expect equal numbers of cancers to fall in each grade category. Published ratios for grades 1, 2 and 3 are approximately 2:3:5 in symptomatic breast cancer,⁵⁰ so about half of all symptomatic cancers are grade 3. If audit of grade distribution shows substantially fewer grade 3 cases, or a majority of grade 2 cases, grading protocols should be carefully reviewed. Screen detected cancer series are likely to include a smaller proportion of high-grade cases; for example, the East Midlands Regional NHS BSP audit (2004–2010) covering a 6 year period showed a histological grade distribution of 28% grade 1, 52% grade 2 and 20% grade 3 invasive carcinomas (Rahul Deb, personal communication).

6.2.2.1 Tubule/acinar formation

All parts of the tumour are scanned and the proportion occupied by tumour islands showing clear acinar or gland formation or defined tubular structures with a central luminal space is assessed semi-quantitatively. This assessment is generally carried out during the initial low power scan of the tumour sections.

Score

1. >75% of tumour forming tubular structures
2. 10–75% of tumour
3. <10% of tumour.

In the assessment of tubule formation, only structures in which there are clearly defined central lumens, surrounded by polarised tumour cells, should be counted. This does,

however, include larger islands of tumour with central gland formation, as may be seen in mucinous carcinoma or invasive micropapillary tumours. A tumour in which 75% or more of its area is composed of such structures would score 1 point for tubule formation.

6.2.2.2 Nuclear atypia/pleomorphism

Individual pathologists differ markedly in their approach to nuclear grading, and breast specialists appear to allocate higher grades than non-specialists.⁵¹ Few cancers possess the very bland nuclei warranting an atypia/pleomorphism score of 1, and obvious atypia/pleomorphism should attract a score of 3. The minimum proportion of tumour nuclei which should show marked nuclear atypia/pleomorphism before a score of 3 is allocated has not been defined, but the finding of an occasional enlarged or bizarre nucleus should not be used to give a score of 3 rather than a score of 2.

Score

1. Nuclei small with little increase in size in comparison with normal breast epithelial cells, regular outlines, uniform nuclear chromatin, little variation in size
2. Cells larger than normal with open vesicular nuclei, visible nucleoli and moderate variability in both size and shape. (Figures 20e, 32d)
3. Vesicular nuclei, often with prominent nucleoli, exhibiting marked variation in size and shape, occasionally with very large and bizarre forms. (Figures 30b, 34)

6.2.2.3 Mitoses (Figure 40)

Accurate mitosis counting requires high quality fixation, obtained when fresh specimens are sectioned promptly as well as tumour blocks of optimal thickness (3–4 mm) fixed immediately in neutral buffered formalin. This can be achieved without compromising the evaluation of resection margins.

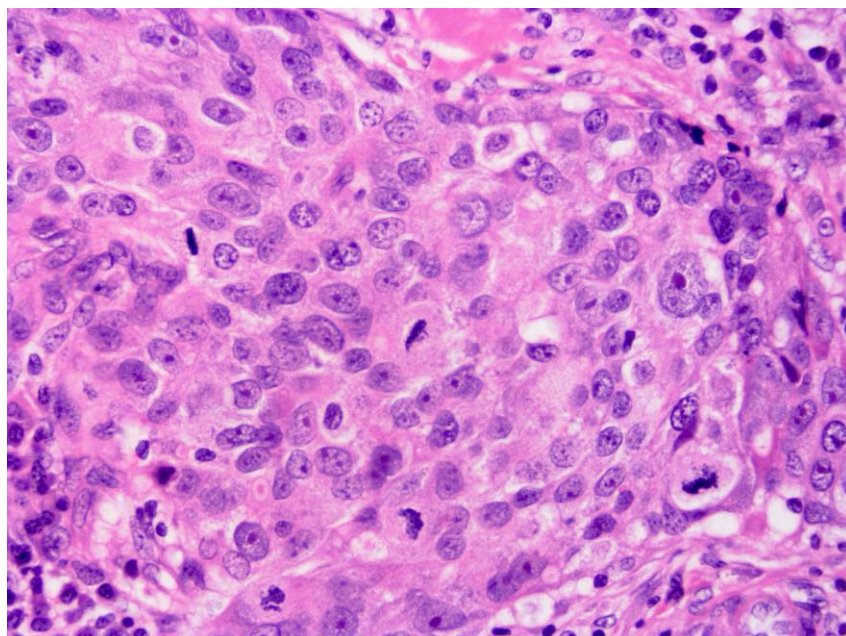


Figure 40: Prompt fixation aids mitotic figure identification

Table 6: Mitotic counts by X40 lens microscopic field diameter

Field diameter (mm)	Number of mitoses corresponding to		
	Score 1	Score 2	Score 3
0.40	up to 4	5 to 9	10 or more
0.41	up to 4	5 to 9	10 or more
0.42	up to 5	6 to 10	11 or more
0.43	up to 5	6 to 10	11 or more
0.44	up to 5	6 to 11	12 or more
0.45	up to 5	6 to 11	12 or more
0.46	up to 6	7 to 12	13 or more
0.47	up to 6	7 to 12	13 or more
0.48	up to 6	7 to 13	14 or more
0.49	up to 6	7 to 13	14 or more
0.50	up to 7	8 to 14	15 or more
0.51	up to 7	8 to 14	15 or more
0.52	up to 7	8 to 15	16 or more
0.53	up to 8	8 to 16	17 or more
0.54	up to 8	8 to 16	17 or more
0.55	up to 8	9 to 17	18 or more
0.56	up to 8	9 to 17	18 or more
0.57	up to 9	9 to 18	19 or more
0.58	up to 9	10 to 19	20 or more
0.59	up to 9	10 to 19	20 or more
0.60	up to 10	10 to 20	21 or more
0.61	up to 10	10 to 21	22 or more
0.62	up to 11	12 to 22	23 or more
0.63	up to 11	12 to 22	23 or more
0.64	up to 11	12 to 23	24 or more
0.65	up to 12	13 to 24	25 or more
0.66	up to 12	13 to 24	25 or more
0.67	up to 12	13 to 25	26 or more
0.68	up to 13	13 to 26	27 or more
0.69	up to 13	13 to 27	28 or more
0.70	up to 13	14 to 27	28 or more

Score

The mitosis score depends on the number of mitoses per 10 high power fields. The size of high power fields is very variable, so it is necessary to standardise the mitotic count using Table 6. The field diameter of the microscope should be measured using the stage graticule or a Vernier scale, and the scoring categories should be read from the corresponding line of Table 6 and Figure 41. Field diameter is a function of the objective lens and the eyepiece, so

if *either* of these is changed this exercise *must* be repeated. The field diameter can also be calculated simply by dividing field number by objective magnification; for example, if the eyepieces give field number 22 when using a x40 objective lens, the field diameter (in mm) is $22/40 = 0.55$ mm.

A minimum of 10 fields should be counted at the periphery of the tumour, where it has been demonstrated that proliferative activity is greatest on lower power search.^{52, 53} If there is variation in the number of mitoses in different areas of the tumour, the least differentiated area (i.e. with the highest mitotic count) should be assessed. If the mitotic frequency score falls very close to a score cut point, one or more further groups of 10 high power fields should be assessed to establish the correct (highest) score. It is recommended that identification of the most mitotically active or least differentiated part of the tumour forms part of the low magnification preliminary assessment of the histological section. This area should be used for mitotic count scoring. If there is no evidence of heterogeneity, mitotic scoring should be carried out at a part of the tumour periphery chosen at random. Fields chosen for scoring are selected during a random meander along the peripheral margin of the selected tumour area. Only fields with a representative tumour burden should be used. The low power scan of the tumour can be used to provide an assessment of the typical tumour to stromal ratio. Only definite mitotic figures (in any phase of the growth cycle) should be counted. Hyperchromatic nuclei and/or apoptotic nuclei should not be scored. Poor quality fixation can result in underscoring of mitotic frequency; optimal fixation is essential.

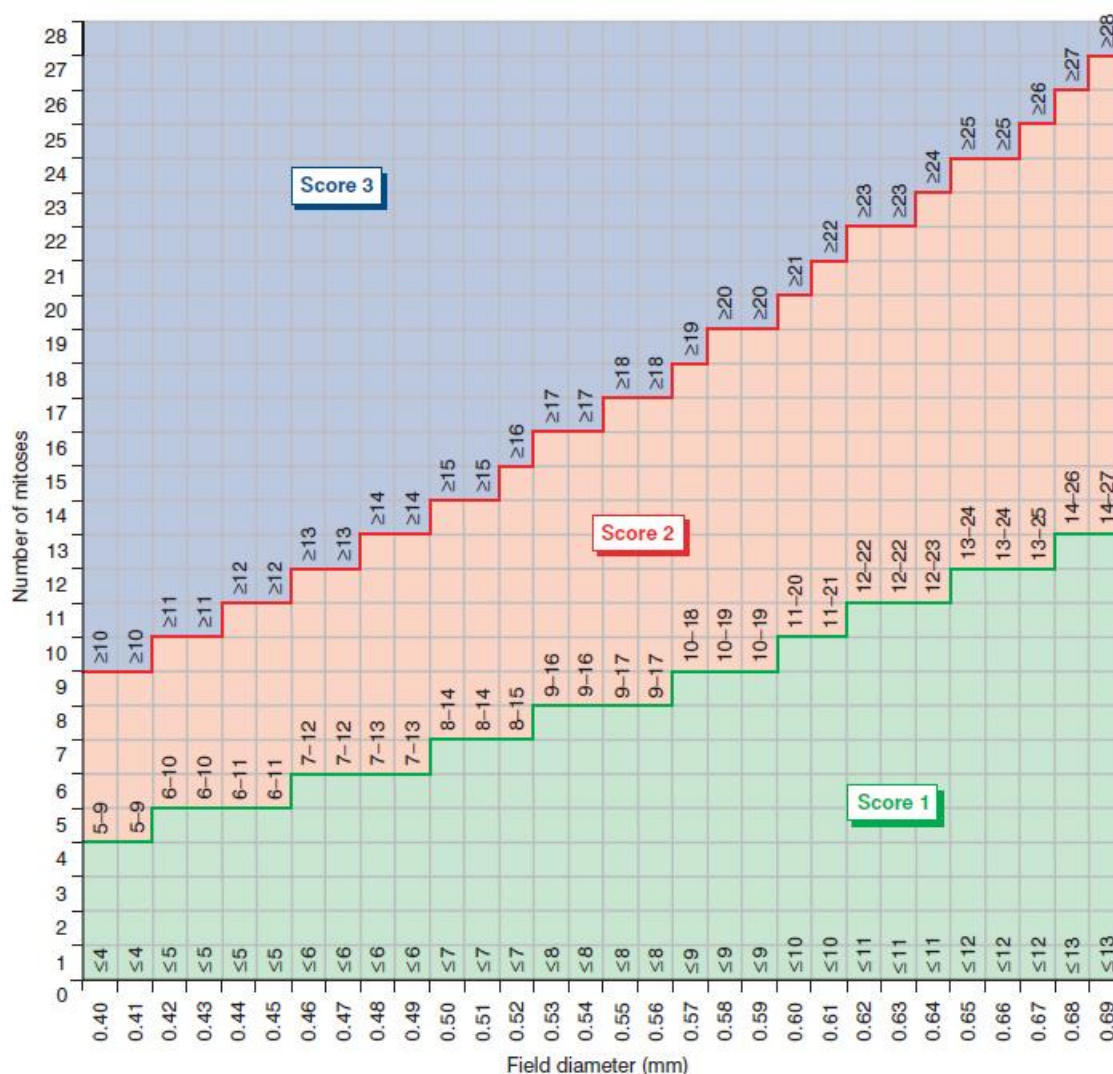


Figure 41: Mitotic count cut points for 10 high power fields by high power lens diameter

6.2.2.4 Overall grade

The use of terms such as well differentiated or poorly differentiated in the absence of a numerical grade is inappropriate. The scores for tubule formation, nuclear pleomorphism and mitoses are then added together and assigned to grades, as below:

Grade 1 = Scores of 3–5

Grade 2 = Scores of 6 or 7

Grade 3 = Scores of 8 or 9.

It is recommended that grading is not restricted to invasive carcinoma of no special type (ductal) but is undertaken on all histological subtypes. There are two major reasons for this recommendation:

- there are occasionally problems in deciding whether to classify a tumour as NST or some other subtype
- there may be significant variation in prognosis within certain subtypes, e.g. lobular carcinoma, and grading provides additional information.^{54,55}

‘Not assessable’ should be ticked if for any reason the grade cannot be determined, e.g. specimen poorly preserved or too small.

Grading systems other than that described above should not be used.

For audit and other purposes, it may be appropriate to record individual components of grade, including actual mitosis count and field size, which may have added prognostic significance within grade categories.⁵⁶

[Level of evidence – A. Invasive tumour grade is a recognised important prognostic factor which is used in treatment planning. Accurate assessment is expected.]

6.2.2.5 Assessment of grade on needle core biopsies

Histological grade can be assessed on core biopsies using the approach described above. This is of particular value if the patient has preoperative systemic treatment. There is about 70% agreement of grade on core biopsy with the corresponding surgical specimen.^{57,58} Usually the histological grade in the surgical specimen is used in preference to the core grade. However, if assessment of grade in the surgical specimen is compromised, for example by poor fixation or preoperative systemic treatment it is reasonable to use the mitotic count in the core biopsy. Another alternative is to use the mitotic count in nodal metastases if interpretation of grade is difficult in the primary carcinoma.

[Level of evidence – C. Some centres use histological grade determined from the diagnostic needle core biopsy as part of the criteria used to consider use of neoadjuvant chemotherapy.]

6.2.3 Lymphovascular invasion (Figure 42)

The presence of lymphovascular invasion is an adverse feature providing independent prognostic information about both local recurrence and survival.^{59–62} It is therefore important to record whether or not it is present. Because it is difficult to distinguish between lymphatic and venous channels, findings should be categorised as ‘lymphovascular spaces’ rather than as specific channels. This is supported by evidence identifying that most tumour emboli are present in lymphatic channels.

One of the major problems in trying to determine whether or not tumour cells are in a vessel is shrinkage artefact, so care should be taken, wherever possible, to ensure that there is optimal tissue fixation and processing. A clear rim of endothelium should be present before

considering that a lymphovascular space has been identified (Figure 42). The presence of unequivocal tumour in lymphovascular spaces should be recorded; if there is doubt, but it is considered to be very likely, it should be recorded as uncertain; and if not present it is categorised as not identified. Only lymphovascular invasion identified in breast tissue associated with the primary breast carcinoma should be recorded. Lymphovascular invasion identified elsewhere, for example in axillary tissue, should be described but not recorded formally as lymphovascular Invasion positive. Perineural invasion should not be recorded as lymphovascular invasion.

There are various features that may be helpful in trying to identify lymphovascular invasion and to recognise whether tumour cells are in definite lymphovascular spaces. These are:

- groups of tumour cells in spaces around the main tumour mass; ensure that any spaces are lined by endothelial cells and are not fat spaces (Figure 42)
- the presence of adjacent channels that may be of varying sizes
- the presence within the space of erythrocytes and/or thrombus
- shrinkage artefact results in nests of cells having the shape of the space in which they lie; endothelial cells will not be seen.

The best method for assessing lymphovascular invasion is the use of good quality, optimally fixed and processed H&E stained sections. Immunostaining for endothelial markers does not generally contribute further, but could be considered for difficult critical cases.

Lymphatic endothelial specific immunohistochemical markers have become available, such as D2-40 and can assist in detection of lymphatic vessel invasion.⁶³ There is insufficient evidence to recommend their use in routine clinical practice at present but they may be of help in more difficult cases.

[Level of evidence – B. Vascular invasion status is a recognised important prognostic factor which is used in treatment planning. Accurate assessment is expected.]

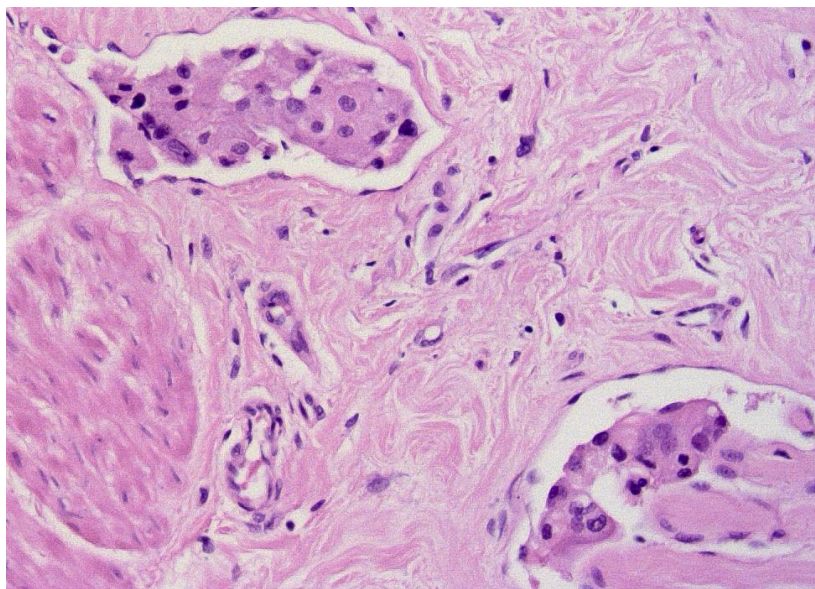


Figure 42: An example of lymphovascular invasion

6.2.4 Lymph node stage

All lymph nodes must be examined histologically, as noted in Chapter 1. Data from axillary nodes must be recorded separately from nodes from other sites.

Histological reports should include:

- the total number of lymph nodes identified
- the number of lymph nodes involved with metastatic disease, both macro- (Figures 43a and 43b) and micro- metastases. Of note, nodes with isolated tumour cell clusters (Figure 43c) are not regarded as involved/positive for metastasis
- specific axillary levels and nodes, i.e. the apical node, may have been identified by the surgeon and can be recorded independently, but they should also be included in the total lymph node figures
- in cases with only one involved node the metastasis should be measured and designated as a macro or micro metastasis
- although the presence of extracapsular spread extending from an involved lymph node can be noted under 'Comments/additional information', extranodal/axillary soft tissue metastatic tumour deposits are regarded as involved lymph nodes for the purposes of assessing the overall number of involved lymph nodes.

UK lymph node staging for breast cancer has been based on the following stratification system and which has been used to integrate into systems like the Nottingham Prognostic Index.

Stage 1: Node negative; Stage 2: 1–3 nodes positive; Stage 3: 4 or more nodes positive.

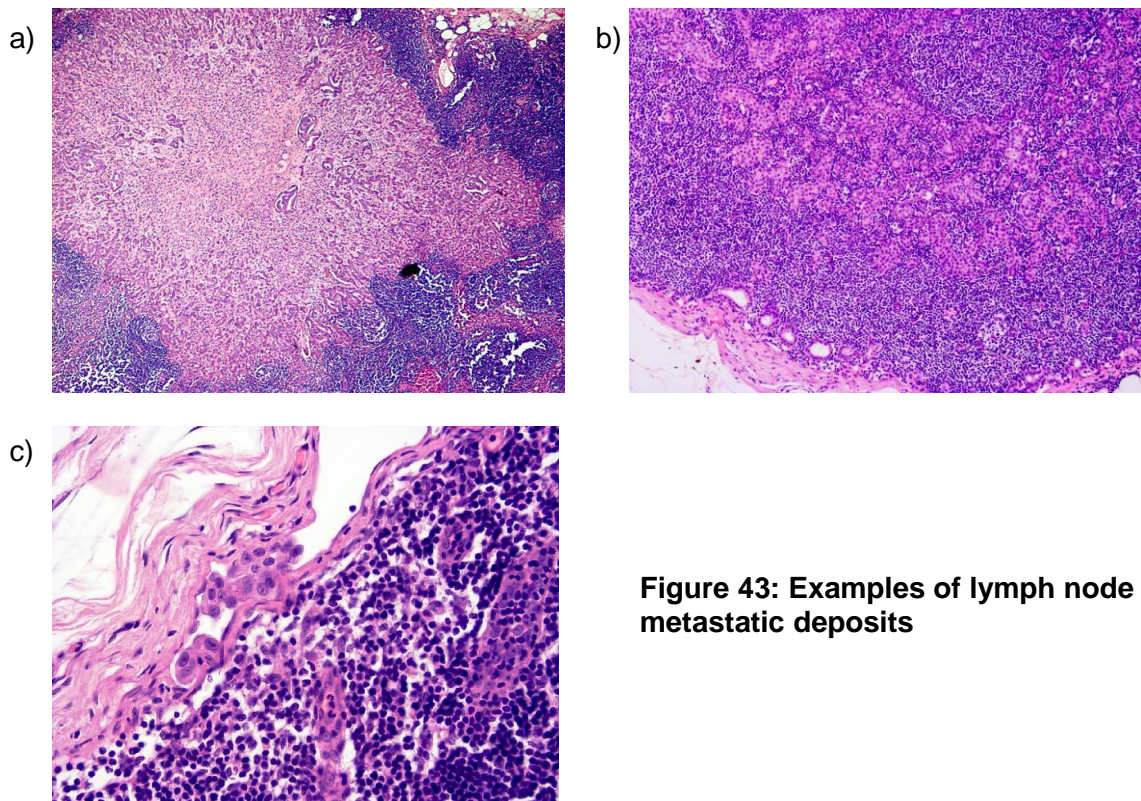


Figure 43: Examples of lymph node metastatic deposits

6.2.4.1 Reporting and definitions of micrometastatic disease and isolated tumour cell clusters (ITCS)

Although it is recognised that the evidence base for the stratification of lymph node stage is limited, adoption of the approach outlined below and described in Appendix F regarding the new TNM staging system is also encouraged as it offers a pragmatic solution to the issues of classification of small metastatic deposits. It is felt appropriate for the UK and the rest of Europe to adopt an international consensus classification system to support an improvement in an evidence accrual based on common definitions. Thus the system outlined in Appendix F is adapted from the TNM classification of malignant tumours.

- Micrometastasis is defined as one or more deposits of metastatic carcinoma within the lymph node or the node capsule that are more than 0.2 mm in size but none of which is larger than 2 mm in greatest dimension. Lymph nodes involved by micrometastases are regarded as positive.
- Cases with only isolated tumour cell clusters (ITCs) in regional lymph nodes are classified as node negative (pN0). ITCs are single tumour cells or small clusters of cells not more than 0.2 mm in greatest dimension (Figure 43c) or single tumour cells, or clusters of fewer than 200 cells in a single histological cross section. These may be detected by routine H&E, by immunohistochemistry or molecular methods but which may be verified on H&E stains. ITCs do not typically show evidence of metastatic activity (e.g. proliferation or stromal reaction).
- Of note there, rare cases may be difficult to categorise reproducible at the border between micrometastasis and ITCs^{64–66} and there is variation between the strict adherence to size criteria described in the AJCC classification of nodal disease and the recommendations of the European Working Group.⁶⁶ The latter, for example, recommend reporting a cluster of tumour cells as micrometastasis when present in the nodal parenchyma even if less than 0.2 mm in dimension whilst by the AJCC criteria this would be regarded as ITCs. This grey area remains controversial as there is no clear clinical evidence to support one technique over the other.
- It is therefore recommended that any lymph node involvement >0.2 mm but <2 mm in any of the three dimensions is categorised as a micrometastasis. The 0.2 mm size cut-off relates to the maximum diameter of the largest tumour cell cluster. There may be instances of nodal involvement with the largest cluster measuring <0.2 mm in diameter but containing >200 cells, and vice versa, i.e. clusters >0.2 mm in diameter with <200 cells. Size should be considered first, and the cell count applied only if the largest cluster is <0.2 mm.⁶⁶

If a patient has received neoadjuvant therapy even very small metastases may have prognostic significance and it is considered likely that micrometastases and ITCs in the setting of neoadjuvant therapy may represent larger metastases that show some response to neoadjuvant therapy. It is therefore advised that any residual tumour cells identified in a lymph node examined after neoadjuvant treatment should be considered as positive. Lymph nodes previously containing tumour often show fibrosis and scarring. In addition to reporting the number of nodes involved and the size of the largest metastasis, the number of nodes with or without viable tumour that show fibrosis should also be recorded (see section 7.6 and Figure 44f). Use of H&E levels and immunohistochemistry is not routinely necessary in assessment of lymph nodes but may prove helpful in problematic cases post neoadjuvant therapy when interpretation may be difficult (see Appendix G).

[Level of evidence – A. Invasive tumour stage is a recognised important prognostic factor which is used in treatment planning, for formal staging purposes (TNM) and as a quality target in the NHSBSP. Accurate assessment is expected.]

6.2.5 Excision margins

Assessment of adequacy of excision requires close correlation between the surgical excision procedure and pathological examination. In particular it is essential that the pathologist is made aware of the depth of tissue excised and whether the surgeon has excised all the tissue from the subcutaneous to the pectoral fascia. In quoting distances between invasive carcinoma or DCIS and resection margins, either all distances should be quoted, or those clearances less than a certain threshold may be quoted, with a note that all the remaining margins have attained that threshold. Since there remains controversy over what clearance constitutes an adequate clearance, it is impossible to specify here a threshold above which the exact clearance no longer needs to be quoted. Some units employ statements like 'all other margins are >5 mm away' or 'all other margins are >10 mm away', as a short cut around the need to specify all clearances, when the local team have decided that they do not need to consider margins with clearances above those thresholds, but the thresholds are arbitrary.

There remains some controversy regarding the minimum width of uninvolved tissue that defines 'complete' excision, although narrower margins are now more widely accepted as adequate than previously. For this reason it is recommended that the pathologist reports the measurement to the inked margins of DCIS and invasive carcinoma rather than quoting 'complete' excision in histology reports.

[Level of evidence – A. Invasive tumour excision status is a recognised important prognostic factor relating to risk of local recurrence and is used for treatment planning. Accurate assessment is expected.]

6.2.5.1 Invasive carcinoma

The excision margins of a well-circumscribed invasive carcinoma without a significant *in situ* component are usually relatively simple to assess. The distance from the tumour to the radial margins (medial, lateral, superior or inferior) and to the deep (posterior) and superficial (anterior, but not skin) margins (if surgically relevant, as described above in section 1) should be measured macroscopically. If the surgeon has orientated the specimen with clips or sutures then the margin assessed should be related to these. To some extent this depends on local issues, especially where the surgeon has not excised the complete depth of breast tissue from subcutaneous to pectoral fascia; in this case the deep (posterior) and superficial (anterior) margins may become more clinically important and should in this instance be adequately assessed.

The relevant margins should be painted with ink or inks, and blocks taken so that the macroscopic measurement can be confirmed microscopically. If only one ink colour is used, care should be taken to describe which block represents which resection margin. Where large blocks are used, or for impalpable disease where there is a high chance that one may need to re-sample the wet specimen, use of multiple ink colours is recommended to avoid confusion. The distance from the radial margins (unless the deep (posterior) margin is involved) should be given in the distance fields on the form.

The most problematic areas of excision margin assessment are related either to diffuse tumours that are not easily visible macroscopically, or to DCIS, whether alone or associated with invasive carcinoma. In the former situation it may not be easy to define the nearest, or suspect, excision margins and a number of blocks from the nearest area of firm fatty or fibrous tissue to the margin may need to be taken. Some units employ shaved margins or large blocks in this instance and these can be very helpful, although with the former it may not be possible to give an exact distance from the margin.

Carcinoma found in cavity shaves or specific margin re-excision specimens should be added to the dimension of the main tumour if they are deemed to be in continuity; otherwise it should be measured and stated as a separate focus, indicating multiple invasive foci. In either

instance, the distance from the carcinoma to the new external margin, i.e. the new clearance should be measured and reported. The final description of resection margin status should take into account all cavity shaves, provided that one can be confident of their position and orientation.

6.2.5.2 DCIS, and invasive carcinoma with an extensive *in situ* component

In the case of DCIS, or invasive tumours with an extensive *in situ* component, it is not possible to very accurately assess the distance of the *in situ* lesion from the excision margins by the standard method of a single block taken from the tumour to the nearest excision margins such as is used for circumscribed invasive tumours. This is because of the ramifying nature of the duct system within the breast, which may contain *in situ* disease. This can therefore potentially extend to any margin of the specimen, even at some distance from the main area of calcification. There are a number of methods of assessing this problem. Each breast service has its own protocol for the surgeon's marking of specimen, usually involving suture style and clips, and this needs to take into account marking of nipple resection margins. It is hoped that national standardisation of such marking may occur, and pathologists should consider arguing for standardisation of marking protocols, at least across their own cancer networks.

Undoubtedly large blocks, in conjunction with use of multiple ink colours and careful attention to the specimen radiograph, are the best for measurement of the distance of foci of *in situ* carcinoma from the margins. However, they can only assess margins two dimensionally and there is a possibility of unrecognised *in situ* tumour extending to the margin outside the plane of even large blocks. The previous edition of these guidelines recommended that "pathologists take blocks from macroscopically normal tissue between an excised tumour and margins in all three planes of section to allow comment on the extent of DCIS and its relationship to the margins" in cases of extensive *in situ* carcinoma. Similarly for pure DCIS, previous guidelines have stated that "the distance from the nearest excision margin should be recorded if the lesion is sufficiently delineated. If not make a comment under 'Comments/Additional information'. The presence of non-neoplastic breast parenchyma between the DCIS and the margin is usually associated with adequate excision." It now appears from the UK DCIS Trial and other studies of recurrent/residual disease post-conservation therapy that such simple rules may not be sufficient to ensure complete excision. Many units now take blocks of the major area of calcification, blocks from this area to the nearest inked margins and then take shaved margin specimens with particular reference to the nipple duct margin. For this reason the nipple duct margin's status regarding DCIS but also invasive carcinoma is now included in the cancer dataset. It is recommended that the surgeon marks this margin, particularly in cases of DCIS as, although it may be some distance from the main area of calcification, it is sometimes the only margin involved. The rationale for shaved margins, which are known to detect extra instances of compromised resection margins beyond those shown in perpendicular blocks, is shown in Figure 2. The specimen radiograph may also be a helpful adjunct in assessing surgical clearance, although it should be borne in mind that *in situ* disease may be more extensive than the calcification seen mammographically, particularly for low-grade disease.

See also macroscopic examination section, section 1.

6.2.6 Assessment of treatment effects including post neoadjuvant therapy

Some patients with high-grade, large, locally advanced or inflammatory breast cancers may receive chemotherapy prior to surgery. This permits an assessment of tumour responsiveness to the chemotherapy and may result in tumour down staging, i.e. a reduction in tumour size and/or nodal involvement.

6.2.6.1 Histological appearances (Figures 44a to 44f)

If there has been minimal response to the treatment, the protocol of histological examination is not significantly different to that of excised breast carcinomas from patients not receiving neoadjuvant chemotherapy. However, if there has been a good (or complete) pathological response to primary chemotherapy, identification of the site of disease can be difficult, not only macroscopically as noted above, but also microscopically. This is histologically typically seen as an area of fibrosis, sometimes oedematous or myxoid with a central nidus in which there is an absence of breast epithelial structures.⁶⁷ (Figures 44a, 44b and 44c) Sometimes islands or sheets of foamy macrophages may be prominent and other chronic inflammatory cells seen in aggregates. Haemosiderin deposition may be present (Figure 44b) and areas of necrosis seen, but the latter is unusual.

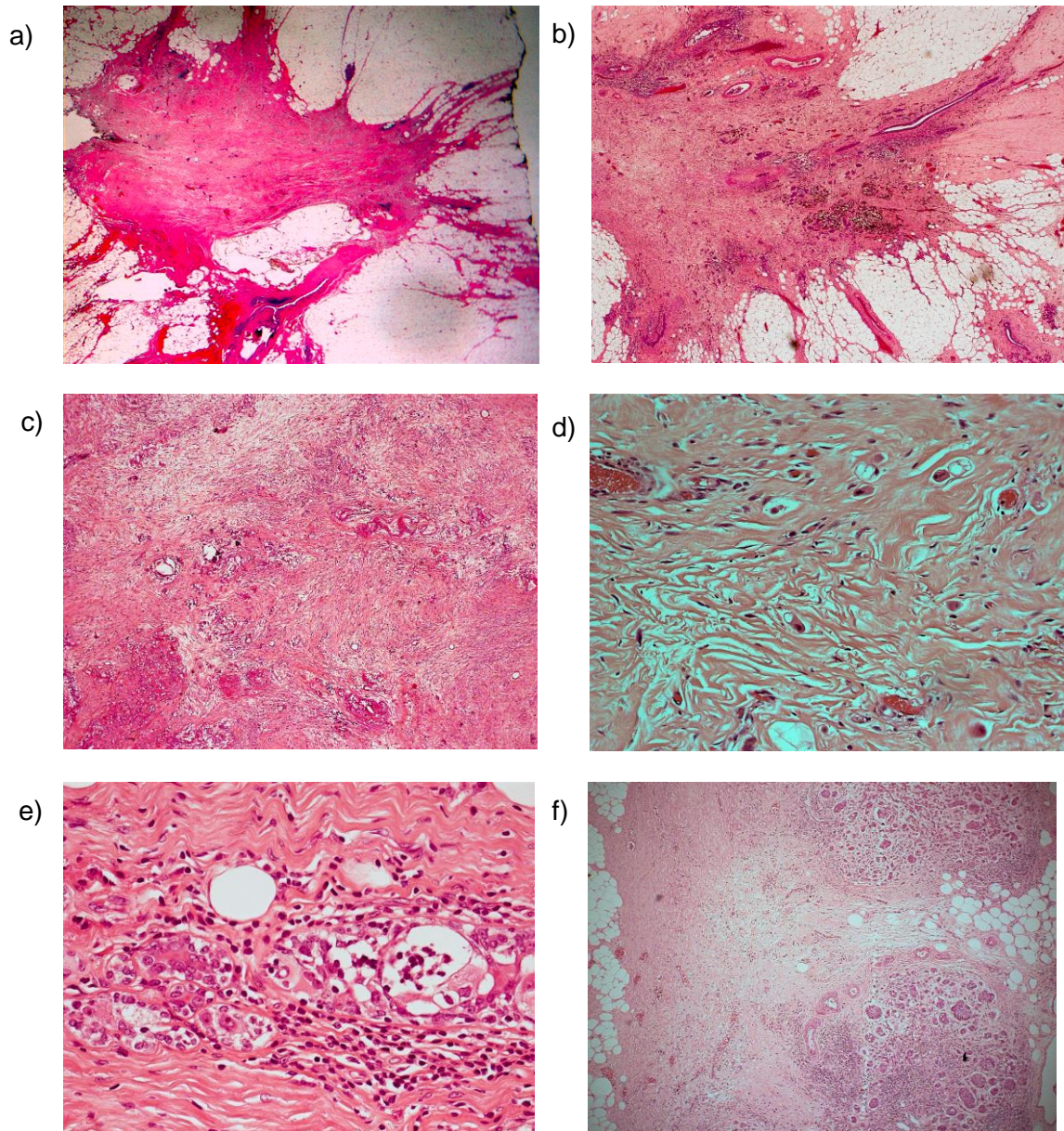


Figure 44: Examples of post-neoadjuvant chemotherapy changes (a, b, c, d) showing stellate fibrosis (a, b), dense fibrosis and elastosis with sparse tumour cells present (c). Tumour cells may be very sparse and difficult to identify (d). The normal epithelium may show reactive changes (e). Lymph nodes may show fibrosis (f) with or without residual tumour cells present

Residual carcinoma may be clearly evident with routine H&E stains and cause no diagnostic difficulties. However, some lesions, particularly if there has been a significant chemotherapy response, may also cause problems in microscopic assessment. Scattered residual invasive carcinoma may mimic macrophages, and vice versa, (Figure 44d) both in the breast tissue and in lymph nodes. Conversely invasive carcinoma cells may be larger, more pleomorphic and atypical after therapy. The architecture of the tumour may also appear to change and no special type lesions may mimic invasive lobular carcinomas after primary chemotherapy treatment.

Of note, even when no residual invasive component can be identified, residual *in situ* carcinoma, typically DCIS, may be seen and this does not preclude categorisation as complete pathological response. However, benign breast epithelium may show chemotherapy changes in the form of enlargement of nuclei with prominent nucleoli and care should be taken not to overdiagnose DCIS in this setting (Figure 44e).

Where no overt tumour is seen, but odd scattered cells with nuclear atypia or whose nature is otherwise uncertain, a low threshold for immunohistochemical evaluation is recommended to confirm the nature of the cell type and to reveal low volume residual disease. Carcinoma cells retain cytokeratin expression post-therapy, whilst macrophages will continue to express CD68. There is some evidence that AE1/AE3 may be preferable to other cytokeratin markers in the immunohistochemical examination of sentinel lymph nodes out with the setting of primary systemic therapy⁶ but reticulum and inflammatory cells (which may give positive reactivity with Cam5.2 and other pan-cytokeratin formulations) may be especially difficult to assess in a background of neoadjuvant chemotherapy changes. Immunohistochemistry may also assist the assessment of margin status in conservation surgery specimens.

6.2.6.2 Assessment of response to treatment

Pathological complete response (pCR) is currently recognised as the key prognostic measure with respect to subsequent patient outcome after neoadjuvant chemotherapy. The definition of pCR does, however, vary between centres. Some definitions focus on absence of any invasive component whilst others require complete effacement of all disease (DCIS, invasive and intravascular). It has recently been reported in large series that disease-free survival is significantly superior in patients with no invasive or *in situ* residual disease in either breast or lymph node nodes when compared with patients with residual DCIS only, those with no invasive residuals in breast but involved nodes, only focal residual invasive disease in the breast, and gross invasive residual disease.⁶⁸ However, the recent CTNeoBC pooled analysis of 12 major international neoadjuvant trials did not find a significant difference in event free survival or overall survival in patients with or without residual DCIS (Cortazar *et al.* 2014). These data suggest that pCR as defined as no invasive and no *in situ* residual disease in either breast or lymph nodes is the best discriminator of patients with a favourable outcome but this is not the globally applied definition, in which residual DCIS does not exclude definition as pCR.

Those patients with focal residual disease (i.e. partial response) fare better than those with gross invasive disease after neoadjuvant chemotherapy but there is no globally agreed method for categorisation of partial/lesser degrees of response to chemotherapy. Several systems have been described.^{69–72} Some systems categorise response based solely on changes in the breast carcinoma, others include assessment of primary tumour and lymph nodes. However, they show overall similarities and generally include an assessment of the cellularity of the tumour (sometimes in relation to cellularity in previous needle core biopsy), some also incorporate an evaluation of the residual extent/size of the lesion and metastasis.

The system described below⁶⁷ has the merit of simplicity and takes account of chemotherapy induced nodal change in addition to changes in the primary tumour:

Tumour response

- Complete pathological response, either (i) no residual carcinoma or (ii) no residual invasive tumour but DCIS present.
- Partial response to therapy, either (i) minimal residual disease/near total effect typically (e.g. <10% of tumour remaining in the tumour bed seen as an area of residual fibrosis delineating the original tumour extent) or (ii) 10–50% of tumour remaining or (iii) >50% of tumour remaining. Comparison with the previous core biopsy sample may be helpful.
- No evidence of response to therapy.

Nodal response

- No evidence of metastatic disease and no evidence of changes in the lymph nodes.
- Metastatic tumour not detected but evidence of response/‘down-staging’, e.g. fibrosis.
- Metastatic disease present but also evidence of response, such as nodal fibrosis (Figure 44f).
- Metastatic disease present with no evidence of response to therapy.

The determination of the Residual Cancer Burden includes an assessment of the tumour bed in two dimensions, the cellularity of the tumour (and the proportion that is DCIS) and the number and size of lymph node metastases. A combination of these gives the Residual Cancer Burden, which can be grouped according to patient outcome.⁷² The algorithm for this, as well as examples of percentage cellularity and methodology can be found on the MD Anderson website – residual cancer burden calculator. (www3.mdanderson.org/app/medcalc/index.cfm?pagename=jsconvert3)

This methodology for assessment of response to neoadjuvant chemotherapy is gaining in popularity with clinicians, is being used in several ongoing clinical trials, and is now routinely reported in some UK Units.

6.2.7.3 Reporting of prognostic and predictive factors after neoadjuvant therapy

Tumour size, histological grade, histological sub-type and lymph node stage, as well as predictive factors, such as ER, PR and HER2, can all be altered by primary chemotherapy. There is some evidence that grade and histological type remain of prognostic value, even when assessed post-treatment in such cases, but in general the pre-treatment core biopsy is recommended for assessment of these two features.

Residual invasive cancer size can be difficult to assess. If multiple scattered foci of invasive tumour remain, present advice is to measure the overall extent of all residual foci, unless clearly disparate islands of cancer can be identified and measured individually. Reference to whether the tumour was unifocal or multifocal on pre-treatment MRI or other imaging may also be helpful. An estimate of tumour volume relative to tumour bed size is useful to convey that, although overall tumour dimension may be large, the amount of actual residual tumour may be low.

Assessment of lymph nodes should take into account the number of nodes containing residual tumour, as well as the number of additional nodes showing fibrosis (often discrete and angulated/wedge-shaped) (Figure 44f) with other features of tumour regression such as other alterations of the nodal architecture or its constituents. There is evidence that patients with evidence of response of nodal metastases and regression of metastases have a better disease free survival than those with persistent metastases.⁷³ For this reason, the number of nodes with evidence of tumour regression should also be recorded, whenever possible. An estimate of pre-treatment nodal burden may also be used in decision making

regarding the need for adjuvant radiotherapy, and whether the supraclavicular nodal fields should be included.

There is conflicting data in the literature regarding changes in ER, PR and HER2 after neoadjuvant therapy, and because of this and the possibility of complete response, it is recommended that these biomarkers are assessed on the pre-treatment core biopsy.

TNM stage, post-chemotherapy should be prefaced with a 'y' code, see Appendix F.

7 Assessment of hormone receptors

7.1 Recommendations for steroid receptor testing

The steroid receptor (oestrogen receptor (ER) or both oestrogen and progesterone receptor (PR)) status of a breast cancer is used to determine whether or not a patient will benefit from endocrine therapy,⁷⁴ either as adjuvant therapy or for metastatic disease. Previously, assays depended on the homogenisation of fresh tumour tissue followed by ligand or antibody binding. Immunohistochemistry is now the method of choice for assessing steroid receptor status. It has the advantage that it can be used for both core biopsies and therapeutic excisions. However, any laboratory undertaking immunohistochemistry must ensure that staining methodology is properly validated and results are reproducible, allowing correct semiquantitative assessment. These guidelines have been formulated to give advice. Assessment of oestrogen receptor status is essential for all invasive carcinomas.⁷⁵ It is controversial whether progesterone receptor status has a role in addition to oestrogen receptor status, so assessment of progesterone receptor status is optional at present. Where clinically relevant, recurrent disease should also be assessed.

7.1.1 Case load

As semiquantitative predictive tests ER and PR require a greater degree of technical and interpretive accuracy than routine immunohistochemistry analyses which are purely diagnostic (positive or negative) and used as part of a panel. False positive and false negative results can lead to direct patient harm as a consequence of lack of benefit and unnecessary side effects from use of inappropriate treatment and denial of benefit from appropriate treatment, respectively. In April 2013, The Care Quality Commission (CQC) published a report into an NHS Trust following a detailed inspection to look into concerns about breast cancer hormone test results. The report incorporated specialist input including a review by The Royal College of Pathologists and the Institute of Biomedical Science of the Trust's Cellular Pathology services and quality assurance systems. In the report above a target level of 300 breast cancer ER assays per year for screening cases was identified. This number was recommended to ensure that the annual national clinical audit of screening cases undertaken by the Association of Breast Surgery or the National Pathology Audit will identify accurately any testing centres which are outliers in ER positivity rates and enable appropriate prompt action to be taken to ensure patient safety and protect patients.⁷⁶

This and other anticipated national audits enable comparison between laboratory services but are not designed to replace the requirement for internal quality control and adequate quality assurance. However, the submission of itemised pathology data as part of the Cancer Outcomes and Services Dataset (COSD) becomes mandatory for English NHS Trusts from 1 January 2016. It is therefore anticipated that national collection of ER/PR status will improve from this date as these are required COSD data items for breast cancers. This should enable more robust statistical analysis of variance in ER status.

A target level of minimum testing numbers was set to ensure continuing expertise of providers and robust monitoring and benchmarking of testing and interpretation. There is evidence of higher consistency of predictive testing quality when assays are performed by high volume

reference laboratories and so testing centres with lower numbers of cases requiring ER and/or PR immunohistochemistry (<300 per year) should consider using a reference laboratory service.

7.2 Principles

7.2.1 Fixation and buffering

Poor fixation will affect immunohistochemical staining, and it is therefore essential that fixation protocols are precisely followed. To obtain optimal fixation, it is recommended that specimens are received as soon as possible after surgery and sliced to allow rapid and even penetration of the fixative. Established fixatives include either or 10% neutral buffered formalin or 10% formal-saline. A minimum of 6 to 8 hours of fixation is required for core biopsies and 24 to 48 hours for excision specimens. There is evidence that prolonged fixation can result in reduced staining and should therefore be avoided.

Prolonged buffering has also been identified as a problem and some manufacturers do not recommend overnight runs for quantitative immunohistochemistry. If necessary, consideration should be given to extending the working day and/or weekend working in the laboratory to avoid prolonged fixation/buffering times.

7.2.2 Methods

- Heat mediated antigen retrieval methods using either a pressure cooker or microwave retrieval have now been surpassed by automated immunohistochemistry platforms that have 'on-board' retrieval technologies. Alternative 'off-board' retrieval methods include a PT module (optimised water bath method) and de-cloaking chamber (digital pressure cooker), which have both been shown to produce reproducible results. Irrespective of the method used the duration of antigen retrieval is critical; too short a heating time can be a major cause of false negative ER staining⁷⁷⁻⁷⁸ and extended antigen retrieval has been shown to be a cause of false positive reactivity.⁷⁹
- Well characterised antibodies against oestrogen receptor and progesterone receptor that have been validated against clinical outcome or against other methodologies for detecting steroid receptors, e.g. ligand binding assays, should be used. Updated recommendations of suitable clones can be found on the UK NEQAS website (www.ukneqasiccish.org) and journal.
- A sensitive detection method should be employed. Polymer based detection systems appear to be the method of choice and provide more sensitive results with cleaner staining results.
- If changes are made either to the duration of antigen retrieval or to the detection system, as new reagents become available, it is important that all antibody titres are optimised to ensure clear nuclear staining with no cytoplasmic or background reactivity.
- Nuclear counterstaining should not obscure weak positive staining.

7.2.3 Controls

These are particularly important and must be used for each staining run. A composite block containing receptor rich, receptor poor and negative tissues or cell lines should be used, ideally on the same test slide and of material which is similarly fixed and processed to the test tissue. Control sections should be ideally cut at the same time as the test material. Long-term storage of pre-cut control sections is strongly discouraged. Tissues to be tested should have normal breast tissue present wherever possible as well as cancer; this acts as a good internal positive control and is particularly important if fixation is suboptimal. Negative controls should always be included. If there are any problems with the standard control or with the staining of internal normal tissue, staining should be repeated. The type and grade of the

carcinoma should also be taken into account because better differentiated carcinomas are unlikely to be negative.

7.3 Scoring

There are several different scoring systems and there is no internationally accepted scoring method. Current consensus (ASCO/CAP and Mitch Dowsett, personal communication) is that the recommended cut-off point for positivity versus negativity for ER status is greater than or equal to 1% of tumour cells.^{75,80} Only nuclear staining is considered, and all of the invasive component should be assessed. Such quantitative scoring of ER positivity is recognised to be clinically relevant for predicting response to endocrine therapy and for this reason is mandated as a dataset requirement.

The most widely used methods are based on a combination of intensity and estimation of % staining and are detailed in Table 7.

Table 7: The Allred/Quick score and H score methods for hormone receptor IHC semi-quantitative scoring

Allred score (0–8 Quick score)⁸¹

Score for proportion	Score for intensity
0 = no staining	0 = no staining
1 = < 1% nuclei staining	1 = weak staining
2 = 1–10% nuclei staining	2 = moderate staining
3 = 11–33% nuclei staining	3 = strong staining
4 = 34–66% nuclei staining	
5 = 67–100% nuclei staining	

The scores are summed to give a maximum of 8.

The cut off for positivity using Allred score ≥ 3 .⁸²

Use of the Allred assessment method can, in a small proportion of cases, conflict with the 1% cut point for positivity/negativity recommended above. All cases showing >1% of tumours cells positive should be classified as receptor positive regardless of their Allred score. All cases showing <1% of tumours cells positive should be classified as receptor negative regardless of their Allred score.

H score⁸³

The percentage of weakly stained nuclei is multiplied by 1, the percentage of moderately stained nuclei is multiplied by 2, and the percentage of strongly stained nuclei is multiplied by 3; the total of these three is the H score, with a range of 0–300.

Using modern immunohistochemical methods the distribution of oestrogen receptor score in breast cancer is bimodal. Most carcinomas are either completely negative or convincingly positive with only a few per cent weakly positive. The cut-off between positive and negative is between the completely negative and convincingly positive groups, but accurately defining a precise cut-off is difficult as there are so few weakly positive tumours. Also, different cut-offs may be used in different clinical situations - the cut-off for primary endocrine treatment may be higher than the cut-off for adjuvant treatment. The distribution of progesterone receptor score in breast cancer is also bimodal, but the proportion of weakly positive tumours is higher. It is important to have a sensitive technique so that weakly positive carcinomas are identified.

7.4 Core biopsy

A number of studies have shown that oestrogen receptor can be reliably assessed on core biopsy.^{84,85} The agreement between core biopsy and surgical specimen is less for progesterone receptor.⁸⁵

Repeat on the surgical excision specimen should be considered if the core biopsy:

- is ER negative with no internal control cells present
- scanty tumour cells only are seen and the lesion has not been adequately sampled in the core biopsy
- low level atypical granular positive nuclear staining is present
- if the carcinoma is morphologically heterogeneous
- if there poor tumour cell cytomorphology or cell damage, such as crushing artefact.

7.5 Multiple tumours

Histologically distinct carcinomas or widely separated carcinomas considered to be separate synchronous primary tumours should each be assessed. It is reasonable not to assess multiple tumours if they are histologically similar and close to each other.

7.6 Ductal carcinoma *in situ*

Oestrogen receptor status may be assessed in patients with ductal carcinoma *in situ* for whom endocrine treatment is being considered, but it is not mandatory for all patients. There is no consensus on cut-offs as, unlike for invasive carcinoma, there are no data, relating clinical outcome on endocrine treatment to the level of oestrogen receptor expression. At the present time it is recommended that the same scoring method and cut point for positivity used for invasive carcinoma be used for assessment of DCIS. Hormone receptor status should be recorded on the NHSBSP and dataset forms as positive or negative with the percentage staining as a minimum and the average intensity or the result of the Allred score or H score as for invasive disease.

7.7 Audit and benchmarking

Regular and ongoing audit should be undertaken. Laboratories should audit their overall positive rate for ER. It is important to ensure that the sample size is adequate. The current average positivity rate in the UK from the UK NEQAS ICC and ISH breast biomarker audit of over 40 000 cancers, is 82.6% for ER, with 83.7% of primary tumours being ER positive and 69.7% of metastatic lesions. For PR status, based on over 30 000 cancers, the overall rate is 67.4% (68.4% for primary and 44.6% for metastatic cancers).

Table 8 shows the combined breast ER/PR receptor rate (UK NEQAS audit data from 2009 to 2012).

Table 8 The current average positivity rate in the UK from the UK NEQAS ICC and ISH breast biomarker audit

	ER+/PR+ (%)	ER-/PR- (%)	ER+/PR- (%)	ER-/PR+ (%)
Primary	67.5	17.3	13.9	1.3
Metastatic	43.2	29.6	25.5	1.6
Overall (n=31,361)	66.4	17.6	14.5	1.5

It should be noted that the overall ER and PR positivity rates will vary, depending on whether the tumour is primary or metastatic and whether the patient presented with symptomatic disease or the breast cancer was identified through the breast screening programme. Audits and benchmarking should take these factors into account.

7.8 Quality assurance for oestrogen receptor evaluation

All UK clinical laboratories utilising immunohistochemical assays for oestrogen receptors (ER) and progesterone receptors (PR) as predictive or prognostic markers must participate in an appropriate external quality assurance (EQA) programme, such as that run by the UK National External Quality Assessment Scheme for Immunocytochemistry and *in situ* hybridisation (UK NEQAS ICC and ISH).

7.8.1 Distribution of EQA material

UK NEQAS ICC and ISH have over 300 participants for their breast hormonal receptor assessment module, of which 167 are from the UK. Currently, the assessments take place on a quarterly basis, with unstained formalin fixed and paraffin processed tissue sections from a composite block generally comprising of three invasive breast carcinomas sections which have previously been characterised for ER and PR receptor expression.

Participating laboratories are requested to stain the UK NEQAS ICC and ISH section using their everyday clinical methodology. As well as the UK NEQAS ICC and ISH slide, participants are also requested to submit their own in-house control material for assessment. It is strongly encouraged that in-house control material should comprise three breast carcinomas showing the following level of expression (i) >80% tumour positivity with high intensity (Allred/Quick score 7–8) (ii) 30–70% tumour positivity with low-moderate intensity (Allred/Quick score 4–6) and (iii) a negative tumour, with positively stained normal glands (Allred/Quick score 0). Participants are also requested to complete a web-based methodology form, including such information as antibody clone and dilution, heat mediated antigen retrieval method, automation staining instrument, etc.

7.8.2 Assessment procedure

Participants then return their stained slides to the organising centre, for evaluation by a panel of four expert assessors. Each of the four assessors awards marks out of 5, which are then totalled to give a score out of 20 (Table 9).

An acceptable score (>12/20) is given when the expected proportion of invasive tumour nuclei for all test sections is clearly stained with the expected staining intensity. A borderline score of 10–12/20 generally indicates that although the sample is clinically readable, the staining pattern is less than the expected proportion of invasive nuclei. Finally, a score of <10/20 is given when for example when a known positive tumour is stained as negative (false negative staining)⁷⁸ or when a known negative tumours is stained as positive (false positive staining).⁷⁹

Table 9: UK NEQAS assessment method

Score	General guideline used in the assessment of slides
0	Slide not returned by participant.
1 or 2	Staining of considerably fewer nuclei than expected in one or more of distributed tissue sections, and/or false positive/negative staining.
3	Staining of 10% or greater of tumour nuclei in each of the positive tumour sections, though substantially less than expected to stain, or staining is weaker than expected.
4 or 5	Demonstration of the proportion of nuclei of invasive tumours, expected to stain, with roughly the expected staining intensity.
<p>Marks are also deducted when correct clinical interpretation of staining may be hindered due to factors such as:</p> <ul style="list-style-type: none"> • non-specific or inappropriate staining • excessive cytoplasmic or diffuse nuclear staining • excessively strong or weak haematoxylin counterstain • excessive antigen retrieval resulting in morphological damage • poor quality/inadequate choice of in-house control tissue (poor/inadequate fixation, damaged cell morphology, over retrieval, etc). 	

7.8.3 Poor performance monitoring

The UK NEQAS ICC and ISH also have a duty to monitor the performance of all UK clinical laboratories performing breast hormonal receptor staining. Because of the direct impact that the results of assays for hormonal receptors have on patient management, more stringent performance monitoring mechanisms are employed than for other assays. Furthermore, as of September 2010 the National Quality Advisory Panel (NQAAP) has made it mandatory for EQA schemes to use a 'traffic light' system for the grading of all its UK participants. The table below highlights the traffic light system used in the breast hormonal receptor module. The poor performance criteria are applicable only to the UK NEQAS ICC and ISH distributed tissue and monitoring covers the 5 most recent assessment periods. Although in-house sections are not part of the poor performance monitoring system, in-house material scores may also be used to gauge overall performance status.

Status	When triggered	Monitoring procedure
Green	1 underperformance (scores <10/20) over 5 runs on NEQAS ICC slides	Participant will be offered assistance to improve
Amber	2 underperformances (scores <10/20) over 5 runs on NEQAS ICC slides	Participant and Head of Department will be notified of continued underperformance and will be sent a 'Warning letter' indicating that they are close to being deemed a poor performer and to contact the scheme Director. The scheme Director will then provide advice and assistance on how the laboratory concerned might improve their results
Red	3 underperformances (scores <10/20) over 5 runs on NEQAS ICC slides	Participant and Head of Department will be notified that they have been deemed a 'poor performer' and to contact the scheme Director to discuss the situation. The scheme is also obliged to refer the laboratory to NQAAP

8 Assessment of human epidermal growth factor receptor 2 (HER2)

8.1 Introduction

Overexpression of the human epidermal growth factor receptor 2 (HER2) protein, mainly due to HER2 gene amplification, in breast cancer is associated with aggressive histological features and poor prognosis.^{86,87} Several randomised clinical trials have demonstrated substantial survival benefits in patients with HER2 positive breast cancer treated with anti-HER2 targeted therapy, such as trastuzumab^{88–90} and the tyrosine kinase inhibitor lapatinib^{91–93} but not in HER2-negative patients.⁹⁴ This, in addition to potential side-effects of these costly drugs and evidence of higher response rates to neoadjuvant chemotherapy in HER2 positive tumour patients⁹⁵, has emphasised the need for accurate assessment of HER2 status in all invasive breast cancer patients. Early studies, with relatively small numbers of cases, suggested that as many as 30% of breast cancers had HER2 overexpression, with a false positive rate up to 19% and a false negative rate of 5–10%.^{96–98} However, following publication of guideline recommendations^{96,99–103} and refinement of test performance parameters including the standardisation of tissue handling, assay methodology and adopting high quality assurance measures, recent data indicate that the frequency of HER2 positivity is between 13–20%.^{96,97,104–106} The false positive rate is reduced to less than 6%, the false negative rate is much lower (<2%) and, importantly, the proportion of inconclusive cases is significantly reduced.^{96,96,104,105} To ensure the highest degree of test accuracy, reproducibility and precision, there is a need to further standardise and improve the quality of technical aspects such as assay performance, validation, proficiency testing and accreditation. These guidelines aim to update the previous UK guidelines,^{99,100,101} and provide recommendations on the pre- and post-analytical assay performance parameters and give advice on methodology and quality assurance measures for HER2 testing.

8.2 Pre-analytical measures

8.2.1 Specimens

HER2 status should be assessed in all invasive primary breast carcinomas and in recurrent and metastatic tumours whenever biopsy tissue is available. Bilateral carcinomas, histologically distinct ipsilateral carcinomas or widely separated carcinomas considered to be separate synchronous primary tumours should each be assessed. It is deemed reasonable not to assess multiple ipsilateral tumours if they are histologically similar and co-located in the same quadrant/region of the breast. There is no consensus on testing residual invasive tumour following neoadjuvant therapy, although some recommend this approach. Retesting non-responding stable or progressive HER2-negative tumours particularly high-grade tumours or those with a long-time period between preoperative biopsy and excision may be considered if considered clinically relevant, but cannot be recommended routinely in view of the lack of evidence.

Excellent concordance between core biopsy and surgical specimens has been shown using immunohistochemistry (IHC) and *in situ* hybridisation (ISH).^{105,107,108} In the majority of UK centres, HER2 testing is performed on the diagnostic needle core biopsy specimens but performing/repeating the assay on an incisional, or excisional surgical specimens should be considered if:

- i) the core biopsy is not available (i.e. there is only a cytology sample); or
- ii) there is a possibility that the HER2 test on the core biopsy is unreliable, or unrepresentative of the tumour identified in the resection specimen as follows:
 - 1) HER2 assessment is uninterpretable on the core due to technical artefacts (i.e. suboptimal processing or staining) or there is doubt about the core biopsy handling.
 - 2) The core biopsy HER2 status remains in the equivocal category after IHC and ISH; for example, repeat assessment is advised if the core biopsy was scored as 2+ on HER2 IHC with borderline negative ISH (ratio of number of HER2 to chromosome 17 centromere copies of 1.8 to 1.99 or HER2 gene copy number is 4–6).
 - 3) Invasive tumour on the core is too small for reliable assessment, or if invasive disease is intimately admixed with *in situ* carcinoma, or only identified in the excision specimen. There is insufficient data to define the amount of invasive tumour tissue in core biopsy sufficient for analysis; however this can be left to the reporting pathologist's discretion.
 - 4) If the tumour in the resection specimens is morphologically distinct from that in the core biopsy, for example of a clearly different histological type or histological grade (e.g. low grade on the core and high grade on the excision, but not just reflecting minor difference in the mitotic count or proportion of solid areas).¹⁰⁹ A repeat may also be undertaken on concurrent metastatic nodal disease if it is morphologically distinct from the primary breast tumour.
 - 5) If the core biopsy staining is heterogeneous and shows a focus of strong HER2 positivity in <10% of the area of the invasive carcinoma in the core biopsy, HER2 testing should be repeated on the excision specimen. If this pattern is detected on the excision specimen, a different tumour block or a nodal metastasis can be tested, to determine the percentage of positive/amplified tumour present in a larger tumour sample.

Fine needle aspirates from primary breast carcinoma are not suitable for assessment of HER2 status as the distinction between invasive and *in situ* disease cannot be made on such samples. However, if FNA is the only material available, or in metastatic disease, some evidence indicates that ISH is reliable for assessing HER2 status in liquid-based and cell block preparations.¹¹⁰ In the case of metastatic bone lesions that require HER2 assessment,

it should be noted that decalcification techniques have the potential to influence immunohistochemical assessment in a detrimental manner and such decalcified samples should be tested with ISH methods.^{111,112}

8.2.2 Fixation and processing

Good fixation of specimens used for HER2 testing should be ensured and the cold ischaemic time (time from removal from the patient to placing in fixative (cold ischaemic time)) should be as short as possible, certainly less than 1 hour. Formalin fixed, paraffin embedded tumour tissue samples are appropriate for assay. Tumours samples should be fixed in buffered formalin and embedded in paraffin wax; fixatives containing alcohol can result in staining of normal tissue and use of Bouin's fixative will preclude testing by fluorescence *in situ* based methods. Other methods of tissue fixation can also adversely affect antigen reactivity. At least 6 hours fixation is recommended for core biopsies. Surgical specimens should be incised as soon as possible through the carcinoma to allow initial penetration of fixative and then sliced into 5–10 mm slices to ensure rapid penetration and even fixation. Tissue should be placed in an adequate volume (ideally 10:1; fixative:tissue) of fixative for at least 24 hours and not more than 72 hours. Centres using rapid fixation and processing must validate their methodology for HER2 assessment.

Sections should be stained within 1–2 days of cutting and drying. Excessive section drying time has also been shown to cause a loss of HER2 expression and it is therefore recommended that freshly cut sections are either dried at 60°C for 1 hour or 37°C overnight (www.ukneqasiccish.org).¹¹³

8.3 Algorithms for HER2 testing

8.3.1 Principles

Immunohistochemistry (IHC) for detection of protein overexpression and ISH for detection of gene amplification status are the techniques recommended for determining HER2 status. High concordance between IHC and gene amplification status is reported.^{101,114,115} The current UK recommendations for HER2 testing are for a two-tier system using IHC with reflex ISH testing if required, using the model shown in Figure 1, or a one-tier ISH strategy. In general testing is performed using IHC with analysis of equivocal cases by ISH, but this does not preclude laboratories, from using primary HER2 ISH testing particularly if the quality of tissue fixation is questionable.¹¹⁶ ISH has usually been conducted using a fluorescence ISH (FISH) technique. Bright-field ISH, which can be used to assess HER2 status with a regular light microscope, is now accepted as an alternative to FISH.¹¹⁷ The most common bright field ISH uses a DNA probe coupled to a chromogenic (CISH) or silver (SISH) detection system, or a combination of both. ISH can be conducted using a single probe to enumerate HER2 copies per nucleus or as a dual-probe technique which allows determination of the HER2:CEP17 ratio and HER2 gene copy number. For this reason the inclusion of a chromosome 17 probe is strongly advocated. Currently, other available HER2 testing techniques (polymerase chain reaction, enzyme-linked immunosorbent assay, Southern blotting, mRNA assays and DNA microarray) should be used for research only. Similarly, HER2 results obtained from a non-ISH technique as part of a prognostic panel cannot be regarded as diagnostic and should not replace standard assay methods detailed above.

8.3.2 Scoring immunohistochemistry

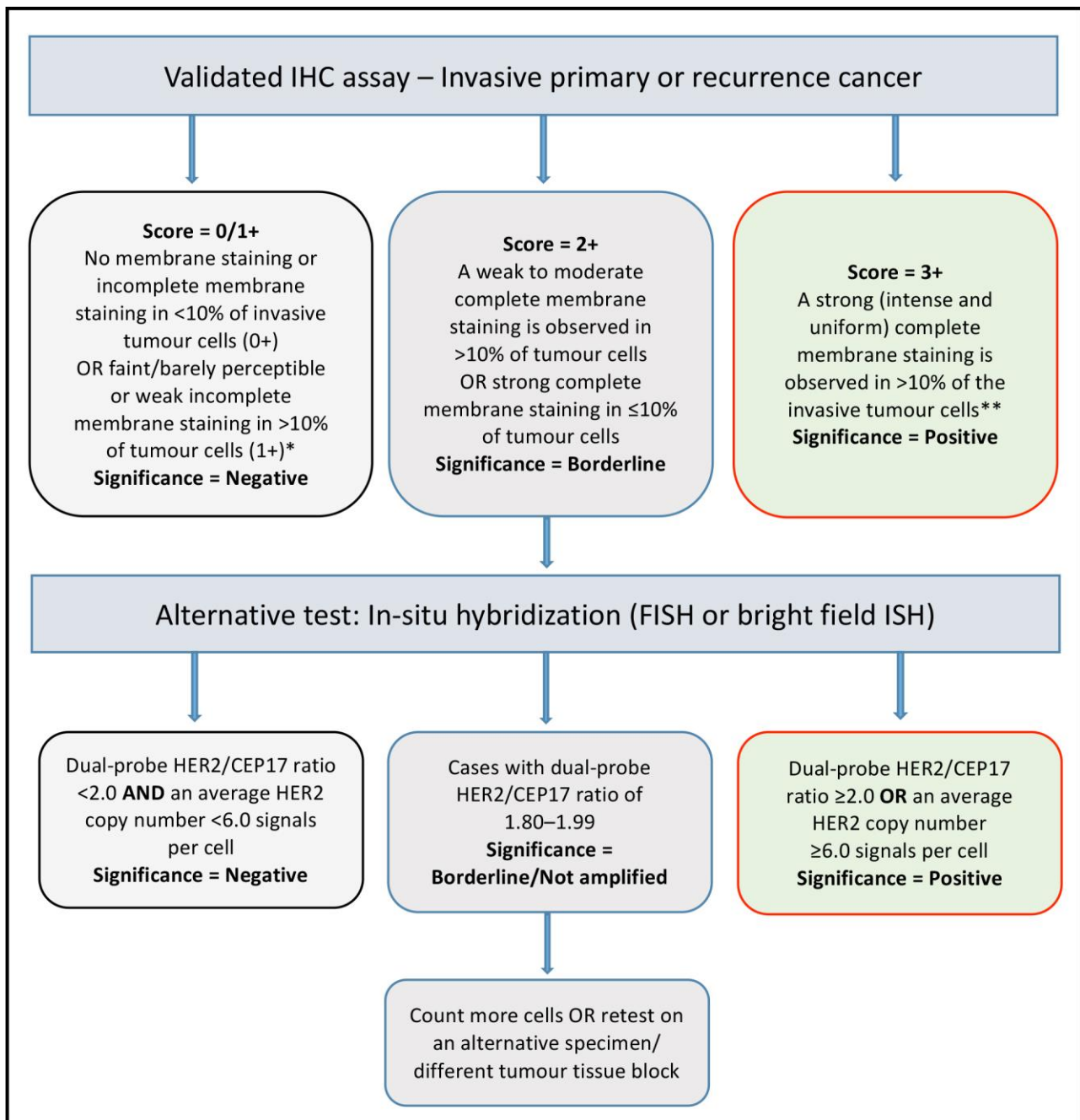
Only membrane staining of the invasive tumour should be considered when scoring HER2. Cytoplasmic staining and staining of *in situ* disease should not be scored, and normal epithelium should be negative. The HER2 IHC scoring method is a semi-quantitative system based on the intensity of reaction product and percentage of membrane positive cells, giving a score range of 0 to 3+ (Figure 45). Samples scoring 3+ are regarded as unequivocally positive, and those scoring 0/1+ as negative. Borderline scores (2+) are regarded as

equivocal and mandate further assessment using ISH (Figure 45). The HER2 test should be reported as indeterminate, and repeated where possible, if technical issues prevent one or both tests (IHC and ISH) from being reported as positive, negative, or equivocal. Examples include, inadequate specimen handling, artefacts (e.g. crush or marked edge artefacts) that make interpretation difficult, analytic testing failure or if controls are not as expected (i.e. sample shows strong membrane staining of normal breast tissue). In such a case, an alternative test, or another specimen if available, should be used to determine HER2 status.

8.3.3 Scoring *in situ* hybridisation

HER2 ISH testing, which use a dual probe method, are initially expressed as the ratio of HER2 signal to chromosome 17 (Ch 17) centromeric enumeration probe (CEP) signal. Subsequently the average HER2 gene copy number reporting has been used in some countries both when using dual probe and single HER2 gene probe methodology. The UK recommendation is to use dual probe ISH and report both the HER2/Ch 17 signal ratio and HER2 copy number. Tumours showing a ratio greater than or equal to 2.0 and/or a mean HER2 gene copy number ≥ 6 are considered to be positive. Assigning cases as positive based on a HER2 gene copy number ≥ 6 where the HER2/Ch 17 ratio is < 2 remains controversial but is recommended as its inclusion aligns with national guidance in other countries.⁹⁶ Cases with dual-probe HER2/CEP17 ratio < 2.0 with an average HER2 copy number < 6.0 signals/cell are considered as HER2 negative (Figure 45). In practice it is recommended that if a HER2/CEP17 borderline negative ratio result (i.e. between 1.8 and 1.99) is obtained from a needle core biopsy sample, repeat assessment on the surgical excision specimen is performed. There is a lack of published evidence base to support further testing for cases exhibiting mean HER2 copies/cell between 4 and 6 with a HER2/CEP17 ratio below 1.8 and it is recommended that such rare cases be reported as HER2 negative. Classification of cases with monosomy of Ch 17 and a HER2/CEP17 ratio > 2.0 remains controversial with uncertain anti-HER2 treatment benefit;^{118,119} current consensus⁹⁶ is to regard such cases as amplified.

A selection of normal cells should be assessed to confirm successful hybridisation, detection and visualisation, before assessment of the invasive carcinoma. The number of chromosome 17 and HER2 signals is scored and recorded and the mean HER2 to chromosome 17 copy ratio is calculated for 20–60 cells, where possible using at least three distinct tumour fields. In most cases, where either clear amplification is observed or the ratio is below 1.5, scoring of 20 tumour cells is sufficient. Only cells in which the nuclear borders can be identified should be counted. Over-digested, damaged and truncated nuclei should not be scored. Only cells with a minimum one copy of HER2 and CEP 17 should be scored. The location of the areas assessed should be recorded. In cases where either tumour heterogeneity is seen, or if the ratio is close to 2.0 or if the average copy number is between ≥ 4.0 and < 6.0 signals/cell, more cells should be scored (at least 60), for details see below. Samples with > 2.0 copies of HER2 for each chromosome 17 in the fields assessed are considered to be amplified. The HER2 ISH test should be reported as indeterminate and a repeat/alternative test (on the same or another specimen) is requested in the following situations: Controls are not as expected, nuclear resolution is poor, if a significant proportion of signals are unscorable due to weak signals or $> 10\%$ of signals occur over cytoplasm, autofluorescence is strong or the observer cannot find and count at least two areas of invasive tumour.



* Insufficient data is available to comment on moderate complete membrane staining in $\leq 10\%$ of tumour cells or strong incomplete membrane staining in $>10\%$ of tumour cells. A repeat on another specimen/tissue block is advisable.

** Membrane staining must be intense and uniform and resemble chicken-wire. Ignore incomplete or pale membrane staining in the percentage estimation.

Figure 45: Recommended HER2 scoring algorithm for immunohistochemistry (IHC) and *in-situ* hybridisation (ISH)

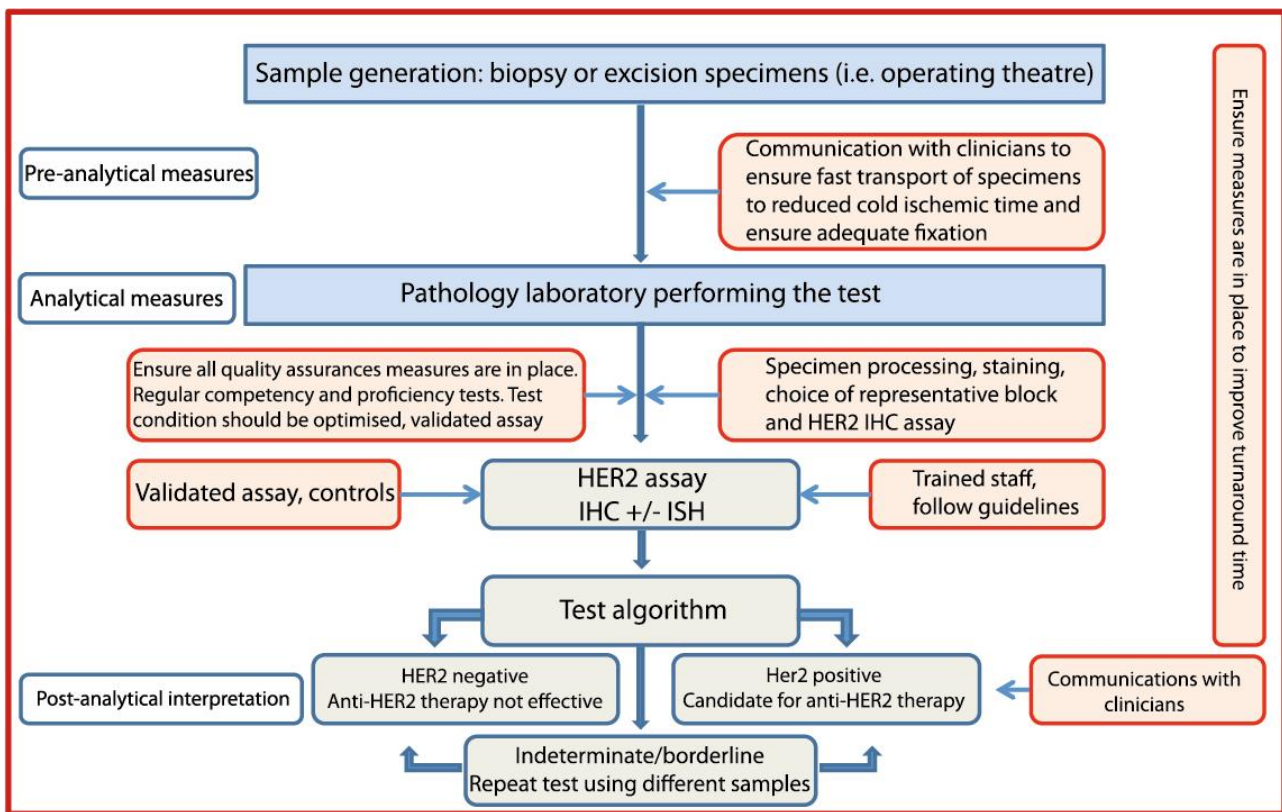


Figure 46: Pathway for HER2 testing

8.3.4 Heterogeneity

Genomic heterogeneity refers to the coexistence of more than one population of tumour cells with distinct HER2 amplification characteristics within the same tumour. Intratumoral heterogeneity can be seen as a clustered form where distinct populations/clones of amplified and non-amplified tumour cells coexist, or as a mosaic form which includes the presence of isolated amplified cells in a predominantly non-amplified tumour or a diffuse mixture of amplified and non-amplified cells across the tumour.^{96,120} While such heterogeneity is generally uncommon in breast cancer, the following approach has been proposed to manage heterogeneous HER2 gene amplification in breast cancer and is recommended in these guidelines.¹²¹

In all cases where ISH is performed the entire slide should be scanned before counting, areas of apparent heterogeneity should be identified during this scan and/or by reference to an IHC stained slide. The number of chromosome 17 (CEP17) and HER2 signals should be counted in 20–60 non-overlapping invasive cancer cell nuclei, using at least three distinct tumour fields. If there is evidence of heterogeneity between fields (or less frequently within fields) additional cells (at least 20 per field) and/or fields (up to 6) should be counted. The HER2/CEP17 ratio should be calculated for each field individually. Where the mean HER2/CEP17 ratio in any field is 2.00 or greater, the tumour should be regarded as amplified. For all cases where the ratio is between 1.80 and 2.20 results should be based on counting at least 60 tumour cells, and in cases where heterogeneity is suspected this should be 60 cells per assessed field. In rare cases where amplified and non-amplified tumour cells are intermingled in a single field, interpretation is difficult and evidence is lacking. We suggest that for such cases only the presence of clearly amplified cells, with multiple HER2 signals, is considered evidence of heterogeneity, again evidence is lacking in this area. Current evidence does not support using the existence of small numbers of apparently amplified cells within an individual tumour field to identify heterogeneous amplification. In borderline cases, i.e. those with a HER2/CEP17 ratio of 1.80–2.20, additional cells should be counted when possible (optimally a minimum of 60 per case), ideally this should include

a dual count (from a second observer; either internally or in a second centre). The optimal approach to improving accuracy in this range is to increase the number of cells counted to 60–120, and/or repeat the test. A ratio of 1.80–1.99, after counting further cells and/or repeating the test, should be reported as borderline but not amplified and include a clear statement that the carcinoma is regarded as HER2 negative (taking the mean HER2 copy number into consideration [mean <6 copies/cell]). In practice if a HER2/CEP17 borderline negative ratio result between (i.e. 1.80 and 1.99) is obtained from a needle core biopsy sample, repeat assessment on the surgical excision specimen should be performed. Tumours with a mean HER2 copies/cell score of between 4 and 6 with a HER2/CEP17 ratio below 1.8 should be reported as negative (see above). A ratio of ≥ 2.00 should be reported as amplified, and regarded as HER2 positive. Data on the response of patients to trastuzumab whose cancers fall within the borderline amplified category are not available; a statement to this effect can be included in reports. While these guidelines are sufficient for the majority of cases, there are occasions when difficult cases should be referred to expert centres for guidance.

Variation increases with highly amplified samples, and is not critical where the ratio of HER2/CEP17 exceeds 4. Where possible, count all signals, but if this is not possible, for example if clusters are present, then try to estimate the number of signals. Count doublets as a single signal. Where resources permit, representative images can be captured and archived. Difficult cases should be assessed by a second observer. A minimum of 10% of cases should be double-reported to ensure consistency between observers.

The ISH report should include: the number of cells scored, the average HER2 and CEP17 copy number and the HER2/CEP17 ratio. Unusual features should be noted. For heterogeneous cases all these details should be reported for each subclone. If there is a problem in specimen handling and/or processing (i.e. non-adherence to the guidelines), this should be documented in the report.

8.3.5 Impact of heterogeneity of IHC and ISH

Although a cut-off of >10% of the invasive tumour area using IHC is used to define positivity, cases showing complete intense membrane staining in <10% of tumour cells are seen, albeit rarely, and should be considered in the borderline category. In such cases, a repeat of the HER2 IHC test on another specimen (e.g. a different tumour block) should be undertaken, to determine the percentage of positive tumour present. If this repeat IHC assessment shows a similar pattern, ISH should be performed. Variation in immunostaining between the periphery and centre of tumours can be due to a fixation gradient.

Defining HER2 positivity using ISH may be complex in cases with intratumoural heterogeneity (see above for scoring methodology). Such genetic heterogeneity affects a proportion of breast cancer (11–40%¹²⁰) and is more frequently seen in HER2 positive tumours. Although no clinical data is available to guide on the likely response of genetically heterogeneous tumours harbouring HER2-amplified subclones to trastuzumab, it would be valuable to standardise the definition of genetic heterogeneity to facilitate future study of its clinical relevance.¹²⁰

8.3.6 Evaluation

For assessment of both HER2 IHC and ISH preparations, training and experience in interpretation of histological characteristics of breast tissue is essential. Recognition of different histological tumour types is required. In particular, HER2 status should only be determined on the invasive portion of the tumour, and neither IHC nor ISH should be reported in isolation. If it is difficult to differentiate invasive from *in situ* disease in the index tumour block submitted for ISH, IHC markers for myoepithelial cells can be used.

Image analysis systems may provide alternatives to manual scoring for both HER2 IHC and ISH. However, at present, insufficient evidence is available to recommend their routine use in the diagnostic setting.

8.4 Good practice and quality assurance measures

8.4.1 Appropriate laboratory methods

For both IHC and ISH based HER2 testing, comprehensive standardisation of methodology, including monitoring of scoring procedures and the inclusion of validated controls, is mandatory. In the UK, participation and satisfactory performance in the UK NEQAS ICC and ISH HER2 IHC and ISH modules is a requirement (www.ukneqasiccish.org).

Standardisation of HER2 IHC staining is best achieved by using a commercial kit/assay. In-house 'home-brew' (laboratory validated) methods are not recommended but, if used, strict protocols need to be followed, including choice of antibody, antibody dilution and retrieval method, each of which can cause variability in staining results. If a commercial kit/assay is utilised, it is recommended that laboratories adhere strictly to the kit/assay protocol and scoring methodology. Local modifications of techniques can lead to false positive and negative results. Therefore, it is important to check and audit controls carefully in order to ensure test accuracy. Laboratories using bright field ISH should perform an initial validation against FISH.

Inter-observer variation in the assessment of IHC staining can lead to misclassification of HER2 status. Each individual assessor should standardise scoring against known positive, negative and borderline cases. It is also preferable to assess comparability of scoring with a colleague on a regular basis. Before undertaking evaluation of HER2, assessors should receive relevant training.

Published data suggest that inter-observer variation is significantly lower for FISH than for IHC. However, especially when developing a new service, care needs to be taken. The recommendation is that laboratories should perform validation studies by dual observer scoring when training new staff until there is concordance of 95%. For ISH validation purposes, each staff member should perform a minimum of 100 ISH test in parallel with an experienced ISH scorer to attain a minimum concordance of 95% on diagnostic results (amplified and non-amplified status) and numerical results (for both HER2 and CEP17). Continued monitoring of scoring offers advantages in quality control and training, but is not a requirement.

8.4.2 Validation of standardised assay method

Test conditions should be optimised so that distinct moderate or strong membrane staining shows >90% concordance with HER2 ISH positive samples. This can be achieved by:

1. Dual HER2 IHC and ISH assay of a contemporary series of breast carcinomas (minimum 100 cases). Use of tumour tissue array blocks for this purpose may reduce costs. HER2 ISH assay can be confined to those cases demonstrating 3+, 2+ and 1+ membrane reactivity.
2. Alternatively, a series of carcinomas that have already been scored for HER2 IHC and ISH, from a reference laboratory, can be used.

Laboratories not able to standardise in-house methodology should also consider using a commercial validated kit assay system.

8.4.3 IHC principles and use of controls

The inclusion of controls, ideally including on slide control(s), and their detailed scrutiny are essential to ensure test accuracy. Controls whose HER2 status has been validated and producing results close to important decision making points are recommended. Tissue-based controls, from breast cancers, should also be used in all assay runs, ideally showing 3+, 2+ and 1+/0 patterns. Control material should be similarly fixed and processed to the test tissue. Control sections should be ideally cut at the same time as the test material. Long-term storage of pre-cut control sections is strongly discouraged. Cell line preparations containing multiple samples of known HER2 status characterised by FISH and IHC and inclusion of a tumour tissue from IHC 3+ case on each slide are useful as additional controls.

- Excessive antigen retrieval should be monitored by evaluating normal breast epithelial cells as an internal control. Should membrane staining be identified in the normal cell population, excessive antigen retrieval may have occurred and retesting of the entire run should be considered. Any such tests should certainly be interpreted with great care; it is reasonable to score a 0 or 1+ tumour as negative, but 2+ or 3+ tumours should have staining repeated. If there is doubt between a 1+/2+ result and a 2+/3+ result, either the IHC should be repeated or amplification status should be assessed using ISH. If membrane staining of normal epithelial cells is seen in a number of cases from the same staining run consideration should be made to repeat staining of the whole run.
- Crushing and edge artefact, particularly affect core biopsies. ISH, or repeat IHC on the surgical specimen, may be needed. The potential gradient effects of suboptimal fixation, particularly in larger surgical specimens, must also be considered in interpretation of staining.
- It is essential that assay procedures be standardised so that staining is reliable. As there can be variation between batches of reagents, it is vital that controls are assessed critically for every run. New batches of antibody should also be tested before commencing routine application. Use of standardised operating procedures, including routine use of control materials, is recommended.

8.4.4 ISH principles and use of controls

ISH testing for HER2 should meet the following criteria:

- comprehensive standardisation of methodology
- validated controls: the inclusion of a chromosome 17 probe to allow for correction of the HER2 signal number for chromosome 17 aneusomy (seen in ~30% of cases and reportedly commoner in tumours that show discrepant HER2 expression and in tumours with discordant HER2-protein and gene copy number measurements) is recommended.

8.4.5 Caseload

Laboratories providing a testing service should be carrying out a minimum of 250 assays per year for immunohistochemical detection of HER2. This target level has been set to ensure higher consistency of assay quality and continuing expertise of assay providers.

Centres with low numbers of cases (<250 per year) should consider using a reference laboratory service.

Similar principles apply to ISH testing; it is recommended that laboratories testing < 100 cases per year (<150 including gastric carcinomas) consider referral of their workload to a reference laboratory. A smaller caseload has been set for ISH assay, as it is generally

accepted to be a more discriminant test at the positive–negative borderline, has greater ease of methodological standardisation, and has less observer variation.

8.4.6 General principles

Control material should be similarly fixed and processed to the test tissue. Control sections should be ideally cut at the same time as the test material. Long-term storage of pre-cut control sections is strongly discouraged. There is no evidence that storage of blocks leads to deterioration of signal. ISH should be performed on the same block as used for IHC, especially if the IHC result was 2+.

It is advisable that areas of the invasive carcinoma to be scored with ISH are located using a serial section stained with haematoxylin and eosin (H&E) and HER2 IHC where available. Care should be taken to avoid areas of ductal carcinoma *in situ* (DCIS), which can show amplification even when adjacent invasive tumour cells are negative. With experience, such features can be identified under fluorescence microscopy, however the use of serial H&E sections is essential should there be any uncertainty.

Tissue digestion should be standardised to maintain nuclear morphology and should follow strict protocols. Some laboratories find it helpful to evaluate nuclear structure before hybridisation and to adjust digestion, where appropriate, to preserve nuclear integrity. This may be particularly valuable with difficult sections, bone biopsies, etc. Evaluation of sections before hybridisation can also improve efficiency and is recommended. Hybridisation and washing steps should be standardised. Guidance can be provided by the reference laboratories. Use of automated tissue processors and standardised commercial tissue digestion kits can improve consistency and should be considered.

It is recommended that commercially available validated probes are used. There are a number of commercial kits for HER2 ISH using both fluorescence and chromogen based detection systems and which are all acceptable, once properly validated.

Short turnaround times for HER2 testing that do not delay the management of patients are recommended. Turnaround time is recognised to be variable between different centres, and can be addressed at the level of cancer networks and local services (Figure 46). The National Institute for Clinical Excellence (NICE) recommends that HER2 status of the tumour be assessed and the results made available within 2 weeks to allow planning of systemic treatment by the multidisciplinary team and that local arrangements and written clinical protocols are in place to ensure HER2 status results are available within this time (<http://publications.nice.org.uk/breast-cancer-quality-standard-qs12/quality-statement-5-pathology-er-and-her2-status#quality-measure-5>). It is also important to emphasise the role of improved communication between pathologists/laboratories performing the test and clinicians to ensure proper handling of specimens (i.e. pre-fixation time and fixation type), short turnaround time and ensure proper interpretation of the test results.

8.4.7 Audit

Regular and ongoing audit should be undertaken. Laboratories should audit their overall positive rate for HER2 using a combination of IHC and ISH. It is important to ensure that the sample size is adequate. Of note, the average proportion of invasive breast cancer cases recorded as HER2 positive is 14.5% (UK NEQAS ICC and ISH combined 5 year national audit data), with 14.3% of primary carcinomas and 18% of metastatic cases being HER2 positive (Table 10). Of these cases approximately 22% cases are reported as borderline (2+) on IHC, of which 15–16% are reported as HER2 ISH amplified¹⁰¹. The proportion of HER2 positive breast cancers found in screen detected breast cancer cases is recognised to be lower than in symptomatic practice. Audit of HER2 assay turnaround time is also important, as it is critical to patient pathway.

Table 10 Proportion of HER2 positive primary and metastatic breast cancers

	0 (%)	1+ (%)	2+ (%)	3+ (%)	ISH + (%)	Overall HER2 positive (%)
Overall	33.1	33.6	21.7	11.6	14.7	14.5
Primary carcinoma	32.9	34.0	21.7	11.5	14.6	14.2
Metastatic lesion	36.6	27.4	21.1	14.9	16.2	18.0

8.4.8 External quality assurance for HER2 testing in the UK

All UK clinical laboratories utilising IHC or ISH to assess HER2 status as a predictive marker must participate in an appropriate external quality assurance (EQA) programme, such as that run by the UK National External Quality Assessment Scheme for Immunocytochemistry and *in situ* hybridisation (UK NEQAS ICC and ISH).

8.4.9 Caseload

In the era of personalised medicine and the commonplace routine practice of multidisciplinary team (MDT) meeting for discussion of diagnosis and management of all cancer patients in the UK, improved communication within the team is considered of paramount importance. Although for many years there has been collaboration between pathologists and patient facing clinicians in the UK, this guideline further emphasises the importance of this collaboration. Close communication with surgeons and radiologists is therefore advised in order to improve control over samples prefixation time and fixation type, and with oncologists to improve understanding of interpretation of the results. This is also expected to facilitate control over HER2 test turn-around time.

8.5 Quality assurance for HER2 receptor evaluation

All UK clinical laboratories utilising immunohistochemical assays or *in situ* hybridisation to assess HER2 status as a predictive or prognostic marker must participate in an appropriate external quality assurance (EQA) programme, such as that run by the UK National External Quality Assessment Scheme for Immunocytochemistry and *in situ* hybridisation (UK NEQAS ICC and ISH).

8.5.1 Distribution of EQA material

UK NEQAS ICC and ISH have nearly 300 participants for their breast HER2 IHC module, of which 72 are from the UK. The assessments take place on a quarterly basis, with unstained formalin fixed and paraffin processed carcinoma cell lines distributed used in quality control assessments. The cell lines have been updated from those initially used^{123,124} and consist of breast carcinoma cells showing the full range of diagnostic membrane staining (see Table 11) and have been further characterised for gene status using FISH. UK NEQAS ICC and ISH data clearly indicates that commercial kits produce more reproducible staining than those from 'home-brew' methods. Information on kits that work well is available from the UK NEQAS website and journal (www.ukneqasiccish.org).

Table 11: The cell lines used by the UK NEQAS ICC and ISH EQA schemes

Cell line	HER2 status by IHC ¹	HER2 status by FISH ²
SK-BR-3	3+	Amplified
MDA-MB-453	2+	Borderline: amplified to amplified
MDA-MB-175	1+	Not amplified
MDA-MB-231	Negative	Not amplified

Participating laboratories are requested to stain the UK NEQAS ICC and ISH section using their usual clinical methodology. As well as the UK NEQAS ICC and ISH slide, participants are also requested to submit their own in-house control material for assessment. In-house control material should ideally include 3+, 2+ and 1+/0 invasive breast cancer cases and show good morphological preservation, which is paramount to gauge the sensitivity of the HER2 IHC test. However, it has become quite apparent that as patient tumour size and respective biopsies become smaller laboratories are finding it difficult to source appropriate invasive control material. It is therefore acceptable by UK NEQAS ICC and ISH to submit DCIS in-house tissue that has the expected range (3+, 2+ and 1+/0) of membrane staining.

8.5.2 Assessment procedure

The HER2 IHC slides are evaluated by a panel of 4 expert assessors using an adapted method initially devised by the Clinical Trials Assay. Due to the nature of cell lines, where cell line viability can be from 30–90%, the expected level of membrane staining is initially controlled by cutting and testing every 50th section. Furthermore, the UK NEQAS ICC and ISH has devised an EQA specific algorithm for scoring cell lines and in-house control sections (Table 12), in order to provide enhanced feedback to participants on the sensitivity/specificity of their test. This is illustrated further below.

Assessors score the cell lines using the guidelines above and a participant must achieve the expected level of staining for each of the four cell lines. An ‘acceptable’ score is awarded when more than 3 out of the 4 assessor are in agreement, a ‘borderline pass’ is awarded when two out of the four assessors find the staining to be appropriate and an ‘unacceptable’ score is awarded when more than three out of the four assessors find the staining to be unacceptable, which could be due a) staining being stronger than expected, leading to false positive staining in a clinical situation; b) staining being weaker than expected, possibly leading to false negative staining in a clinical situation; or c) uninterpretable, due to reasons shown in the table above.

8.5.3 Poor performance monitoring

The UK NEQAS ICC and ISH also have a duty to monitor the performance of all UK clinical laboratories performing breast HER2 IHC testing. Because of the direct impact that the results of assays for hormonal receptors have on patient management, more stringent performance monitoring mechanisms are employed. Furthermore, as of September 2010 the National Quality Advisory Panel (NQAAP) has made it mandatory for EQA schemes to use a ‘traffic light’ system for the grading of all its UK participants. Table 13 highlights the traffic-light system used in the breast hormonal receptor module. The poor performance criteria are applicable only to the UK NEQAS ICC and ISH distributed cell lines and monitoring covers the five most recent assessment periods. Although in-house sections are not part of the poor performance monitoring system, in-house material scores may also be used to gauge overall performance status.

Table 12: The cell lines scoring system used by the UK NEQAS ICC EQA scheme

Cell line	Score	Acceptable level/s of staining during assessments	Description of staining pattern used by the assessors
SK-BR-3	3	3+ only	The 3+ cell line has a wide threshold of complete membrane staining showing strong staining. Only this level of membrane staining is deemed acceptable for this cell line.
MDA-MB-453	2+	2+ or 1+/2+ or 2+/3+	i) 1+/2+: Staining is slightly weaker than expected when compared to the 'gold standard' stained sections. ii) 2+/3+: Staining is slightly stronger than expected when compared to the 'gold standard' stained sections
MDA-MB-175	1+	1+ or 0/1+ or 1+/0	i) 0/1+: Staining is more towards the weaker end of 1+ staining but still acceptable. ii) 1+/0: Staining is more towards the weaker end of 1+ staining but still acceptable.
MDA-MB-231	Negative	0 or 0/1+ or 1+/0	0/1+ or 1+/0 = Cells are starting to show very weak membrane staining
<p>U = uninterpretable scores</p> <p>Assessors may also give a score of 'U' indicating that the cell lines/tissue sections were 'uninterpretable' due to the reasons set out below. A score of U/x, e.g. U/3+ or U/2+ or U/1+ or U/0 indicates a borderline uninterpretable scores indicating that the staining is just about readable and further improvements are required.</p>			

Table 13: The traffic-light system used to summarise performance in the breast hormonal receptor module

Status	When triggered	Monitoring procedure
GREEN	1 underperformance (1 score = No) over 5 runs on NEQAS ICC slides	No issues with poor performance. Participant will be offered assistance to improve
AMBER	2 underperformances (2 scores = No) over 5 runs on NEQAS ICC slides	Participant and Head of Department will be notified of continued underperformance and will be sent a 'Warning letter' indicating that they are close to being deemed a poor performer and to contact the scheme director. The scheme Director will then provide advice and assistance on how the laboratory concerned might improve their results
RED	3 underperformances (3 scores = No) over 5 runs on NEQAS ICC slides	Participant and Head of Department will be notified that they have been deemed a 'poor performer' and to contact the scheme Director to discuss the situation. The scheme is also obliged to refer the laboratory to NQAAP

9 Comments/additional information

Any relevant information should be entered here as free text. Please also state whether any further special investigations have been undertaken, such as additional receptor assessment or growth fraction analysis. Many centres now use combinations of prognostic factors in the form of a prognostic index to assist clinical management. Guidance on Prognostic classifiers such as the Nottingham Prognostic Index is given in Appendix H.

10 Diagnostic staging and coding

Staging and SNOMED coding are required for the COSD V2.1 core dataset.

10.1 pTNM status should be recorded according to the 7th edition UICC (Appendix D)

TNM stage grouping can be deferred until all current staging information is available and if appropriate, until after MDT discussion. A stage group can be added to a histopathology report as a non-core item but the report should indicate that this is the minimum stage group based on the information in the report.

General principles of TNM staging:

pT Primary tumour

pTx Primary tumour cannot be assessed

pTis Carcinoma *in situ*

pT1, pT2, pT3, pT4

Additional descriptors can be used:

The suffix 'm' indicates the presence of multiple primary tumours in a single site and is recorded in parentheses, e.g. pT(m) NM.

The 'r' prefix indicates a recurrent tumour when staging is carried out after a documented disease-free interval.

pN Regional lymph node status

pM Distant metastasis

Full details are provided in Appendix D.

10.2 SNOMED codes

SNOMED Topography (T) code must be recorded for the anatomical site.

SNOMED Morphology (M) code must be recorded for the diagnosis/tumour morphology.

A list of applicable T and M codes is provided in Appendix E.

11 Non-core data items

These data items are not recognised as core and so are not included on the datasets. However, it is recognised that these additional data items may be collected by some laboratories:

- DCIS growth pattern (solid, cribriform, papillary, micropapillary, apocrine, flat, comedo, other)

- inflammation present in association with DCIS
- components of grade (tubules, nuclear pleomorphism, mitoses)
- intraoperative assessment of lymph nodes
- progesterone status and score
- proliferation (Ki67) index.
- prognostic tools such as Oncotype Dx.

12 Criteria for audit

As recommended by the RCPATH as key performance indicators (see *Key Performance Indicators – Proposals for implementation*, July 2013

<https://www.rcpath.org/profession/clinical-effectiveness/key-performance-indicators-kpi.html>):

- Cancer resections must be reported using a template or proforma, including items listed in the English COSD which are, by definition, core data items in RCPATH cancer datasets. English Trusts are required to implement the structured recording of core pathology data in the COSD by January 2014.
Standard: 95% of reports must contain structured data.
- Histopathology cases that are reported, confirmed and authorised within seven and ten calendar days of the procedure.
Standard: 80% of cases must be reported within seven calendar days and 90% within ten calendar days.

The following standards are also suggested:

- Completeness of histopathology core items recorded. The standard is that reports should contain 100% of the core items.

13 References

1. Association of Breast Surgery at BASO 2009. Surgical guidelines for the management of breast cancer. *Eur J Surg Oncol* 2009;35(Supplement 1):S1–S22.
2. Singleton M, Firth M, Stephenson T, Morrison G, Baginska J. Radiation-guided breast sentinel lymph node biopsies – is a handling delay for radiation protection necessary? *Histopathology* 2012;61:277–282.
3. Hodi Z, Ellis IO, Elston CW, Pinder SE, Donovan G, Macmillan RD *et al.* Comparison of margin assessment by radial and shave sections in wide local excision specimens for invasive carcinoma of the breast. *Histopathology* 2010;56:573–580.
4. Thomson JZ, Evans AJ, Pinder SE, Burrell HC, Wilson AR, Ellis IO. Growth pattern of ductal carcinoma *in situ* (DCIS): a retrospective analysis based on mammographic findings. *Br J Cancer* 2001, 20;85:225–227.
5. Baslaim MM, Al Malik OA, Al-Sobhi SS, Ibrahim E, Ezzat A, Ajarim D *et al.* Decreased axillary lymph node retrieval in patients after neoadjuvant chemotherapy. *Am J Surg* 2002;184:299–301.

6. Xu X, Roberts SA, Pasha TL, Zhang PJ. Undesirable cytokeratin immunoreactivity of native nonepithelial cells in sentinel lymph nodes from patients with breast carcinoma. *Arch Pathol Lab Med* 2000;124:1310–1313.
7. Giuliano AE, Hunt KK, Ballman KV, Beitsch PD, Whitworth PW, Blumencranz PW *et al.* Axillary dissection vs no axillary dissection in women with invasive breast cancer and sentinel node metastasis: a randomized clinical trial. *JAMA* 2011;305:569–575.
8. Liu LC, Lang JE, Lu Y, Roe D, Hwang SE, Ewing CA *et al.* Intraoperative frozen section analysis of sentinel lymph nodes in breast cancer patients: a meta-analysis and single-institution experience. *Cancer* 2011;117:250–258.
9. Tew K, Irwig L, Matthews A, Crowe P, Macaskill P. Meta-analysis of sentinel node imprint cytology in breast cancer. *Br J Surg* 2005;92:1068–1080.
10. Cserni G. Intraoperative analysis of sentinel lymph nodes in breast cancer by one-step nucleic acid amplification. *J Clin Pathol* 2012;65:193–199.
11. Walker RA, Hanby A, Pinder SE, Thomas J, Ellis IO, National Coordinating Committee for Breast Pathology Research Subgroup. Current issues in diagnostic breast pathology. *J Clin Pathol* 2012;65:771–785.
12. Pinder SE, Reis-Filho JS. Non-operative breast pathology: columnar cell lesions. *J Clin Pathol* 2007;60:1307–1312.
13. Fraser JL, Raza S, Chorny K, Connolly JL, Schnitt SJ. Columnar alteration with prominent apical snouts and secretions: a spectrum of changes frequently present in breast biopsies performed for microcalcifications. *Am J Surg Pathol* 1998;22:1521–1527.
14. Collins LC, Schnitt SJ. Papillary lesions of the breast: selected diagnostic and management issues. *Histopathology* 2008;52:20–29.
15. Putti TC, Pinder SE, Elston CW, Lee AH, Ellis IO. Breast pathology practice: most common problems in a consultation service. *Histopathology* 2005;47:445–457.
16. Page DL. Atypical hyperplasia, narrowly and broadly defined. *Hum Pathol* 1991;22:631–632.
17. Page DL, Kidd TE Jr, Dupont WD, Simpson JF, Rogers LW. Lobular neoplasia of the breast: higher risk for subsequent invasive cancer predicted by more extensive disease. *Hum Pathol* 1991;22:1232–1239.
18. Fadare O, Dadmanesh F, Alvarado-Cabrero I, Snyder R, Stephen Mitchell J, Tot T *et al.* Lobular intraepithelial neoplasia [lobular carcinoma in situ] with comedo-type necrosis: A clinicopathologic study of 18 cases. *Am J Surg Pathol* 2006;30:1445–1453.
19. Holland R, Hendriks JH. Microcalcifications associated with ductal carcinoma in situ: mammographic-pathologic correlation. *Semin Diagn Pathol* 1994;11:181–192.
20. Holland R, Hendriks JH, Vebeek AL, Mravunac M, Schuurmans Stekhoven JH. Extent, distribution, and mammographic/histological correlations of breast ductal carcinoma in situ. *Lancet* 1990;335:519–522.
21. Quinn CM, Ostrowski JL. Cytological and architectural heterogeneity in ductal carcinoma *in situ* of the breast. *J Clin Pathol* 1997;50:596–599.
22. Lester SC, Bose S, Chen Y-Y, Connolly JL, de Baca ME, Fitzgibbons PL *et al.* Protocol for the examination of specimens from patients with ductal carcinoma *in situ* of the breast. *Arch Pathol Lab Med.* 2009;133:15–25.
23. Tavassoli FA, Norris HJ. Intraductal apocrine carcinoma: a clinicopathologic study of 37 cases. *Mod Pathol* 1994 ;7:813–818.

24. O'Malley FP, Bane A. An update on apocrine lesions of the breast. *Histopathology* 2008;52:3–10.
25. Fisher ER, Brown R. Intraductal signet ring carcinoma. A hitherto undescribed form of intraductal carcinoma of the breast. *Cancer* 1985;55:2533–2537.
26. Tan PH, Lui GG, Chiang G, Yap WM, Poh WT, Bay BH. Ductal carcinoma *in situ* with spindle cells: a potential diagnostic pitfall in the evaluation of breast lesions. *Histopathology* 2004;45:343–351.
27. Kawasaki T, Nakamura S, Sakamoto G, Murata S, Tsunoda-Shimizu H, Suzuki K *et al.* Neuroendocrine ductal carcinoma *in situ* (NE-DCIS) of the breast--comparative clinicopathological study of 20 NE-DCIS cases and 274 non-NE-DCIS cases. *Histopathology* 2008;53:288–298.
28. Guerry P, Erlandson RA, Rosen PP. Cystic hypersecretory hyperplasia and cystic hypersecretory duct carcinoma of the breast. Pathology, therapy, and follow-up of 39 patients. *Cancer* 1988;61:1611–1620.
29. Page DL, Salhany KE, Jensen RA, Dupont WD. Subsequent breast carcinoma risk after biopsy with atypia in a breast papilloma. *Cancer* 1996;78:258–266.
30. Collins LC, Carlo VP, Hwang H, Barry TS, Gown AM, Schnitt SJ. Intracystic papillary carcinomas of the breast: a reevaluation using a panel of myoepithelial cell markers. *Am J Surg Pathol* 2006;30:1002–1007.
31. Rakha EA, Gandhi N, Climent F, van Deurzen CH, Haider SA, Dunk L *et al.* Encapsulated papillary carcinoma of the breast: an invasive tumor with excellent prognosis. *Am J Surg Pathol* 2011;35:1093–1103.
32. Carter D, Orr SL, Merino MJ. Intracystic papillary carcinoma of the breast. After mastectomy, radiotherapy or excisional biopsy alone. *Cancer* 1983;52:14–19.
33. Nagi C, Bleiweiss I, Jaffer S. Epithelial displacement in breast lesions: a papillary phenomenon. *Arch Pathol Lab Med* 2005;129:1465–1469.
34. Bilous M. Breast core needle biopsy: issues and controversies. *Mod Pathol* 2010;23:536–545.
35. McLaughlin CS, Petrey C, Grant S, Ransdell JS, Reynolds C. Displaced epithelium after liposuction for gynecomastia. *Int J Surg Pathol* 2011;19:510–513.
36. Koo JS, Jung WH, Kim H. Epithelial displacement into the lymphovascular space can be seen in breast core needle biopsy specimens. *Am J Clin Pathol* 2010;133:781–787.
37. Diaz NM, Cox CE, Ebert M, Clark JD, Vrcel V, Stowell N *et al.* Benign mechanical transport of breast epithelial cells to sentinel lymph nodes. *Am J Surg Pathol* 2004;28:1641–1645.
38. Singhai R, Patil VW, Jaiswal SR, Patil SD, Tayade MB, Patil AV. E-Cadherin as a diagnostic biomarker in breast cancer. *N Am J Med Sci* 2011;3:227–233.
39. Fisher ER, Kenny JP, Sass R, Dimitrov NV, Siderits RH, Fisher B. Medullary cancer of the breast revisited. *Breast Cancer Res Treat* 1990;16:215–229.
40. Ridolfi RL, Rosen PP, Port A, Kinne D, Mike V. Medullary carcinoma of the breast: a clinicopathologic study with 10 year follow-up. *Cancer* 1977;40:1365–1385.
41. Chen AC, Paulino AC, Schwartz MR, Rodriguez AA, Bass BL, Chang JC *et al.* Prognostic markers for invasive micropapillary carcinoma of the breast: a population-based analysis. *Clin Breast Cancer* 2013;13:133–139.

42. Ho BCS, Tan HW, Lee VKM, Tan PH. Preoperative and intraoperative diagnosis of low-grade adenosquamous carcinoma of the breast: potential diagnostic pitfalls. *Histopathology* 2006;49:603–611.
43. Kawaguchi K, Shin SJ. Immunohistochemical staining characteristics of low-grade adenosquamous carcinoma of the breast. *Am J Surg Pathol* 2012;36:1009–1020.
44. Van Hoesen KH, Drudis T, Cranor ML, Erlandson RA, Rosen PP. Low-grade adenosquamous carcinoma of the breast. A clinicopathologic study of 32 cases with ultrastructural analysis. *Am J Surg Pathol* 1993;17:248–258.
45. Soo K, Tan PH. Low-grade adenosquamous carcinoma of the breast. *J Clin Pathol* 2013; 16:506–511.
46. Gobbi H, Simpson JF, Borowsky A, Jensen RA, Page DL. Metaplastic breast tumors with a dominant fibromatosis-like phenotype have a high risk of local recurrence. *Cancer* 1999; 85:2170–2182.
47. Tse GM, Tan PH, Putti TC, Lui PCW, Chaiwun B, Law BKB. Metaplastic carcinoma of the breast: a clinicopathological review. *J Clin Pathol* 2006;59:1079–1083.
48. Page DL, Ellis IO, Elston CW. Histologic grading of breast cancer. Let's do it. *Am J Clin Pathol* 1995;103:123–124.
49. Rakha EA, El-Sayed ME, Lee AH, Elston CW, Grainge MJ, Hodi Z *et al*. Prognostic significance of Nottingham histologic grade in invasive breast carcinoma. *J Clin Oncol* 2008;26:3153–3158.
50. Elston CW, Ellis IO. Pathological prognostic factors in breast cancer. The value of histological grade in breast cancer: experience from a large study with long-term follow-up. *Histopathology* 1991;19:403–410.
51. Dunne B, Going JJ. Scoring nuclear pleomorphism in breast cancer. *Histopathology* 2001;39:259–265.
52. Verhoeven D, Bourgeois N, Derde MP, Kaufman L, Buysens N. Comparison of cell growth in different parts of breast cancers. *Histopathology* 1990;17:505–509.
53. Connor AJM, Pinder SE, Elston CW, Bell JA, Wencyk p, Robertson JFR *et al*. Intratumoural heterogeneity of proliferation in invasive breast carcinoma evaluated with MIB1 antibody. *The Breast* 1997;6:171–176.
54. Pereira H, Pinder SE, Sibbering DM, Galea MH, Elston CW, Blamey RW *et al*. Pathological prognostic factors in breast cancer. IV: Should you be a typer or a grader? A comparative study of two histological prognostic features in operable breast carcinoma. *Histopathology* 1995;27:219–226.
55. Rakha EA, El-Sayed ME, Menon S, Green AR, Lee AHS, Ellis IO. Histologic grading is an independent prognostic factor in invasive lobular carcinoma of the breast. *Breast Cancer Res Treat* 2008;111:121–127.
56. Lynch J, Pattekar R, Barnes DM, Hanby AM, Campjohn RS, Ryder K *et al*. Mitotic counts provide additional prognostic information in grade II mammary carcinoma. *J Pathol* 2002;196:275–279.
57. Harris GC, Denley HE, Pinder SE, Lee AH, Ellis IO, Elston CW *et al*. Correlation of histologic prognostic factors in core biopsies and therapeutic excisions of invasive breast carcinoma. *Am J Surg Pathol* 2003;27:11–15.
58. O'Shea AM, Rakha EA, Hodi Z, Ellis IO, Lee AH. Histological grade of invasive carcinoma of the breast assessed on needle core biopsy – modifications to mitotic count assessment to improve agreement with surgical specimens. *Histopathology* 2011;59:543–548.

59. Pinder SE, Ellis IO, Galea M, O'Rourke S, Blamey RW, Elston CW. Pathological prognostic factors in breast cancer. III. Vascular invasion: relationship with recurrence and survival in a large study with long-term follow-up. *Histopathology* 1994;24:41–47.
60. Lee AH, Pinder SE, Macmillan RD, Mitchell M, Ellis IO, Elston CW *et al*. Prognostic value of lymphovascular invasion in women with lymph node negative invasive breast carcinoma. *Eur J Cancer* 2006;42:357–362.
61. Mohammed RA, Ellis IO, Lee AH, Martin SG. Vascular invasion in breast cancer; an overview of recent prognostic developments and molecular pathophysiological mechanisms. *Histopathology* 2009;55:1–9.
62. Rakha EA, Martin S, Lee AH, Morgan D, Pharoah PD, Hodi Z *et al*. The prognostic significance of lymphovascular invasion in invasive breast carcinoma. *Cancer* 2012;118:3670–3680.
63. Braun M, Flucke U, Debald M, Walgenbach-Bruenagel G, Walgenbach K-J, Holler T *et al*. Detection of lymphovascular invasion in early breast cancer by D2-40 (podoplanin): a clinically useful predictor for axillary lymph node metastases. *Breast Cancer Res Treat* 2008;112:503–511.
64. Turner RR, Weaver DL, Cserni G, Lester SC, Hirsch K, Elashoff DA *et al*. Nodal stage classification for breast carcinoma: improving interobserver reproducibility through standardized histologic criteria and image-based training. *J Clin Oncol* 2008;26:258–263.
65. de Mascarel I, MacGrogan G, Debled M, Brouste V, Mauriac L. Distinction between isolated tumor cells and micrometastases in breast cancer: is it reliable and useful? *Cancer* 2008;112:1672–1678.
66. Cserni G, Bianchi S, Vezzosi V, van Diest P, van Deurzen C, Sejbien I *et al*. Variations in sentinel node isolated tumour cells/micrometastasis and non-sentinel node involvement rates according to different interpretations of the TNM definitions. *Eur J Cancer* 2008;44:2185–2191.
67. Pinder SE, Provenzano E, Earl H, Ellis IO. Laboratory handling and histology reporting of breast specimens from patients who have received neoadjuvant chemotherapy. *Histopathology* 2007;50:409–417.
68. von Minckwitz G, Untch M, Blohmer JU, Costa SD, Eidtmann H, Fasching PA *et al*. Definition and impact of pathologic complete response on prognosis after neoadjuvant chemotherapy in various intrinsic breast cancer subtypes. *J Clin Oncol* 2012;30:1796–1804.
69. Chevallier B, Roche H, Olivier JP, Chollet P, Hurteloup P. Inflammatory breast cancer. Pilot study of intensive induction chemotherapy (FEC-HD) results in a high histologic response rate. *Am J Clin Oncol* 1993;16:223–228.
70. Sataloff DM, Mason BA, Prestipino AJ, Seinige UL, Lieber CP, Baloch Z. Pathologic response to induction chemotherapy in locally advanced carcinoma of the breast: a determinant of outcome. *J Am Coll Surg* 1995;180:297–306.
71. Ogston KN, Miller ID, Payne S, Hutcheon AW, Sarkar TK, Smith I *et al*. A new histological grading system to assess response of breast cancers to primary chemotherapy: prognostic significance and survival. *Breast* 2003;12:320–327.
72. Symmans WF, Peintinger F, Hatzis C, Rajan R, Kuerer H, Valero V *et al*. Measurement of residual breast cancer burden to predict survival after neoadjuvant chemotherapy. *J Clin Oncol* 2007;25:4414–4422.
73. Newman LA, Pernick NL, Adsay V, Carolin KA, Philip PA, Siperski S *et al*. Histopathologic evidence of tumor regression in the axillary lymph nodes of patients treated with preoperative chemotherapy correlates with breast cancer outcome. *Ann Surg Oncol* 2003;10:734–739.

74. Davies C, Godwin J, Gray R, Clarke M, Cutter D, Darby S *et al*. Relevance of breast cancer hormone receptors and other factors to the efficacy of adjuvant tamoxifen: patient-level meta-analysis of randomised trials. *Lancet* 2011;378:771–784.
75. Hammond MEH, Hayes DF, Dowsett M, Allred DC, Hagerty KL, Badve S *et al*. American Society of Clinical Oncology/College of American Pathologists guideline recommendations for immunohistochemical testing of estrogen and progesterone receptors in breast cancer. *Arch Pathol Lab Med* 2010;134:907–922.
76. Liebmann RD, Reynolds T, Williams P, Macaskill S. *Review of cellular pathology governance, breast reporting and immunohistochemistry at Sherwood Forest Hospitals NHS Foundation Trust. A report prepared for the Care Quality Commission in respect of diagnostic and screening procedure*. London: RCPATH, 2013.
77. Rhodes A, Jasani B, Barnes DM, Bobrow LG, Miller KD. Reliability of immunohistochemical demonstration of oestrogen receptors in routine practice: interlaboratory variance in the sensitivity of detection and evaluation of scoring systems. *J Clin Pathol*. 2000;53:125–130.
78. Rhodes A, Jasani B, Balaton AJ, Barnes DM, Anderson E, Bobrow LG *et al*. Study of interlaboratory reliability and reproducibility of estrogen and progesterone receptor assays in Europe. Documentation of poor reliability and identification of insufficient microwave antigen retrieval time as a major contributory element of unreliable assays. *Am J Clin Pathol* 2001;115: 44–58.
79. Ibrahim M, Dodson A, Barnett S, Fish D, Jasani B, Miller K. Potential for false-positive staining with a rabbit monoclonal antibody to progesterone receptor (SP2): findings of the UK National External Quality Assessment Scheme for Immunocytochemistry and FISH highlight the need for correct validation of antibodies on introduction to the laboratory. *Am J Clin Pathol* 2008;129: 398–409.
80. Fitzgibbons PL, Murphy DA, Hammond ME, Allred DC, Valenstein PN. Recommendations for validating estrogen and progesterone receptor immunohistochemistry assays. *Arch Pathol Lab Med* 2010;134:930–935.
81. Harvey JM, Clark GM, Osborne CK, Allred DC. Estrogen receptor status by immunohistochemistry is superior to the ligand-binding assay for predicting response to adjuvant endocrine therapy in breast cancer. *J Clin Oncol* 1999;17:1474–1481.
82. Leake R, Barnes D, Pinder S, Ellis I, Anderson L, Anderson T *et al*. Immunohistochemical detection of steroid receptors in breast cancer: a working protocol. UK Receptor Group, UK NEQAS, The Scottish Breast Cancer Pathology Group, and The Receptor and Biomarker Study Group of the EORTC. *J Clin Pathol* 2000;53:634–635.
83. McCarty KS, Jr., Miller LS, Cox EB, Konrath J, McCarty KS Sr. Estrogen receptor analyses. Correlation of biochemical and immunohistochemical methods using monoclonal antireceptor antibodies. *Arch Pathol Lab Med* 1985;109:716–721.
84. Hodi Z, Chakrabarti J, Lee AH, Ronan JE, Elston CW, Cheung KL *et al*. The reliability of assessment of oestrogen receptor expression on needle core biopsy specimens of invasive carcinomas of the breast. *J Clin Pathol* 2007;60:299–302.
85. Arnedos M, Nerurkar A, Osin P, A'Hern R, Smith IE, Dowsett M. Discordance between core needle biopsy (CNB) and excisional biopsy (EB) for estrogen receptor (ER), progesterone receptor (PgR) and HER2 status in early breast cancer (EBC). *Ann Oncol* 2009;20:1948–1952.
86. Slamon DJ, Godolphin W, Jones LA, Holt JA, Wong SG, Keith DE *et al*. Studies of the HER-2/neu proto-oncogene in human breast and ovarian cancer. *Science* 1989;244:707–712.
87. Ross JS, Fletcher JA. HER-2/neu (c-erb-B2) gene and protein in breast cancer. *Am J Clin Pathol* 1999;112:S53–67.

88. Gianni L, Dafni U, Gelber RD, Azambuja E, Muehlbauer S, Goldhirsch A *et al.* Treatment with trastuzumab for 1 year after adjuvant chemotherapy in patients with HER2-positive early breast cancer: a 4-year follow-up of a randomised controlled trial. *Lancet Oncol* 2011;12:236–244.
89. Piccart-Gebhart MJ, Procter M, Leyland-Jones B, Goldhirsch A, Untch M, Smith I *et al.* Trastuzumab after adjuvant chemotherapy in HER2-positive breast cancer. *N Engl J Med* 2005;353:1659–1672.
90. Gianni L, Eiermann W, Semiglazov V, Manikhas A, Lluch A, Tjulandin S *et al.* Neoadjuvant chemotherapy with trastuzumab followed by adjuvant trastuzumab versus neoadjuvant chemotherapy alone, in patients with HER2-positive locally advanced breast cancer (the NOAH trial): a randomised controlled superiority trial with a parallel HER2-negative cohort. *Lancet* 2010;375:377–384.
91. Geyer CE, Forster J, Lindquist D, Chan S, Romieu CG, Pienkowski T *et al.* Lapatinib plus capecitabine for HER2-positive advanced breast cancer. *N Engl J Med* 2006;355:2733–2743.
92. Baselga J, Bradbury I, Eidtmann H, Di Cosimo S, de Azambuja E, Aura C *et al.* Lapatinib with trastuzumab for HER2-positive early breast cancer (NeoALTTO): a randomised, open-label, multicentre, phase 3 trial. *Lancet* 2012;379:633–640.
93. Di Leo A1, Gomez HL, Aziz Z, Zvirbule Z, Bines J, Arbushites MC *et al.* Phase III, double-blind, randomized study comparing lapatinib plus paclitaxel with placebo plus paclitaxel as first-line treatment for metastatic breast cancer. *J Clin Oncol* 2008;26:5544–5552.
94. Seidman AD, Berry D, Cirincione C, Harris L, Muss H, Marcom PK *et al.* Randomized phase III trial of weekly compared with every-3-weeks paclitaxel for metastatic breast cancer, with trastuzumab for all HER-2 overexpressors and random assignment to trastuzumab or not in HER-2 nonoverexpressors: final results of Cancer and Leukemia Group B protocol 9840. *J Clin Oncol* 2008;26:1642–1649.
95. Untch M, Rezai M, Loibl S, Fasching PA, Huober J, Tesch H *et al.* Neoadjuvant treatment with trastuzumab in HER2-positive breast cancer: results from the GeparQuattro study. *J Clin Oncol* 2010;28:2024–2031.
96. Wolff AC, Hammond ME, Schwartz JN, Hagerty KL, Allred DC, Cote RJ *et al.* American Society of Clinical Oncology/College of American Pathologists guideline recommendations for human epidermal growth factor receptor 2 testing in breast cancer. *J Clin Oncol* 2007;25:118–145.
97. Perez EA, Suman VJ, Davidson NE, Martino S, Kaufman PA, Lingle WL *et al.* HER2 testing by local, central, and reference laboratories in specimens from the North Central Cancer Treatment Group N9831 intergroup adjuvant trial. *J Clin Oncol* 2006;24:3032–3038.
98. Taucher S, Rudas M, Mader RM, Gnant M, Dubsy P, Roka S *et al.* Prognostic markers in breast cancer: the reliability of HER2/neu status in core needle biopsy of 325 patients with primary breast cancer. *Wien Klin Wochenschr* 2004;116:26–31.
99. Ellis IO, Bartlett J, Dowsett M, Humphreys S, Jasani B, Miller K *et al.* Best Practice No 176: Updated recommendations for HER2 testing in the UK. *J Clin Pathol* 2004;57:233–237.
100. *Pathology reporting of breast disease. A Joint Document Incorporating the Third Edition of the NHS Breast Screening Programme's Guidelines for Pathology Reporting in Breast Cancer Screening and the Second Edition of The Royal College of Pathologists' Minimum Dataset for Breast Cancer Histopathology*, 2005. NHSBSP Pub. No 58.
101. Walker RA1, Bartlett JM, Dowsett M, Ellis IO, Hanby AM, Jasani B *et al.* HER2 testing in the UK: further update to recommendations. *J Clin Pathol* 2008;61:818–824.

102. Hammond ME¹, Hayes DF, Dowsett M, Allred DC, Hagerty KL, Badve S *et al.* American Society of Clinical Oncology/College Of American Pathologists guideline recommendations for immunohistochemical testing of estrogen and progesterone receptors in breast cancer. *J Clin Oncol* 2010;28:2784–2795.
103. Carlson RW, Moench SJ, Hammond ME, Perez EA, Burstein HJ, Allred DC *et al.* HER2 testing in breast cancer: NCCN Task Force report and recommendations. *J Natl Compr Canc Netw* 2006;4 Suppl 3:S1–22.
104. Middleton LP¹, Price KM, Puig P, Heydon LJ, Tarco E, Sneige N *et al.* Implementation of American Society of Clinical Oncology/College of American Pathologists HER2 Guideline Recommendations in a tertiary care facility increases HER2 immunohistochemistry and fluorescence *in situ* hybridization concordance and decreases the number of inconclusive cases. *Arch Pathol Lab Med* 2009;133:775–780.
105. Chen X¹, Yuan Y, Gu Z, Shen K. Accuracy of estrogen receptor, progesterone receptor, and HER2 status between core needle and open excision biopsy in breast cancer: a meta-analysis. *Breast Cancer Res Treat* 2012;134:957–967.
106. Wolff AC, Hammond ME, Hicks DG, Dowsett M, McShane LM, Allison KH *et al.* Recommendations for human epidermal growth factor receptor 2 testing in breast cancer: American Society of Clinical Oncology/College of American Pathologists clinical practice guideline update. *J Clin Oncol* 2013;31:3997–4013.
107. Arnedos M, Nerurkar A, Osin P, A'Hern R, Smith IE, Dowsett M. Discordance between core needle biopsy (CNB) and excisional biopsy (EB) for estrogen receptor (ER), progesterone receptor (PgR) and HER2 status in early breast cancer (EBC). *Ann Oncol* 2009;20:1948–1952.
108. Lee AH, Key HP, Bell JA, Hodi Z, Ellis IO. Concordance of HER2 status assessed on needle core biopsy and surgical specimens of invasive carcinoma of the breast. *Histopathology* 2012;60:880–884.
109. Greer LT, Rosman M, Mylander WC, Hooke J, Kovatich A, Sawyer K *et al.* Does breast tumor heterogeneity necessitate further immunohistochemical staining on surgical specimens? *J Am Coll Surg* 2013;216:239–251.
110. Durgapal P¹, Mathur SR, Kalamuddin M, Datta Gupta S, Parshad R, Julka PK *et al.* Assessment of Her-2/neu status using immunocytochemistry and fluorescence *in situ* hybridization on fine-needle aspiration cytology smears: Experience from a tertiary care centre in India. *Diagn Cytopathol* 2013;42:726–731.
111. Zustin J, Boddin K, Tsourlakis MC, Burandt E, Mirlacher M, Jaenicke F *et al.* HER-2/neu analysis in breast cancer bone metastases. *J Clin Pathol* 2009;62:542–546.
112. Penault-Llorca F, Coudry RA, Hanna WM, Osamura RY, Rüschoff J, Viale G *et al.* Experts' opinion: Recommendations for retesting breast cancer metastases for HER2 and hormone receptor status. *Breast* 2013;22:200–202.
113. Lundgaard Hansen B, Winther H, Moller K. Excessive section drying of breast cancer tissue prior to deparaffinisation and antigen retrieval causes a loss in HER2 immunoreactivity. *UKNEQAS Immunocytochemistry Journal*. 2008;6:Run 76:117–122.
114. Press MF, Sauter G, Bernstein L, Villalobos IE, Mirlacher M, Zhou JY *et al.* Diagnostic evaluation of HER-2 as a molecular target: an assessment of accuracy and reproducibility of laboratory testing in large, prospective, randomized clinical trials. *Clin Cancer Res* 2005;11: 6598–6607.
115. Pauletti G, Dandekar S, Rong H, Ramos L, Peng H, Seshadri R *et al.* Assessment of methods for tissue-based detection of the HER-2/neu alteration in human breast cancer: a direct comparison of fluorescence *in situ* hybridization and immunohistochemistry. *J Clin Oncol* 2000;18:3651–3664.

116. Sauter G, Lee J, Bartlett JM, Slamon DJ, Press MF. Guidelines for human epidermal growth factor receptor 2 testing: biologic and methodologic considerations. *J Clin Oncol* 009;27:1323–1333.
117. Arnould L, Roger P, Macgrogan G, Chenard MP, Balaton A, Beauclair S *et al.* Accuracy of HER2 status determination on breast core-needle biopsies (immunohistochemistry, FISH, CISH and SISH vs FISH). *Mod Pathol* 2012;25:675–682.
118. Risio M, Casorzo L, Redana S, Montemurro F. HER2 gene-amplified breast cancers with monosomy of chromosome 17 are poorly responsive to trastuzumab-based treatment. *Oncol Rep* 2005;13:305–309.
119. Perez EA, Reinholz MM, Hillman DW, Tenner KS, Schroeder MJ, Davidson NE *et al.* HER2 and chromosome 17 effect on patient outcome in the N9831 adjuvant trastuzumab trial. *J Clin Oncol* 2010;28:4307–4315.
120. Hanna WM, Rüschoff J, Bilous M, Coudry RA, Dowsett M, Osamura RY *et al.* HER2 *in situ* hybridization in breast cancer: clinical implications of polysomy 17 and genetic heterogeneity. *Mod Pathol* 2014;27:4–18.
121. Bartlett AI, Starczynski J, Robson T, Maclellan A, Campbell FM, van de Velde CJ *et al.* Heterogeneous HER2 gene amplification: impact on patient outcome and a clinically relevant definition. *Am J Clin Pathol* 2011;136:266–274.
122. Ohlschlegel C, Zahel K, Kradolfer D, Hell M, Jochum W. HER2 genetic heterogeneity in breast carcinoma. *J Clin Pathol* 2011;64:1112–1116.
123. Rhodes A, Jasani B, Couturier J, McKinley MJ, Morgan JM, Dodson AR *et al.* A formalin-fixed, paraffin-processed cell line standard for quality control of immunohistochemical assay of HER-2/neu expression in breast cancer. *Am J Clin Pathol* 2002;117:81–89.
124. Jasani B, Reid V, Tristram C, Walker J, P. Scorer, Morgan M *et al.* Standard Reference Material: Cell Lines Development and Use of Reference Cell Lines as Standards for External Quality Assurance of HerHER-2 IHC and ISH Testing. In: Shi S-R, Taylor CR (eds). *Antigen Retrieval Immunohistochemistry Based Research and Diagnostics*. John Wiley & Sons, Inc: New Jersey, 2010.

Appendix A NHS BSP breast pathology synoptic proforma template for surgically resected lesions, including dataset and commonly used optional items

This template is provided as an example proforma for use for synoptic reporting of breast screening and symptomatic breast disease related specimens. It can be separated into separate documents for reporting benign, *in situ* carcinoma and invasive carcinoma related cases and can be adapted to suit local needs and protocols (but must include the RCPATH dataset, see Appendix B. Sections in italics are regarded as optional.

Pathology report

Patient's identifier:

Date reported: Report number:

Pathologist: Laboratory:

Surgical specimen(s)

Side: Right Left

Specimen type:

WLE Excision biopsy Localisation specimen Segmental excision

Mastectomy Subcutaneous mastectomy

Re-excision Further margins (including cavity shaves/bed biopsies)

Microdochestomy/microductectomy

SLN Axillary sampling Axillary LN level I

Axillary LN level II Axillary LN level III Total duct excision/Hadfield's procedure

Other

Specimen weight (g)

Comment:

Specimen radiograph seen: Yes No

Mammographic abnormality: Yes No Unsure

Site of previous core biopsy seen Yes No

Histological calcification Absent Benign Malignant Both

Benign lesions

Columnar cell change Complex sclerosing lesion/radial scar Fibroadenoma

Fibrocystic change Multiple papillomas Papilloma (single)

Periductal mastitis/duct ectasia Sclerosing adenosis Solitary cyst

Other Specify other.....

Epithelial proliferation: Not present Present without atypia

Flat epithelial atypia Present with atypia (ductal) Present with atypia (lobular)

Malignant lesions

Malignant *in situ* lesion: Not present Present

***In situ* components:** Ductal Lobular Paget's

DCIS grade: High Intermediate Low Not assessable

DCIS growth pattern: Solid Cribriform Papillary Micropapillary

Apocrine Flat Comedo

Other Specify other.....

DCIS necrosis: Present Absent

Inflammation: Present Absent

'Pure' DCIS size mm:

LCIS: Present Absent

Paget's disease: Present Absent

Microinvasive: Present Absent

Invasive carcinoma Present Absent

Size and extent

Tumour size (mm):

Whole tumour size (mm):

Disease extent: Localised Multiple invasive foci Not assessable

Invasive tumour type Pure (tick one box below) Mixed (tick all components present below)

Tubular/Cribriform Lobular Mucinous Medullary-like Ductal/NST Micropapillary

Other Other type/component:

Histological grade 1 2 3 Not assessable

Components (optional): Tubule formation 1 2 3 Not assessable

Nuclear pleomorphism 1 2 3 Not assessable

Mitoses 1 2 3 Not assessable

Lymphovascular invasion Present Absent Possible

Lymph node stage

Intra-operative assessment (optional)

Sentinel LN assessed: No Yes Positive Negative

Sentinel LN positive: Macrometastasis Micrometastasis ITCs

(Note ITCs only classified as node negative)

Method of assessment: PCR OSNA Frozen section Cytology Other

Axillary nodes present: No Yes

Total present:

Total positive:.....

Extracapsular spread: Present Not identified

For single node positive: Macrometastasis Micrometastasis ITCs

(Note ITCs only classified as node negative)

Other nodes present: No Yes Site:

Total present:

Total positive:.....

For single node positive: Macrometastasis Micrometastasis ITCs

(Note ITCs only classified as node negative)

Status of perinodal fat: *involved, not involved*

Summary lymph node stage:

1 = Node negative

2 = 1–3 nodes positive

3 = 4 or more nodes positive

Modifications for post neoadjuvant therapy cases:

Residual tumour size and extent

Residual invasive tumour size (mm):.....

Whole residual tumour (invasive + DCIS) size (mm):

Disease extent: Localised residual tumour Multiple residual invasive foci
Cannot be assessed

Residual invasive tumour type Pure (tick one box below)

Mixed (tick all components present below) Not applicable (no residual invasive tumour)

Tubular/cribriform Lobular Mucinous Medullary-like Ductal/NST Micropapillary

Other Other type/component:

Residual tumour histological grade: 1 2 3 Cannot be assessed

Residual *in situ* components:

DCIS: Present Absent

DCIS grade: High Intermediate Low Cannot be assessed

DCIS/pleomorphic or DCIS like LCIS size mm:

LCIS: Present Not identified

Paget's disease: Present Not identified Cannot be assessed

Microinvasive: Present Not identified

Lymphovascular invasion Present Not identified Uncertain

Post therapy lymph node stage

Axillary nodes:

Total present:

Total positive:

Other nodes: Site:

Total present:

Total positive:.....

Evidence of treatment response in the metastases: Present Absent

Number of lymph nodes with evidence of treatment response (fibrosis or histiocytic infiltrate) but no tumour cells:

Final classification of chemotherapy response

Breast disease response:

1. Complete pathological response, either (i) no residual carcinoma or (ii) no residual invasive tumour but DCIS present
2. Partial response to therapy
 - a. minimal residual disease/near total effect typically (<10% of tumour remaining in the tumour bed seen as an area of residual fibrosis delineating the original tumour extent)
 - b. Evidence of response but significant tumour remaining (>10% of tumour remaining in the tumour bed seen as an area of residual fibrosis delineating the original tumour extent)
3. No evidence of response to therapy

Lymph nodal response:

1. No evidence of metastatic disease and no evidence of changes in the lymph nodes
2. Metastatic tumour not detected but evidence of response/'down-staging', e.g. fibrosis
3. Metastatic disease present but also evidence of response, such as nodal fibrosis
4. Metastatic disease present with no evidence of response to therapy

TNM stage

T stage: pTis pT1mi pT1a pT1b pT1c pT2 pT3 pT4a pT4b
pT4c pT4d Cannot be assessed

N stage: pN0 pN1mi pN1a pN1b pN1c pN2a pN2b pN3a pN3c
Cannot be assessed

M stage: pM1 Cannot be assessed

Note: Add suffix 'y' to TNM codes for post neoadjuvant therapy treated cases

Excision status

Distance from each margin (mm)

Invasive tumour	Superior.....	Inferior	Medial	Lateral
	Deep	Superficial	Nipple margin.....	

DCIS	Superior	Inferior.....	Medial	Lateral
	Deep	Superficial	Nipple margin	

Receptor status

Oestrogen receptor status: Positive (> or = 1%) Negative (<1%)

% positive tumour cells =.....

On-slide positive control material: Present Absent

Optional:

Allred score (0–8):.....

H score (0–300):.....

HER2 IHC score: 0 Negative 1+ Negative 2+ Borderline 3+ Positive

FISH/CISH ratio:

Status: Amplified Non-amplified Borderline Not performed

Her2 copy no: Chromosome 17 no:

Final HER2 status: Positive Negative

Optional:

Progesterone receptor status: Positive (>1%) Negative (<1%)

% positive tumour cells =.....

On-slide positive control material: Present Absent

Optional:

Allred score (0–8):.....

H score (0–300):.....

Optional:

Proliferation (Ki67) index:

TNM stage:

SNOMED codes

T:

M:

Appendix B RCPATH dataset for histopathological reporting of breast cancer surgical resections (*in situ* and invasive disease)

This section lists the items recognised as core cancer dataset fields. These have been incorporated into a recommended synoptic reporting format in Appendix A.

Surname: Forenames: Date of birth:
 Sex: Hospital: Hospital/CHI no:
 NHS no: Date of surgery: Date of report
 Authorisation: Report no: Date of receipt:
 Pathologist: Surgeon:

Surgical specimen(s)

Is there a history of neo-adjuvant therapy?* Yes No Not known
 Side:* Right Left
 Specimen type: *
 WLE Excision biopsy Localisation specimen Segmental excision
 Mastectomy Subcutaneous mastectomy
 Re-excision Further margins (including cavity shaves/bed biopsies)
 Microdochestomy/microductectomy
 SLN Axillary sampling Axillary LN level I
 Axillary LN level II Axillary LN level III Total duct excision/Hadfield's procedure
 Other

Specimen weight (g)

Malignant lesions

Malignant *in situ* lesion:

In situ components:

DCIS grade:* High Intermediate Low Cannot be assessed
 DCIS/pleomorphic or DCIS like LCIS size mm:
 LCIS: Present Not identified
 Paget's disease: Present Not identified Cannot be assessed
 Microinvasive: Present Not identified

Invasive carcinoma

Size and extent

Invasive tumour size (mm): *
 Whole tumour (invasive + DCIS) size (mm): *
 Disease extent:* Localised Multiple invasive foci Cannot be assessed

Invasive tumour type* Pure (tick one box below) Mixed (tick all components present below)
Tubular/cribriform Lobular Mucinous Medullary-like Ductal/NST Micropapillary
Other Other type/component:

Histological grade* 1 2 3 Cannot be assessed

Lymphovascular invasion* Present Not identified Uncertain

Lymph node stage

Axillary nodes:

Total present:

Total positive:

For single node positive: Macrometastasis Micrometastasis ITCs

(Note ITCs only classified as node negative)

Other nodes: Site:

Total present: *

Total positive: *

For single node positive: Macrometastasis Micrometastasis ITCs

(Note ITCs only classified as node negative)

Summary lymph node stage: 1 = Node negative 2 = 1–3 nodes positive

3 = 4 or more nodes positive

Modifications for post neoadjuvant therapy cases (replacing above)

Residual tumour size and extent

Residual invasive tumour size (mm): *

Whole residual tumour (invasive + DCIS) size (mm): *

Residual disease extent:* Localised residual tumour Multiple residual invasive foci
Cannot be assessed

Residual invasive tumour type*

Pure (tick one box below)

Mixed (tick all components present below) Not applicable (no residual invasive tumour)

Tubular/cribriform Lobular Mucinous Medullary-like Ductal/NST Micropapillary

Other Other type/component:

Residual tumour histological grade:* 1 2 3 Cannot be assessed

Residual *in situ* components:

DCIS: Present Absent

DCIS grade:* High Intermediate Low Cannot be assessed

DCIS/pleomorphic or DCIS like LCIS size mm:

LCIS: Present Not identified

Paget's disease: Present Not identified Cannot be assessed

Microinvasive: Present Not identified

Lymphovascular invasion* Present Not identified Uncertain

Post therapy lymph node stage

Axillary nodes:

Total present:*

Total positive:*

Other nodes: Site:

Total present:

Total positive:.....

Evidence of treatment response in the metastases: Present Not identified

Number of lymph nodes with evidence of treatment response (fibrosis or histiocytic infiltrate) but no tumour cells:

Final classification of chemotherapy response

Breast disease response:

1. Complete pathological response, either (i) no residual carcinoma or (ii) no residual invasive tumour but DCIS present
2. Partial response to therapy
 - a. minimal residual disease/near total effect typically (<10% of tumour remaining in the tumour bed seen as an area of residual fibrosis delineating the original tumour extent)
 - b. Evidence of response but significant tumour remaining (>10% of tumour remaining in the tumour bed seen as an area of residual fibrosis delineating the original tumour extent)
3. No evidence of response to therapy

Lymph nodal response:

1. No evidence of metastatic disease and no evidence of changes in the lymph nodes
2. Metastatic tumour not detected but evidence of response/'down-staging', e.g. fibrosis
3. Metastatic disease present but also evidence of response, such as nodal fibrosis
4. Metastatic disease present with no evidence of response to therapy

TNM stage:

See Appendix D for relevant codes

Note: Add suffix 'y' to TNM codes for post neoadjuvant therapy treated cases.

Excision status

Excision margins:* Involved Not involved

Distance from each margin (mm) *

Invasive tumour Superior..... Inferior Medial Lateral
Deep Superficial Nipple Margin.....

DCIS/pleomorphic and DCIS like LCIS Superior Inferior..... Medial
Lateral
Deep Superficial Nipple Margin

Receptor status

Oestrogen receptor status:* Positive (> or = 1%) Negative (<1%)

% positive tumour cells =.....

On-slide positive control material: Present Absent

HER2 IHC score:* 0 Negative 1+ Negative 2+ Borderline 3+ Positive

FISH/CISH ratio:

Status:* Amplified Non-amplified Borderline Not performed

HER2 copy no: Chromosome 17 no:

Final HER2 status:* Positive Negative

SNOMED codes*

T:

M:

* Data items which are currently part of the Cancer Outcomes and Services Dataset (COSD) version 6.

Appendix C RCPATH proforma in list format

Element name	Values	Implementation comments
Is there a history of neo-adjuvant therapy?	Single selection value list: <ul style="list-style-type: none"> • Yes • No • Not known 	
Side	Single selection value list: <ul style="list-style-type: none"> • Right • Left 	
Specimen type	Multiple selection value list: <ul style="list-style-type: none"> • WLE • Excision biopsy • Localisation specimen • Segmental excision • Mastectomy • Subcutaneous mastectomy • Re-excision • Further margins (including cavity shaves/bed biopsies) • Microdochectomy/microductectomy • SLN • Axillary sampling • Axillary LN level I • Axillary LN level II • Axillary LN level III • Total duct excision/Hadfield's procedure • Other 	
Specimen type, other (specify)	Free text	Only applicable if 'Specimen type, Other' selected
Specimen weight	Weight in g	
DCIS grade	Single selection value list: <ul style="list-style-type: none"> • High • Intermediate • Low • Cannot be assessed 	
DCIS/pleomorphic or DCIS like LCIS size	Size in mm	
LCIS	Single selection value list: <ul style="list-style-type: none"> • Present • Not identified 	
Paget's disease	Single selection value list: <ul style="list-style-type: none"> • Present • Not identified • Cannot be assessed 	
Microinvasive	Single selection value list: <ul style="list-style-type: none"> • Present • Not identified 	
Invasive tumour size	Size in mm	
Whole tumour (invasive + DCIS) size	Size in mm	

Disease extent	Single selection value list: <ul style="list-style-type: none"> • Localised • Multiple invasive foci • Cannot be assessed 	
Invasive tumour type	Single selection value list: <ul style="list-style-type: none"> • Pure • Mixed 	
Invasive tumour type, components	Multiple selection value list: <ul style="list-style-type: none"> • Tubular/cribriform • Lobular • Mucinous • Medullary-like • Ductal/NST • Micropapillary • Other 	Single selection value list if 'Pure' selected for invasive tumour type
Invasive tumour type, components, other	Free text	Only applicable if 'Invasive tumour type, components Other' selected.
Histological grade	Single selection value list: <ul style="list-style-type: none"> • 1 • 2 • 3 • Cannot be assessed 	
Lymphovascular invasion	Single selection value list: <ul style="list-style-type: none"> • Present • Not identified • Uncertain 	
Axillary nodes, total present	Integer	
Axillary nodes, total positive	Integer	
Axillary nodes, for single node positive	Single selection value list: <ul style="list-style-type: none"> • Macrometastasis • Micrometastasis • ITCs • Not applicable 	Macrometastasis and micrometastasis only selectable if 'Axillary nodes, total positive = 1'. ITCs only selectable if 'Axillary nodes, total positive = 0'.
Other nodes, site	Free text	
Other nodes, total present	Integer	
Other nodes, total positive	Integer	
Other nodes, for single node positive	Single selection value list: <ul style="list-style-type: none"> • Macrometastasis • Micrometastasis • ITCs • Not applicable 	Macrometastasis and micrometastasis only selectable if 'Other nodes, total positive = 1'. ITCs only selectable if 'Other nodes, total positive = 0'.
Summary lymph node stage	Single selection value list: <ul style="list-style-type: none"> • 1 • 2 • 3 	
Residual invasive tumour size	Size in mm	
Whole residual tumour (invasive + DCIS) size	Size in mm	

Residual disease extent	Single selection value list: <ul style="list-style-type: none"> • Localised residual tumour • Multiple residual invasive foci • Cannot be assessed 	
Residual invasive tumour type	Single selection value list: <ul style="list-style-type: none"> • Pure • Mixed • Not applicable (no residual invasive tumour) 	
Residual invasive tumour type, components	Multiple selection value list: <ul style="list-style-type: none"> • Tubular/cribriform • Lobular • Mucinous • Medullary-like • Ductal/NST • Micropapillary • Other • Not applicable 	Single selection value list if 'Pure' selected for residual invasive tumour type. Not applicable if 'Residual invasive tumour type' is 'Not applicable'.
Residual invasive tumour type, components, other	Free text	Only applicable if 'Residual invasive tumour type, components Other' selected.
Residual tumour histological grade	Single selection value list: <ul style="list-style-type: none"> • 1 • 2 • 3 • Cannot be assessed 	
Residual DCIS	Single selection value list: <ul style="list-style-type: none"> • Present • Absent 	
Residual DCIS grade	Single selection value list: <ul style="list-style-type: none"> • High • Intermediate • Low • Cannot be assessed 	
Residual DCIS/pleomorphic or DCIS like LCIS size	Size in mm	
Residual LCIS	Single selection value list: <ul style="list-style-type: none"> • Present • Not identified 	
Residual Paget's disease	Single selection value list: <ul style="list-style-type: none"> • Present • Not identified • Cannot be assessed 	
Residual microinvasive	Single selection value list: <ul style="list-style-type: none"> • Present • Not identified 	
Residual lymphovascular invasion	Single selection value list: <ul style="list-style-type: none"> • Present • Not identified • Uncertain 	
Post therapy axillary nodes, total present	Integer	
Post therapy axillary nodes, total positive	Integer	

Post therapy axillary nodes, for single node positive	Single selection value list: <ul style="list-style-type: none"> • Macrometastasis • Micrometastasis • ITCs • Not applicable 	Macrometastasis and micrometastasis only selectable if 'Post therapy axillary nodes, total positive = 1'. ITCs only selectable if 'Post therapy axillary nodes, total positive = 0'.
Post therapy other nodes, site	Free text	
Post therapy other nodes, total present	Integer	
Other nodes, Total positive	Integer	
Other nodes, largest tumour deposit	Single selection value list: <ul style="list-style-type: none"> • Macrometastasis • Micrometastasis • ITCs 	
Evidence of treatment response in metastases	Single selection value list: <ul style="list-style-type: none"> • Present • Not identified 	
Number of lymph nodes or with evidence of treatment response (fibrosis or histiocytic infiltrate) but no tumour cells	Integer	
Breast disease response	Single selection value list: <ul style="list-style-type: none"> • 1 • 2a • 2b • 3 	
Lymph nodal response	Single selection value list: <ul style="list-style-type: none"> • 1 • 2 • 3 • 4 	
T stage	Single selection value list: <ul style="list-style-type: none"> • TX • T0 • Tis (DCIS) • Tis (LCIS) • Tis (Paget's) • T1mi • T1a • T1b • T1c • T2 • T3 • T4a • T4b • T4c • T4d • pTX • pT0 • pTis (DCIS) • pTis (LCIS) • pTis (Paget's) • ypT1mi 	

	<ul style="list-style-type: none"> • ypT1a • ypT1b • ypT1c • ypT2 • ypT3 • ypT4a • ypT4b • ypT4c • ypT4d 	
N stage	<p>Single selection value list:</p> <ul style="list-style-type: none"> • pNX • pN0 • pN0(i-) • pN0(i+) • pN0(mol-) • pN0(mol+) • pN1mi • pN1a • pN1b • pN1c • pN2a • pN2b • pN3a • pN3b • pN3c • ypNX • ypN0 • ypN0(i-) • ypN0(i+) • ypN0(mol-) • ypN0(mol+) • ypN1mi • ypN1a • ypN1b • pN1c • pN2a • pN2b • pN3a • pN3b • pN3c 	
M stage	<p>Single selection value list:</p> <ul style="list-style-type: none"> • pM0 • cM0(i+) • M1 	
Excision margins	<p>Single selection value list:</p> <ul style="list-style-type: none"> • Involved • Distance from each margin 	
Distance from superior margin, invasive tumour	Distance in mm	
Distance from inferior margin, invasive tumour	Distance in mm	

Distance from medial margin, invasive tumour	Distance in mm	
Distance from lateral margin, invasive tumour	Distance in mm	
Distance from deep margin, invasive tumour	Distance in mm	
Distance from superficial margin, invasive tumour	Distance in mm	
Distance from nipple margin, invasive tumour	Distance in mm	
Distance from superior margin, DCIS/pleomorphic and DCIS like LCIS	Distance in mm	
Distance from inferior margin, DCIS/pleomorphic and DCIS like LCIS	Distance in mm	
Distance from medial margin, DCIS/pleomorphic and DCIS like LCIS	Distance in mm	
Distance from lateral margin, DCIS/pleomorphic and DCIS like LCIS	Distance in mm	
Distance from deep margin, DCIS/pleomorphic and DCIS like LCIS	Distance in mm	
Distance from superficial margin, DCIS/pleomorphic and DCIS like LCIS	Distance in mm	
Distance from nipple margin, DCIS/pleomorphic and DCIS like LCIS	Distance in mm	
Oestrogen receptor status	Single selection value list: <ul style="list-style-type: none"> • Positive • Negative 	
Oestrogen receptor, positive tumour cells	Number (0–100)	
On-slide positive control material	Single selection value list: <ul style="list-style-type: none"> • Present • Absent 	
HER2 IHC score	Single selection value list: <ul style="list-style-type: none"> • 0 Negative • 1+ Negative • 2+ Borderline • 3+ Positive 	
FISH/CISH ratio	Free text	
HER2 status	Single selection value list: <ul style="list-style-type: none"> • Amplified • Non-amplified • Borderline • Not performed 	
HER2 copy number	Number	
Chromosome 17 number	Number	
Final HER2 status	Single selection value list: <ul style="list-style-type: none"> • Positive • Negative 	
SNOMED Topography code	May have multiple codes. Look up from SNOMED tables.	
SNOMED Morphology code	May have multiple codes. Look up from SNOMED tables.	

Appendix D TNM classification of tumours of the breast

1. Primary tumour (T)

Designation should be made with the subscript 'c' or 'p' modifier to indicate whether the T classification was determined by clinical (physical examination or radiological) or pathological measurements, respectively

If the tumour size is slightly less than or greater than a cut-off for a given T classification, it is recommended that the size be rounded to the millimetre reading that is closest to the cut-off, e.g. size of 1.1 mm is reported as 1 mm, or a size of 2.01 cm is reported as 2.0 cm.

TX	Primary tumour cannot be assessed
T0	No evidence of primary tumour
Tis	Carcinoma <i>in situ</i>
Tis (DCIS)	DCIS
Tis (LCIS)	LCIS
Tis (Paget's)	<p>Paget's disease of the nipple NOT associated with invasive carcinoma and/or carcinoma <i>in situ</i> (DCIS and/or LCIS) in the underlying breast parenchyma.</p> <p>Carcinomas in the breast parenchyma associated with Paget's disease are categorised based on the size and characteristics of the parenchymal disease, but presence of Paget disease should still be noted</p>
T1	Tumour ≤20 mm in greatest dimension
T1mi	Tumour ≤1 mm in greatest dimension
T1a	Tumour >1 mm but ≤5 mm in greatest dimension
T1b	Tumour >5 mm but ≤10 mm in greatest dimension
T1c	Tumour >10 mm but ≤20 mm in greatest dimension
T2	Tumour >20 mm but ≤50 mm in greatest dimension
T3	Tumour >50 mm in greatest dimension
T4	Tumour of any size with direct extension to the chest wall and/or to the skin (ulceration or skin nodules) <i>[NB. Invasion of the dermis alone does not qualify as T4]</i>
T4a	Extension to the chest wall, not including only pectoralis muscle adherence/invasion.
T4b	Ulceration and/or ipsilateral satellite nodules and/or oedema (including peau d'orange) of the skin, which do not meet the criteria for inflammatory carcinoma.
T4c	Both T4a and T4b
T4d	Inflammatory carcinoma

2. Nodes (pN)

Classification is based on axillary lymph node dissection with or without sentinel lymph node biopsy. Classification based solely on sentinel lymph node biopsy without subsequent axillary lymph node dissection is designated (SN) for 'sentinel node,' for example, pN0(SN)

pNX	Regional lymph nodes cannot be assessed (e.g. previously removed or not removed for histological assessment)
pN0	No regional lymph node metastasis identified histologically
NB: ITCs are defined as small clusters of cells ≤ 0.2 mm, or single tumour cells, or a cluster of < 200 cells in a single histologic cross-section. ITCs may be detected by routine H&E or by IHC. Nodes containing only ITCs are excluded from the total positive node count for purposes of N classification but should be included in the total number of nodes evaluated.	
pN0(i-)	No regional lymph node metastases histologically, negative IHC
pN0(i+)	Malignant cells in regional lymph node(s) ≤ 0.2 mm (detected by H&E or IHC including ITC).
pN0(mol-)	No regional lymph node metastases histologically, negative molecular findings (RT-PCR).
pN0(mol+)	Positive molecular findings (RT-PCR), but no regional lymph node metastases detected by histology or IHC.
pN1	Micrometastases OR
	Metastases in 1–3 axillary lymph nodes AND/OR
	Metastases in internal mammary nodes with metastases detected by sentinel lymph node biopsy but not clinically detected
pN1mi	Micrometastases (> 0.2 mm and/or > 200 cells but none > 2.0 mm)
pN1a	Metastases in 1–3 axillary lymph nodes, at least one metastasis > 2.0 mm
pN1b	Metastases in internal mammary nodes with micrometastases or macrometastases detected by sentinel lymph node biopsy but not clinically detected
pN1c	Metastases in 1–3 axillary lymph nodes and in internal mammary lymph nodes with micrometastases or macrometastases detected by sentinel lymph node biopsy but not clinically detected
pN2	Metastases in 4–9 axillary lymph nodes OR
	Metastases in clinically detected internal mammary lymph nodes in the absence of axillary lymph node metastases.
pN2a	Metastases in 4–9 axillary lymph nodes (at least 1 deposit > 2 mm)
pN2b	Metastases in clinically detected internal mammary lymph nodes in the <i>absence</i> of axillary lymph node metastases
pN3	Metastases in ≥ 10 axillary lymph nodes OR
	Metastases in infraclavicular (level III axillary) lymph nodes OR
	Metastases in clinically detected ipsilateral internal mammary lymph nodes in the presence of one or more positive level I, II axillary lymph nodes OR
	Metastases in > 3 axillary lymph nodes and in internal mammary lymph nodes with micrometastases or macrometastases detected by sentinel lymph node biopsy but not clinically detected OR
	Metastases in ipsilateral supraclavicular lymph nodes.

pN3a	Metastases in ≥ 10 axillary lymph nodes (at least 1 tumour deposit > 2.0 mm) OR
	Metastases in the infraclavicular (level III axillary lymph) nodes.
pN3b	Metastases in clinically detected ipsilateral internal mammary lymph nodes in the <i>presence</i> of one or more positive axillary lymph nodes OR
	Metastases in > 3 axillary lymph nodes and in internal mammary lymph nodes with micrometastases or macrometastases detected by sentinel lymph node biopsy but not clinically detected.
pN3c	Metastases in ipsilateral supraclavicular lymph nodes.
Post-treatment ypN	
– Post-treatment yp ‘N’ should be evaluated as for clinical (pre-treatment) ‘N’ methods above. The modifier ‘SN’ is used only if a sentinel node evaluation was performed after treatment. If no subscript is attached, it is assumed that the axillary nodal evaluation was by ALND.	
–The X classification should be used (ypNX) if no yp post-treatment SN or ALND was performed	
–N categories are the same as those used for pN	

Distant metastases (M)

This is generally not assessable by the pathologist and cannot therefore be included on surgical specimen histology reports.

M0	No clinical or radiological evidence of distant metastases.
cM0(i+)	No clinical or radiological evidence of distant metastases, but deposits of molecularly or microscopically detected tumour cells in circulating blood, bone marrow, or other non-regional nodal tissue that are ≤ 0.2 mm in a patient without symptoms or signs of metastases
M1	Distant detectable metastases as determined by classic clinical and radiographic means and/or histologically proven > 0.2 mm

Post-treatment yp M classification

The M category for patients treated with neoadjuvant therapy is the category assigned in the clinical stage, prior to initiation of neoadjuvant therapy. Identification of distant metastases after the start of therapy in cases where pre-therapy evaluation showed no metastases is considered progression of disease. If a patient was designated to have detectable distant metastases (M1) before chemotherapy, the patient will be designated as M1 throughout.

Helpful rules of thumb for TNM stage

In the case of multiple simultaneous tumours in one organ, the tumour with the highest T category should be classified and the multiplicity or the number of tumours should be indicated in parentheses, e.g. T2(m) or T2(5). In simultaneous bilateral cancers of paired organs, each tumour should be classified independently.

If there is doubt concerning the correct T, N, or M category to which a particular case should be allotted, then the lower (i.e., less advanced) category should be chosen. This will also be reflected in the stage grouping.

Anatomic stage/prognostic groups

*T0 and T1 tumours with nodal micrometastases only are excluded from Stage IIA and are classified Stage IB.

- M0 includes M0(i+)
- The designation pM0 is not valid; any M0 should be clinical
- If a patient presents with M1 prior to neoadjuvant systemic therapy, the stage is considered Stage IV and remains Stage IV regardless of response to neoadjuvant therapy
- Post-neoadjuvant therapy is designated with 'yc' or 'yp' prefix.

Of note, no stage group is assigned if there is a complete pathological response (pCR) to neoadjuvant therapy, e.g. ypT0ypN0cM0.

Stage	T	N	M
0	Tis	N0	M0
IA	T1 (includes T1mi)	N0	M0
IB	T0	N1mi	M0
	T1 (includes T1mi)	N1mi	M0
IIA	T0	N1*	M0
	T1 (includes T1mi)	N1*	M0
	T2	N0	M0
IIB	T2	N1	M0
	T3	N0	M0
IIIA	T0	N2	M0
	T1 (includes T1mi)	N2	M0
	T2	N2	M0
	T3	N1	M0
	T3	N2	M0
IIIB	T4	N0	M0
	T4	N1	M0
	T4	N2	M0
IIIC	Any T	N3	M0
IV	Any T	Any N	M1

References

1. Breast. In: Edge S, Byrd DR, Compton CC, Fritz AG, Greene FL, Trotti A (Eds.). *AJCC Cancer Staging Manual (7th ed)*. New York, NY: Springer, 2010.
2. Singletary SE, Allred C, Ashley P, Bassett LW, Berry D, Bland KI *et al*. Revision of the American Joint Committee on Cancer staging system for breast cancer. *J Clin Oncol* 2002;20:3628–3636.
3. Woodward WA, Strom EA, Tucker SL, McNeese MD, Perkins GH, Schechter NR *et al*. Changes in the 2003 American Joint Committee on Cancer staging for breast cancer dramatically affect stage-specific survival. *J Clin Oncol* 2003;21:3244–3248.

Appendix E Recommended SNOMED codes for breast pathology

Neoplasms

The following are SNOMED3 equivalents of the ICD-O codes that are recognised internationally. Codes with a * are proposed codes that have not formally been included in ICD-O yet.

The licensing rights to SNOMED are held by IHTSDO.

Morphological codes	SNOMED code	SNOMED CT terminology	SNOMED CT code
Adenocarcinoma NOS	M-81403	Adenocarcinoma, no subtype (morphologic abnormality)	35917007
Adenoid cystic carcinoma	M-82003	Adenoid cystic carcinoma (morphologic abnormality)	11671000
Adenoma of nipple	M-85060	Adenoma of the nipple (morphologic abnormality)	65787003
Adenomyoepithelioma (benign)	M-89830	Adenomyoepithelioma (morphologic abnormality)	128765009
Adenomyoepithelioma (malignant)	M-89833*	Adenomyoepithelioma with carcinoma (morphologic abnormality)	703644009
Angiosarcoma	M-91203	Haemangiosarcoma (morphologic abnormality)	39000009
Apocrine carcinoma	M-85733	Adenocarcinoma with apocrine metaplasia (morphologic abnormality)	22694002
Atypical medullary carcinoma	M-85133	Atypical medullary carcinoma (morphologic abnormality)	128698005
Carcinoma with osteoclast-like giant cells	M-80353	Carcinoma with osteoclast-like giant cells (morphologic abnormality)	128631001
Cribriform carcinoma	M-82013	Cribriform carcinoma (morphologic abnormality)	30156004
DCIS	M-85002	Intraductal carcinoma, noninfiltrating, no International Classification of Diseases for Oncology (ICDO) subtype (morphologic abnormality)	86616005
Ductal adenoma	M-85030	Intraductal papilloma (morphologic abnormality)	5244003
Ductal carcinoma/NST	M-85003	Infiltrating duct carcinoma (morphologic abnormality)	82711006
Encysted papillary carcinoma	M-85042	Noninfiltrating intracystic carcinoma (morphologic abnormality)	89277004
Fibroadenoma	M-90100	Fibroadenoma, no ICDO subtype (morphologic abnormality)	65877006
Fibroadenoma juvenile	M-90300	Juvenile fibroadenoma (morphologic abnormality)	46212000
Fibromatosis-like carcinoma	M-85723	Adenocarcinoma with spindle cell metaplasia (morphologic abnormality)	68358000

Granular cell tumour	M-95800	Granular cell tumour (morphologic abnormality)	12169001
Haemangioma	M-91200	Haemangioma, no ICDO subtype (morphologic abnormality)	2099007
Hamartoma	M-90203	Phyllodes tumour, malignant (morphologic abnormality)	87913009
Inflammatory carcinoma	M-85303	Inflammatory carcinoma (morphologic abnormality)	32968003
Intraductal papilloma	M-85030	Intraductal papilloma (morphologic abnormality)	5244003
Intraductal papilloma with DCIS	M-85032	Noninfiltrating intraductal papillary adenocarcinoma (morphologic abnormality)	30566004
Invasive micropapillary carcinoma	M-85073*	Invasive micropapillary carcinoma of breast (morphologic abnormality)	703578005
Invasive papillary carcinoma	M-85033	Intraductal papillary adenocarcinoma with invasion (morphologic abnormality)	64524002
LCIS	M-85202	Lobular carcinoma <i>in situ</i> (morphologic abnormality)	77284006
Lipoma	M-88500	Lipoma, no ICDO subtype (morphologic abnormality)	46720004
Lobular carcinoma	M-85203	Lobular carcinoma (morphologic abnormality)	89740008
Low-grade adenosquamous carcinoma	M-85703	Adenocarcinoma with squamous metaplasia (morphologic abnormality)	15176003
Lymphoma NOS	M-95903	Malignant lymphoma, no ICDO subtype (morphologic abnormality)	21964009
Medullary carcinoma	M-85103	Medullary carcinoma (morphologic abnormality)	32913002
Metaplastic carcinoma NOS	M-85753	Metaplastic carcinoma (morphologic abnormality)	128705006
Metastatic carcinoma	M-80106	Carcinoma, metastatic (morphologic abnormality)	79282002
Mixed carcinoma	Specify subtypes		
Mucinous carcinoma	M-84803	Mucinous adenocarcinoma (morphologic abnormality)	72495009
Myoepithelial carcinoma	M-89823	Malignant myoepithelioma (morphologic abnormality)	128884000
Myofibroblastoma	M-88250	Myofibroblastoma (morphologic abnormality)	128738002
Neuroendocrine carcinoma (poorly differentiated)	M-80413	Small cell carcinoma (morphologic abnormality)	74364000

Neuroendocrine carcinoma (well differentiated)	M-82463	Neuroendocrine carcinoma (morphologic abnormality)	55937004
Nodular fasciitis	M-88280*	Nodular fasciitis (morphologic abnormality)	703616008
Paget's disease of nipple	M-85403	Paget's disease, mammary (morphologic abnormality)	2985005
Papillary carcinoma <i>in situ</i>	M-85032	Noninfiltrating intraductal papillary adenocarcinoma (morphologic abnormality)	30566004
Papilloma multiple	M-85050	Intraductal papillomatosis (morphologic abnormality)	32296002
Phyllodes benign	M-90200	Phyllodes tumour, benign (morphologic abnormality)	16566002
Phyllodes malignant	M-90203	Phyllodes tumour, malignant (morphologic abnormality)	87913009
Phyllodes borderline	M-90201	Phyllodes tumour, borderline (morphologic abnormality)	71232009
Pleomorphic carcinoma	M-80223	Pleomorphic carcinoma (morphologic abnormality)	16741004
Pleomorphic LCIS	M-85192*	Pleomorphic lobular carcinoma <i>in situ</i> (morphologic abnormality)	444591006
Secretory carcinoma	M-85023	Juvenile carcinoma of the breast (morphologic abnormality)	41919003
Signet ring carcinoma	M-84903	Signet ring cell carcinoma (morphologic abnormality)	87737001
Spindle cell carcinoma	M-80323	Spindle cell carcinoma (morphologic abnormality)	65692009
Squamous cell carcinoma	M-80703	Squamous cell carcinoma, no ICDO subtype (morphologic abnormality)	28899001
Syringomatous adenoma of nipple	M-84070	Syringoma (morphologic abnormality)	71244007
Tubular adenoma	M-82110	Tubular adenoma, no ICDO subtype (morphologic abnormality)	19665009
Tubular carcinoma	M-82113	Tubular adenocarcinoma (morphologic abnormality)	4631006
Undifferentiated carcinoma	M-80203	Carcinoma, undifferentiated (morphologic abnormality)	38549000

Other conditions

Term	SNOMED code	SNOMED CT terminology	SNOMED CT code
Abscess	M-41610	Abscess (morphologic abnormality)	44132006
Accessory/ectopic breast	D4-48012	Accessory breast (disorder)	18166000
Apocrine metaplasia	M-73310	Apocrine metaplasia (morphologic abnormality)	81274009
Atypical apocrine hyperplasia	M-73315	Atypical apocrine metaplasia (morphologic abnormality)	103673004
Atypical ductal hyperplasia	M-72175	Atypical intraductal hyperplasia (morphologic abnormality)	6660000
Atypical lobular hyperplasia	M-72105	Atypical lobular hyperplasia (morphologic abnormality)	33889003
Calcification	M-55400	Calcified structure (morphologic abnormality)	54497001
Collagenous spherulosis	M-72171	Collagenous spherulosis (morphologic abnormality)	447298005
Columnar cell atypia	M-67020	Columnar cell atypia (morphologic abnormality)	55465005
Columnar cell lesions	M-74240	Blunt duct adenosis (morphologic abnormality)	58811002
Complex sclerosing lesion	M-78731	Radial scar (morphologic abnormality)	133855003
Cyst NOS	M-33400	Cyst (morphologic abnormality)	12494005
Duct ectasia	M-32100	Duct ectasia (morphologic abnormality)	110420004
Epithelial hyperplasia without atypia	M-72170	Intraductal hyperplasia (morphologic abnormality)	67617000
Excision margins tumour free	M-09400	Surgical margin uninvolved by tumour (finding)	55182004
Fat necrosis	M-54110	Fat necrosis (morphologic abnormality)	79682009
Fibrocystic change	M-74320	Fibrocystic disease (morphologic abnormality)	28092006
Fibromatosis	M-76100	Angiomatosis (morphologic abnormality)	14350002
Fistula	M-39300	Acquired fistula (morphologic abnormality)	51711001
Foreign body reaction	M-44140	Foreign body giant cell granuloma (morphologic abnormality)	37058002
Galactocoele	M-33220	Galactocoele associated with childbirth (disorder)	87840008
Gynaecomastia	M-71000	Hypertrophy (morphologic abnormality)	56246009
Infarction	M-54700	Infarct (morphologic abnormality)	55641003
Inflammation acute	M-41000	Acute inflammation (morphologic abnormality)	4532008

Inflammation chronic	M-43000	Chronic inflammation (morphologic abnormality)	84499006
Inflammation granulomatous	M-44000	Granulomatous inflammation (morphologic abnormality)	6266001
Involucional change	M-79140	Menstrual involution of breast (morphologic abnormality)	33429008
Juvenile hypertrophy	D7-90404	Pubertal breast hypertrophy (disorder)	198113009
Lactational change	M-82040	Lactating adenoma (morphologic abnormality)	128651002
Metaplasia atypical	M-73005	Atypical metaplasia (morphologic abnormality)	125544002
Metaplasia chondroid	M-73600	Cartilaginous metaplasia (morphologic abnormality)	112671001
Metaplasia epithelial (clear cell, etc)	M-73200	Epithelial metaplasia (morphologic abnormality)	54725001
Metaplasia osseous	M-73400	Osseous metaplasia (morphologic abnormality)	38109001
Metaplasia squamous	M-73220	Squamous metaplasia (morphologic abnormality)	83577005
Microglandular adenosis	M-72480	Microglandular hyperplasia (morphologic abnormality)	2953007
Microglandular hyperplasia	M-72450	Adenofibromyomatous hyperplasia (morphologic abnormality)	88000003
Morphological description only	M-09350	Morphologic description only (finding)	85728002
Mucocoele-like lesion	M-33440	Mucous cyst (morphologic abnormality)	19633006
Normal: NOS	M-00100	Normal tissue (finding)	30389008
PASH	M-72430	Stromal hyperplasia (morphologic abnormality)	75235002
Plasma cell mastitis	M-43060	Plasma cell inflammation (morphologic abnormality)	26246006
Pregnancy	M-68080	Pregnancy pattern (morphologic abnormality)	68737009
Radial scar	M-78731	Radial scar (morphologic abnormality)	133855003
Radiotherapy effect	M-11600	Radiation injury (morphologic abnormality)	81018009
Sclerosing adenosis	M-74220	Fibrosing adenosis (morphologic abnormality)	50916005
Surgical wound or cavity	M-14020	Surgical wound (morphologic abnormality)	112633009
Weddelite	M-55400	Calcified structure (morphologic abnormality)	54497001

Appendix F Index for screening NHSBSP office pathology system

Term	Place to classify on form
Abscess	Other benign pathology (specify)
Adenocarcinoma (no special type)	Invasive ductal NST
Adenoid cystic carcinoma	Other primary carcinoma (specify)
Adenoma, apocrine	Other benign pathology (specify)
Adenoma intraduct	Enter as papilloma
Adenoma of nipple	Other benign pathology (specify)
Adenoma, pleomorphic	Other benign pathology (specify)
Adenoma, tubular	Fibroadenoma
Adenomyoepithelioma benign	Other benign pathology (specify)
Adenomyoepithelioma malignant	Other primary carcinoma (specify)
Adenosis, NOS	Histology normal
Adenosis, apocrine	Other benign pathology (specify)
Adenosis, apocrine (atypical)	Other benign pathology (specify), epithelial proliferation atypia (ductal)
Adenosis, blunt duct	Columnar cell change
Adenosis, microglandular	Other benign pathology (specify)
Adenosis, sclerosing with atypia	Sclerosing adenosis, epithelial proliferation atypia (ductal or lobular)
Adnexal tumours	Other benign pathology (specify)
Alveolar variant of lobular carcinoma	Invasive lobular
Aneurysm	Other benign pathology (specify)
Angiosarcoma	Other malignant tumour (specify)
Apocrine adenoma	Other benign pathology (specify)
Apocrine adenosis	Other benign pathology (specify)
Apocrine carcinoma (<i>in situ</i>)	Non-invasive malignant, ductal (specify)
Apocrine carcinoma (invasive)	Other primary carcinoma (if pure) or ductal NST
Apocrine metaplasia (multilayered/papillary)	Fibrocystic change Epithelial proliferation present without atypia
Argyrophil carcinoma	Other primary carcinoma (specify)
Arteritis	Other benign pathology (specify)
Atypical blunt duct adenosis	Epithelial proliferation, atypia (ductal)
Atypical ductal hyperplasia	Epithelial proliferation, atypia (ductal)
Atypical lobular hyperplasia	Epithelial proliferation, atypia (lobular)
B-cell lymphoma	Other malignant tumour (specify)
Benign phyllodes tumour	Other benign pathology (specify)
Blunt duct adenosis	Columnar cell change
Breast abscess	Other benign pathology (specify)
Calcification (benign)	Calcification present, benign
Calcification (malignant)	Calcification present, malignant
Carcinoma, apocrine (<i>in situ</i>)	Non-invasive malignant, ductal (specify type)
Carcinoma, apocrine (invasive)	Other primary carcinoma (if pure) or ductal NST

Carcinoma, clear cell	Other primary carcinoma (specify)
Carcinoma, colloid	Invasive mucinous carcinoma
Carcinoma, comedo (<i>in situ</i>)	Non-invasive malignant, ductal (specify type)
Carcinoma, cribriform (<i>in situ</i>)	Non-invasive malignant, ductal (specify type)
Carcinoma, cribriform (invasive)	Invasive tubular or cribriform
Carcinoma, ductal (<i>in situ</i>)	Non-invasive malignant, ductal (specify type)
Carcinoma, lobular (<i>in situ</i>)	Non-invasive malignant, lobular
Carcinoma, lobular (invasive)	Invasive lobular
Carcinoma, lobular variant	Invasive lobular
Carcinoma, medullary	Invasive medullary like
Carcinoma, metastatic	Other malignant tumour (specify)
Carcinoma, mixed	Other primary carcinoma (specify)
Carcinoma, mucinous	Invasive mucinous carcinoma
Carcinoma, papillary	Other primary carcinoma (specify)
Carcinoma, signet ring	Other primary carcinoma (specify)
Carcinoma, spindle cell	Other primary carcinoma (specify)
Carcinoma, squamous	Other primary carcinoma (specify)
Carcinosarcoma	Other primary carcinoma (specify)
Cellular fibroadenoma	Fibroadenoma
Clear cell carcinoma	Other primary carcinoma (specify)
Clear cell hidradenoma	Other benign pathology (specify)
Clear cell metaplasia	Other benign pathology (specify)
Collagenous spherulosis	Other benign pathology (specify)
Columnar cell alteration	Columnar cell change
Columnar cell change	Columnar cell change
Columnar cell hyperplasia	Columnar cell change
Comedocarcinoma	Non-invasive malignant, ductal
Comedocarcinoma (invasive)	Invasive ductal NST
Complex sclerosing lesion	Complex sclerosing lesion/radial scar
Cribriform carcinoma (<i>in situ</i>)	Non-invasive malignant, ductal (specify type)
Cribriform carcinoma (invasive)	Invasive tubular or cribriform
Cyclical menstrual changes	Histology normal
Cyst, epidermoid	Other benign pathology (specify)
Cyst, single	Solitary cyst
Cyst, multiple	Fibrocystic change
Cystic disease	Fibrocystic change
Cystic mastopathy	Fibrocystic change
Cystic hypersecretory hyperplasia	Other benign pathology (specify)
Cystic hypersecretory carcinoma	Non-invasive malignant, ductal
Ductal carcinoma (<i>in situ</i>)	Non-invasive malignant, ductal
Ductal carcinoma (invasive)	Invasive ductal NST
Ductal hyperplasia (regular)	Epithelial proliferation present without atypia
Ductal hyperplasia (atypical)	Epithelial proliferation, atypia (ductal)
Duct ectasia	Periductal mastitis/duct ectasia

Duct papilloma	Papilloma, single
Dysplasia, mammary	Fibrocystic change
Eccrine tumours	Other benign pathology (specify)
Epidermoid cyst	Other benign pathology (specify)
Epitheliosis (regular)	Epithelial proliferation present without atypia
Epitheliosis (atypical)	Epithelial proliferation, atypia (ductal)
Epitheliosis (infiltrating)	Complex sclerosing lesion/radial scar
Fat necrosis	Other benign pathology (specify)
Fibroadenoma	Fibroadenoma
Fibroadenoma, giant	Fibroadenoma
Fibroadenoma, juvenile	Fibroadenoma
Fibrocystic disease	Fibrocystic change
Fibromatosis	Other benign pathology (specify)
Fistula, mamillary	Other benign pathology (specify)
Focal lactational change	Histology normal
Foreign body reaction	Other benign pathology (specify)
Galactocoele	Other benign pathology (specify)
Giant fibroadenoma	Fibroadenoma
Glycogen rich carcinoma	Other primary carcinoma (specify)
Granulomatous mastitis	Other benign pathology (specify)
Haematoma	Other benign pathology (specify)
Haemangioma	Other benign pathology (specify)
Hamartoma	Other benign pathology (specify)
Hyaline epithelial inclusions	Other benign pathology (specify)
Hyperplasia, ductal (regular)	Epithelial proliferation present without atypia
Hyperplasia, ductal (atypical)	Epithelial proliferation, atypia (ductal)
Hyperplasia, lobular (atypical)	Epithelial proliferation, atypia (lobular)
Infarct	Other benign pathology (specify)
Inflammatory carcinoma	Specify by type (usually ductal NST)
Invasive carcinoma	Specify by type
Invasive comedocarcinoma	Invasive ductal NST
Invasive cribriform carcinoma	Invasive tubular or cribriform
Involution	Histology normal
Juvenile fibroadenoma	Fibroadenoma
Juvenile papillomatosis	Other benign pathology (specify)
Lactation	Histology normal
Lactational change, focal	Histology normal
Lipoma	Other benign pathology (specify)
Lipid rich carcinoma	Other primary carcinoma (specify)
Lobular carcinoma (<i>in situ</i>)	Non-invasive malignant, lobular
Lobular carcinoma (invasive)	Invasive lobular
Lobular hyperplasia (atypical)	Epithelial proliferation, atypia (lobular)
Lymphoma	Other malignant tumour (specify)
Malignant phyllodes tumour	Other malignant tumour (specify)

Mammary duct ectasia	Periductal mastitis/duct ectasia
Mamillary fistula	Other benign pathology (specify)
Mastitis, acute	Other benign pathology (specify)
Mastitis, granulomatous	Other benign pathology (specify)
Mastitis, plasma cell	Periductal mastitis/duct ectasia
Mastopathy, cystic	Fibrocystic change
Medullary carcinoma	Invasive medullary like
Menopausal changes	Histology normal
Metaplasia, apocrine (single layer)	Fibrocystic change
Metaplasia, apocrine (multilayered/papillary)	Fibrocystic change; epithelial proliferation present without atypia
Metaplasia, clear cell	Other benign pathology (specify)
Metaplasia, mucoid	Other benign pathology (specify)
Metaplasia, squamous	Other benign pathology (specify)
Metaplastic carcinoma	Other primary carcinoma (specify)
Metastatic lesion	Other malignant tumour (specify)
Microcysts	Histology normal
Microglandular adenosis	Other benign pathology (specify)
Microinvasive carcinoma	Code by <i>in situ</i> component and specify microinvasion present
Micropapillary change	Epithelial proliferation present
Mixed carcinoma	Other primary carcinoma (specify types)
Mondor's disease	Other benign pathology (specify)
Mucinous carcinoma	Invasive mucinous carcinoma
Mucocoele-like lesion	Other benign pathology (specify)
Mucoid metaplasia	Other benign pathology (specify)
Multiple papilloma syndrome	Papilloma, multiple
Multiple papilloma syndrome with atypia	Papilloma, multiple with epithelial proliferation atypia (ductal)
Myoepithelial hyperplasia	Other benign pathology (specify)
Necrosis, fat	Other benign pathology (specify)
Nipple adenoma	Other benign pathology (specify)
Nipple – Paget's disease	Non-invasive malignant, Paget's disease
Normal breast	Histology normal
Paget's disease of nipple	Non-invasive malignant, Paget's disease
Panniculitis	Other benign pathology (specify)
Papillary carcinoma (<i>in situ</i>)	Non-invasive malignant, ductal (specify type)
Papillary carcinoma (invasive)	Other primary carcinoma (specify)
Papilloma, duct	Papilloma single
Papillomatosis	Epithelial proliferation (with or without atypia)
Papillomatosis, juvenile	Other benign pathology (specify)
Papillomatosis, sclerosing	Specify under other benign pathology as adenoma of nipple
Phyllodes tumour, benign or borderline	Other benign pathology (specify)

Phyllodes tumour, malignant	Other malignant tumour (specify)
Pregnancy changes	Histology normal
Radial scar	Complex sclerosing lesion/radial scar
Regular hyperplasia	Epithelial proliferation present without atypia
Sarcoidosis	Other benign pathology (specify)
Sarcoma	Other malignant tumour (specify)
Sclerosing adenosis with atypia	Sclerosing adenosis with epithelial proliferation atypia (ductal or lobular)
Sclerosing subareolar proliferation	Specify under other benign pathology as adenoma of nipple
Squamous carcinoma	Invasive malignant, other (specify)
Squamous metaplasia	Other benign pathology (specify)
Spindle cell carcinoma	Invasive malignant, other (specify)
Scar, radial	Complex sclerosing lesion/radial scar
Trauma	Other benign pathology (specify)
Tuberculosis	Other benign pathology (specify)
Tubular adenoma	Fibroadenoma
Tubular carcinoma	Invasive tubular or cribriform
Wegener's granulomatosis	Other benign pathology (specify)

*NST, no special type

NOS, not otherwise specified

Appendix G Diagnostic immunohistochemistry of the breast

Immunohistochemistry can be a valuable adjunct to conventional histology in improving diagnostic accuracy and consistency. Marker studies should not be viewed in isolation but interpreted in the context of the appearances on conventional H&E histology.

1 Distinction between usual epithelial hyperplasia and atypical ductal hyperplasia ADH/ low-grade ductal carcinoma *in situ* (DCIS)

Epithelial hyperplasia of usual type generally shows strong but heterogeneous/mosaic staining for the high molecular weight ('basal') cytokeratin markers (e.g. CK5, CK14 and CK17) whilst ADH and DCIS are usually uniformly negative. Care should be taken not to misinterpret positivity in residual normal or hyperplastic epithelial and myoepithelial cells. The absence of positivity should not by itself be regarded as diagnostic of atypia or malignancy as many normal cells and columnar cell lesions are negative. Likewise, a small proportion of DCIS with a basal phenotype may be focally positive with basal cytokeratins. 34betaE12, which detects a common epitope on CK 1, 5, 10 and 14, is less discriminatory in this context and its use is not recommended. Oestrogen receptor staining is also useful in this context. Usual type epithelial hyperplasia will typically exhibit a heterogeneous pattern with both positively and negatively stained cells present. In contrast, the clonal luminal epithelial cell populations of ADH and low-grade DCIS typically exhibit homogeneous strong ER positivity. Note that some benign lesions such as columnar cell change may also exhibit strong uniform ER positivity and a pure luminal cell phenotype.

2 Lobular carcinoma phenotype

Expression of the cell adhesion molecule E-cadherin may be useful in distinguishing between ductal carcinoma *in situ* (DCIS) and lobular *in situ* neoplasia (ALH and LCIS) and also between invasive carcinoma of no special type and invasive lobular lesions. E cadherin exhibits a strong linear membrane pattern of staining in ductal lesions, while lobular lesions are almost always negative. Weak patchy membrane positivity may however sometimes be observed in lobular carcinomas and lobular *in situ* neoplasia (LISN). Care must be taken not to misinterpret E-cadherin positive benign epithelial and myoepithelial cells admixed with the cells of LISN. LISN admixed with usual type epithelial hyperplasia may be more easily recognised where there are clusters of cells with adjacent membranes lacking staining for E-cadherin.

Of note, some (10–20%) lobular carcinomas can be positive with E-cadherin and immunohistochemical findings must be interpreted in the context of the findings on conventional histology. Some lobular carcinomas show cytoplasmic E-cadherin positivity and some may show an aberrant pattern of staining with punctate cytoplasmic or membrane 'dot-like' positivity, particularly the pleomorphic variant. In equivocal cases p120 catenin staining may be helpful showing cytoplasmic positivity in lobular carcinomas and a membrane pattern of staining in ductal carcinomas.

3 Assessment of stromal invasion

The distinction between invasive and *in situ* disease has significant implications for patient management. Identification of a peripheral rim of enclosing myoepithelial cells confirms a tumour focus remains *in situ*, whilst the absence of a surrounding layer is strongly suggestive (although not necessarily diagnostic) of invasion. Potential attenuation or discontinuity of the myoepithelial cell layer in an *in situ* lesion should always be considered.

Common diagnostic scenarios benefitting from identification of myoepithelium include:

- a. distinction between the entrapped tubules of a radial scar and invasive tubular carcinoma

- b. distinction between invasive malignancy and *in situ* carcinoma, particularly when the latter is colonising a sclerosing lesion (e.g. sclerosing adenosis)
- c. identification of certain special types of tumour characterised by the presence of myoepithelial differentiation, e.g. low-grade adenosquamous carcinoma, adenoid cystic carcinoma, and adenomyoepithelioma.

A range of immunohistochemical markers can be used to highlight myoepithelial cells but these vary in sensitivity and specificity. Smooth muscle myosin (SMM) heavy chain is a particularly useful marker which gives strong positive staining in the cytoplasm of myoepithelial cells, although it may also highlight smooth muscle of vascular walls. Care should be taken not to misinterpret such staining, particularly when vessels are found closely applied to epithelial cell islands, for example with the fronds of a papillary lesion. SMM is only weakly expressed by stromal myofibroblasts, if at all, thus usually shows little background reactivity producing a 'clean' picture.

Other myoepithelial markers that identify antigens present in muscle, e.g. the calcium binding protein calponin, and smooth muscle actin (SMA) show greater reactivity for vascular walls and stromal myofibroblasts and therefore may be more problematic to interpret. P63 is a sensitive myoepithelial marker expressed in the nucleus. It may be expressed in a small proportion of breast cancers, especially metaplastic carcinomas in which it is often a useful marker. Staining may be discontinuous but demonstration of nuclear expression of p63 usefully complements the other cytoplasmic markers. It is important to remember that positive expression of myoepithelial markers may be seen at the periphery of islands of low-grade adenosquamous carcinoma and this does not imply *in situ* disease in this context. Cytokeratin markers, e.g. CK 7 may also occasionally be of use in highlighting the abnormal/infiltrative architecture of microinvasive or invasive disease when this is obscured by, e.g. inflammation or diathermy artefact.

4 Paget's disease of nipple versus melanoma versus carcinoma

Paget's disease of the nipple, but not intraepidermal squamous carcinoma, normal squamous epithelium or melanoma, expresses CAM5.2. CK7 is positive in almost all cases of Paget's disease but not intraepidermal squamous carcinoma or melanoma. However, care should be exercised in the interpretation of CK7 staining as Merkel cells, Toker cells and intraepithelial extensions of lactiferous duct cells may be positive with this marker. HER2 is positive in approximately 80–90% cases and is also very valuable. EMA may also be expressed in Paget's disease. HMB45 and Melan A are positive in melanoma but not Paget's disease or intraepidermal squamous carcinoma. Both markers should be used for confident diagnosis as individual sensitivity varies. S100 protein is of limited usefulness as approximately 20% of Paget's disease may be positive. Use of p63 staining is useful to exclude intraepidermal squamous cell carcinoma.

5 Spindle cell lesions

The differential diagnosis of spindle cell lesions of the breast is wide and includes a variety of benign and malignant lesions of epithelial, myoepithelial and mesenchymal origin. A detailed overview of this subject is beyond the scope of this document and the following is a brief practical guide:

The differential diagnosis of any malignant spindle cell lesion of the breast must include monophasic spindle cell (metaplastic) carcinoma as well as sarcoma including angiosarcoma (particularly if there is a history of radiotherapy exposure) and malignant phyllodes tumour. Spindle cell carcinomas may show only mild pleomorphism, especially the fibromatosis-like variant, and this diagnosis must be considered in the differential diagnosis of any breast spindle cell lesion. A wide panel of cytokeratin markers should be employed as the sensitivity of any individual marker in this context varies. Expression of luminal low molecular weight keratins (CAM5.2 and CK7) may in particular be variable and are less useful than high

molecular weight cytokeratins (CK5, CK 14). Broad spectrum cytokeratins should also be included in the panel such as MNF116 and AE1/AE3. Other useful markers include P63, which is a particularly sensitive and specific marker for spindle cell/metaplastic cell carcinoma and should always be included in the panel.

Most spindle cell lesions including metaplastic carcinoma will express vimentin. Expression of smooth muscle actin (SMA) may reflect myofibroblastic as well as smooth muscle differentiation raising the possibility of myofibroblastic proliferations including nodular fasciitis and myofibroblastoma as well as reactive fibroblastic/myofibroblastic proliferative post-FNAC or core biopsy. CD34 positivity is seen in phyllodes tumours and myofibroblastoma. Fibromatosis of the breast is usually positive for vimentin and SMA but negative for CD34 and ER. The possibility of myofibroblastoma is suggested by positive expression of ER.

6 Papillary lesions

A uniform layer of myoepithelial cells (highlighted by, for example, SMM and P63) is seen underlying the epithelium in the fibrovascular fronds in benign papillomas, whilst a myoepithelial layer is absent in the fronds in papillary carcinoma *in situ* and encysted (intracystic/encapsulated) papillary carcinoma. The latter will often not have a surrounding layer of myoepithelium at its periphery (see section 5.3). When DCIS is seen within a papilloma and in papillary carcinoma *in situ* a myoepithelial cell layer is identified at the periphery of the involved ducts although this may appear discontinuous. ADH or low-grade DCIS arising within a papilloma may be highlighted by lack of staining with CK5 and CK14, as in non-papillary lesions.

7 Basal carcinoma phenotype

A panel of makers generally including epidermal growth factor (EGFR), vimentin and the high molecular weight cytokeratins CK5 and CK14, may be used to aid identification of carcinomas with a basal-like phenotype. Such tumours are usually also ER PR and HER2 negative ('triple negative') although there is incomplete concordance between a triple negative phenotype and the basal carcinoma phenotype. Such tumours are also over-represented in patients from families with germline BRCA1 gene mutations.

8 Apocrine carcinoma phenotype.

Expression of Gross cystic disease fluid protein (GCDFP) and the androgen receptor (AR) may help confirm an apocrine phenotype. Approximately 60–70% breast cancers are positive for GCDFP and positive staining may help identify breast as the site of origin when this is uncertain. Lack of expression however does not rule out a primary breast origin.

9 Primary versus metastatic carcinoma

No single immunohistochemical marker is sensitive or specific enough to identify a carcinoma as definitively of breast origin. There are a variety of potentially useful markers which may aid diagnosis although those employed will depend on the likely differential diagnosis taking into account gender of the patient, histological features, previous history and clinical findings. Gross cystic disease fluid protein 15 (GCDFP) is a relatively specific marker for breast cancer providing a tumour of skin appendage or salivary gland origin is excluded. GCDFP lacks sensitivity however as it is expressed in only 50–75% cases of metastatic breast cancer. Nuclear ER positivity is suggestive of a breast origin although it is also strongly expressed in some gynaecological malignancies. Weak positive ER expression has been reported in occasional carcinomas from a wide variety of sites including stomach and lung and should not be considered to definitively indicate a breast origin. Expression of other markers, such as thyroid transcription factor -TTF1- (positive in 75% lung adenocarcinomas) and the CK 7/CK20 expression profile should be considered. The majority of breast carcinomas are CK7+/CK20- whilst gastric, hepatobiliary, colonic and mucinous ovarian carcinomas are usually CK20

positive. Positive expression of CK20 is therefore highly suggestive of a non-breast origin. Wilms tumour 1 (WT1) is expressed in the majority of ovarian serous or transitional carcinomas but carcinomas of breast are usually negative. If malignant melanoma is a consideration then positive expression of HMB45 and Melan A may be diagnostic. Of note, S100 protein may be expressed in both melanomas and breast carcinomas and is therefore less useful.

10 Lymph node assessment

Immunohistochemistry is not recommended as routine for examination of lymph nodes. However, it may be helpful if there are worrisome/uncertain features seen in the H&E sections. In this situation immunohistochemistry for broad spectrum cytokeratin, clone AE1/AE3, is recommended.¹ Reactivity of dendritic reticulum cells and some lymphoid cells may lead to false positive results when using some cytokeratin antibodies and assessment must therefore be based on immunoreactivity and morphological correlation.

Reference

1. Xu X, Roberts SA, Pasha TL, Zhang PJ. Undesirable cytokeratin immunoreactivity of native nonepithelial cells in sentinel lymph nodes from patients with breast carcinoma. *Arch Pathol Lab Med* 2000;124:1310–1313.

Table 1: Immunohistochemistry in breast cancer diagnosis

Diagnosis	Useful markers	Findings	Comments
Distinction between epithelial hyperplasia of usual type and atypical ductal hyperplasia/ low-grade DCIS	CK5, CK14, ER	Heterogeneous/mosaic staining for CK5 and CK14 in epithelial hyperplasia of usual type with ADH and DCIS uniformly negative. A mosaic pattern with ER may also be seen in usual epithelial hyperplasia, compared with uniform, strong positivity in the low-grade neoplasia family	Absence of staining does not necessarily imply atypia or malignancy as many normal cells and columnar cells also negative with CK5 and CK14 (and strongly positive for ER)
Lobular carcinoma phenotype	E-cadherin (and p120 catenin)	Invasive lobular carcinoma and LISN usually negative for E-cadherin and show cytoplasmic positivity for p120	Approximately 10–20% lobular carcinomas are E-cadherin positive. Take care not to misinterpret admixed E-cadherin positive epithelial and myoepithelial cells in LISN

Diagnosis	Useful markers	Findings	Comments
Assessment of stromal invasion	SMM, CK5, CK14, p63 (myoepithelial markers); CK7	Identification of surrounding myoepithelium usually implies an <i>in situ</i> process. CK7 may highlight infiltrative architecture	Note that myoepithelial staining may be discontinuous, therefore absence of staining does not always imply invasion and peripheral myoepithelial positivity does not imply <i>in situ</i> in, for example, adenoid cystic and adenosquamous carcinomas
Paget's disease of nipple versus squamous carcinoma and melanoma	CAM5.2, CK7, EMA, S100 protein, Melan A, HER2, p63	Paget's disease positive for CAM5.2, CK7, EMA and HER2. Melanoma positive for S100 and Melan A. p63 positive in squamous cell carcinoma	Note 20% of Paget's disease are S100 protein positive; Benign Toker cells are CK7 and CAM5.2 positive
Spindle cell lesions	CAM5.2, CK7, AE1/3, CK5, CK14, MNF116, SMA, CD34, ER, p63, Vimentin	Various – see text	Note potential for cytokeratin positivity in myoepithelial lesions and stroma of malignant phyllodes
Papillary lesions	SMM, p63, CK5, CK14, ER	Myoepithelial markers positive in fibrovascular cores of benign papilloma. Myoepithelium absent or reduced in papillary carcinoma <i>in situ</i> and encysted papillary carcinoma	CK5, CK14 and ER useful for identifying atypical epithelial proliferation within papilloma. Note absence of myoepithelial cells at periphery of encysted papillary carcinoma
Basal carcinoma phenotype	CK5, CK14, EGFR, Vimentin	Positive expression in basal phenotype, e.g. basal-like carcinomas	Staining for basal markers may be patchy and show variable sensitivity therefore use a panel
Apocrine carcinoma phenotype	GCDFP 15 (BRST-2), AR	Expressed in cells showing apocrine differentiation	Only 50–75% invasive carcinomas show positive expression of GCDFP15
Primary v secondary carcinoma	ER, PR, GCDFP 15, TTF1, WT1, CK7, CK20, S100 protein	ER positive in breast and gynaecological malignancy (less common, at low level, in a range of other tumour), TTF1 positive in adenocarcinoma of lung, WT1 positive in ovarian serous or transitional carcinoma, breast cancers usually CK7+/CK20-	Note some breast cancers may be S100 positive; some lung and gastric cancers may show weak ER positivity

Diagnosis	Useful markers	Findings	Comments
Lymph node assessment	AE1/AE3 and other broad spectrum cytokeratins and Ck7	Identifies epithelial cells and therefore facilitates detection of low level metastatic disease	Note potential for dendritic reticulum cells and some lymphoid cells to express epithelial markers; take care not to over-interpret benign epithelial inclusions

Appendix H Prognostic classifiers in breast cancer and emerging prognostic and biomarker assays

Selection of systemic adjuvant therapy in early stage breast cancer is based on the assessment of prognostic and predictive factors. Despite the fact that several factors have demonstrated strong and independent prognostic and predictive value, none of these variables on its own is able to reflect the degree of tumour heterogeneity or stratify patients into clinically distinct classes for treatment decision-making. Considering multiple factors in combination is of greater clinical value and forms the basis of a number of schemata used to group patients into various risk categories and estimate the prognosis for an individual patient. In routine practice, prognostic stratification aims to identify patients whose prognosis is so good that adjuvant systemic therapy can be avoided and it would not be a cost-beneficial and, conversely, those whose prognosis is poor and systemic therapy is justified. Predictive stratification is applied to identify patients who will or will not respond to specific type of therapy.

Data on prognostic and predictive factors, treatments and outcomes are used to estimate a risk equation (prognostic model), from which prognostic indices and algorithms are developed. A valid prognostic classifier typically provides the following:

- it stratifies patients into subsets with significantly differing outcomes
- it provides wide separation and good numbers in each subset
- it is simple and cost-efficient
- it is applicable to the widest spectrum of the disease, e.g. small through to large size, young to older age and a range of different tumour types
- its clinical efficacy is validated both internally and externally.

Currently available and widely used prognostic indices, algorithms and management guidelines include: the Nottingham Prognostic Index,¹ the AJCC tumour, node and metastasis (TNM) staging system² and the web-based tools Adjuvant!Online (www.adjuvantonline.com/index.jsp) and PREDICT (www.predict.nhs.uk/predict.html)³. These have been developed based on the clinical evidence of the different components of each classifier when used in combination.

Management guidelines include the St Gallen Consensus Criteria⁴, NCCN Clinical Guideline⁵ and the NIH Consensus Criteria⁶, which are derived from consensus opinions of international experts based on their interpretation of the current clinical evidence. These guidelines stratify patients into subsets based on valid prognostic tools and suggest preferred treatment protocols on the basis of reported estimates of efficacy.

The Nottingham Prognostic Index (NPI) is a well-validated prognostic scoring system based on the three standard and well-established prognostic variables in operable breast cancer: tumour size, histological grade and axillary lymph node status.^{1,7,8} NPI is widely used in UK and elsewhere. When first described, the NPI divided patients into three prognostic groups.¹ However, subsequent studies used NPI scores to allocate patients to more groups (up to six groups have been described).⁹

The NPI is calculated using the formula: $NPI = \text{Grade (1 to 3)} + \text{Node (1 to 3, see below)} + [\text{size of invasive carcinoma in cm} \times 0.2]$.

Node is the axillary lymph node stage estimated as follows:

Score 1 = Negative nodes

Score 2 = 1–3 positive axillary nodes or a positive internal mammary node alone (e.g. for medial tumours)

Score 3 = >3 positive nodes and/or the apical node, or any low axillary node and an internal mammary node together.

These three pathological variables are assessed microscopically at the time of diagnosis using full-face tissue sections. Size is the greatest dimension of the invasive tumour and in multifocal disease, the largest invasive tumour mass is considered. If histological assessment of tumour size or grade is not available, imaging or clinical size or preoperative core biopsy grade can be used.

NPI scores vary from 2.01 to up to >7 and can be sub-divided into the following groups:

<2.4	=	Excellent prognostic group
2.4 – <3.4	=	Good prognostic group
3.4 – <4.4	=	Moderate 1 prognostic group
4.4 – <5.4	=	Moderate 2 prognostic group
≥5.4	=	Poor prognostic group.

This latter category can be subdivided into poor (≥5.4–<6.4) and very poor prognostic groups (≥6.4).

The NPI is not applicable to tumours after neoadjuvant therapy, or in locally advanced or metastatic cancers or for recurrent tumours. Although management protocols based on NPI vary among different centres, adjuvant systemic therapy is typically given to patients in the poor prognostic group while patients in the excellent prognostic group are not offered such therapy. Although many guidelines recommend hormone therapy be offered to all ER-positive patients,⁴ published data indicate that patients in the excellent prognostic group have an excellent outcome that is comparable to age match general population even without systemic therapy.⁸ Patients in the good and moderate 1 groups are offered hormone therapy based on oestrogen receptor (ER) status. Adjuvant chemotherapy is often offered to patients in the moderate prognostic groups and selection of regimen is based on ER and HER2 status, other prognostic variables and local protocol.

Several studies have attempted to improve the classification power and applicability of the NPI by incorporation of other variables such as lymphovascular invasion, ER, PR and HER2 status. Although these features are considered in the treatment decision-making process, none of these variables have been incorporated in the NPI formula, as yet. However, there is compelling evidence that ER and HER2 positive and negative tumours are distinct diseases and that NPI may produce different stratification power among these classes.

The AJCC TNM staging system is applicable to all breast cancers, including metastatic disease. However, its stratification power is limited in the early stage disease, which comprises a large proportion of cases typically presenting in UK practice (i.e. small and/or node-negative tumours) and does not incorporate histological grade or receptors status. The NCCN guideline⁵ is a comprehensive management decision tool that consider tumour size, grade, nodal status, ER and HER2 status and tumour histological type and includes management for *in-situ* carcinomas.

Adjuvant! Online (www.adjuvantonline.com/index.jsp) is a web-based outcome and treatment benefit assessment tool that is introduced to help making decisions about adjuvant therapy in early stage breast cancer. Adjuvant!Online uses tumour size, node stage, tumour grade, ER status, patient age and co-morbidities to predict patient survival. The main advantage of this system is that the additional benefit of a range of systemic therapies (hormone therapy, chemotherapy or combined) can be estimated, in addition to the patient's underlying likely prognosis. Another version of Adjuvant!Online can be used to assessed the risk of relapse in patients with ER positive breast cancer at time they are completing 5 years of adjuvant tamoxifen. PREDICT is a similar mathematical model developed utilising cohorts of UK patients and includes HER2 and Ki67 status. Like Adjuvant!Online, PREDICT (www.predict.nhs.uk/predict.html) aims to estimate not only breast cancer survival but the benefits of different systemic therapies.

Emerging prognostic and biomarker assays

The shift towards an earlier diagnosis of breast cancer largely due to improved imaging methods and screening programs, and the incremental application of increasingly effective adjuvant therapies, have highlighted the need for additional prognostic and predictive markers to enable individualised and patient-tailored therapy. Among the widely assessed variables in breast cancer, the proliferation marker Ki67 and gene expression-based tests have received most attention. Ki67 is a nuclear non-histone protein expressed in proliferating cells and absent in quiescent (G_0 phase) cells. Its expression levels are determined as the percentage of immunohistochemically stained invasive tumour cell nuclei. The use of Ki67 as a prognostic and predictive marker in breast cancer has been widely investigated¹⁰ because it is perceived that Ki67 assessment can provide a more objective and accurate method of tumour proliferation than mitotic counts; a key component of histological grade.

Although prognostic value to Ki67 assessment has been demonstrated in several reports,^{10–11} variation among studies regarding methodology and the choice of optimal cut-off point have interfered with the full evaluation of any additional prognostic information it may provide and thus its incorporation into present published guidelines, apart from the St Gallen Consensus criteria.⁴ In a comprehensive review of Ki67 as a predictive marker in breast cancer,¹⁰ it was concluded that current evidence of its predictive value and its ability to identify patients who will benefit from specific chemotherapy or endocrine therapy is not robust and needs further validation. However, when Ki67 expression is used as a continuous variable (percentage), it consistently demonstrates prognostic utility. As such, Ki67 has been incorporated with other markers, namely ER, PR and HER2, to develop prognostic models that, in initial studies at least, perform similarly to Oncotype DX score¹² in recurrence prediction. This includes the IHC4 score¹³ and Magee Equations.¹⁴ In the latter, the 4 markers are combined with tumour size and histological grading score (scores 3–9) to predict recurrence. There is thus some evidence that Ki67 can provide a cost-effective additional molecular test that can be done in parallel with other immunohistochemical markers that are included in the pathology report. Development of guidelines regarding standardisation of methodology and validation of defined cut-off points are required prior to its acceptance in routine clinical practice. Currently, tumours with inadequate fixation, grade 2 cancers (which comprise 30–50% of cases), ER-positive and HER2-negative cancers are expected to benefit most from Ki67 assessment.^{15,16}

With the introduction of high-throughput genome-wide technologies, numerous multigene signatures and molecular assays have been identified which aim to predict outcome and response to therapy that can outperform or complement traditional markers. Two such assays relying upon measurement of gene expression in tumour RNA, namely Oncotype DX¹² and MammaPrint¹⁷, that have been tested in clinical trials are approved by the US Food and Drug Administration (FDA) and are commercially available.

Oncotype DX, which assesses the expression of 21 genes in formalin-fixed, paraffin-embedded tumour tissue using RT-PCR, produces a recurrence score. The scores vary from 0 to 100 and cut-offs are used to stratify patients into 3 risk groups namely low (score 0–17), intermediate (score 18–30) and high (score 31 or more). It is applied mainly to women with node negative ER-positive HER2-negative tumours to evaluate the likelihood of recurrence and assesses the benefit of adjuvant chemotherapy. Oncotype DX is incorporated in the management decision models by NCCN Clinical Guidelines⁵ and the St Gallen criteria⁴ and it is recommended by the American Society of Clinical Oncology (ASCO)¹⁸ and the European Society for Medical Oncology (ESMO) as a useful diagnostic tool to gain additional information to complement pathology assessment. It is not recommended for ER-negative, HER2-positive tumours.

MammaPrint is a gene expression profile assay that measures 70 cancer-related genes in frozen tumour tissue samples using DNA microarray. The MammaPrint Index is calculated and a prognosis assignment score of low risk or high risk is produced to predict the likelihood of breast cancer recurrence. Several other multigene assays such as the 76-gene 'Rotterdam signature' assay, Mammostrat, the Breast Cancer Gene Expression Ratio (THEROS Breast Cancer IndexSM) are described, but more supporting data are needed to assess their clinical utility. Current evidence

indicates that both advanced tumours and, conversely, tumours in the excellent NPI prognostic groups are not likely to benefit from such molecular tests.

Other types of multigene classifiers include molecular ‘intrinsic’ subtypes. Global gene expression profiling is used to classify invasive breast cancers into molecularly distinct classes that showed an association with outcome. These subtypes are known as Luminal A, Luminal B, HER2-Enriched (HER2-E) and basal-like classes. Several studies have demonstrated that this molecular subtyping is an independent predictor of survival in breast cancer when used in multivariate analyses with standard prognostic variables.¹⁹ To improve reproducibility and reduce the number of genes used in the classification, a small gene set (PAM50) has been identified and shows comparable classification power to that of the larger ‘intrinsic’ gene sets previously used,¹⁹ and it is now more commonly employed. However, these molecular classifiers may measure the same biology assessed by conventional pathologic tools such as grade, proliferation and receptor status and the added value of this RNA-based intrinsic gene set classification over the pathologically determined markers, particularly when used in combination, is not clear. These assays are relatively high cost, technically demanding and therefore potentially limited in their clinical utility. Although equivalent groups can be defined using immunohistochemistry there is no globally agreed panel of markers to define luminal, HER2 and basal-like groups. The best agreement is for the basal-like subgroup of tumours; these lesions being ‘triple negative’, i.e. ER, PR and HER2 negative, but expressing either CK5 or epidermal growth factor receptor (EGFR).^{20,21} Such basal-like invasive carcinomas have been described to be of poor prognosis,²² although this range of lesions includes adenoid cystic carcinomas and other low-grade metaplastic lesions, in addition to medullary-like carcinomas and other more typical metaplastic cancers.

More markers and assays have the potential to become relevant in the near future but careful randomised testing and comparison with existing established factors are required to select those emerging markers that offer additional prognostic and/or predictive value in a cost-effective way and thereby justify their use for routine invasive breast cancer therapy decision-making.

References

1. Galea MH, Blamey RW, Elston CE, Ellis IO. The Nottingham Prognostic Index in primary breast cancer. *Breast Cancer Res Treat* 1992;22:207–219.
2. Edge SB, Byrd DR, Compton CC, Fritz AG, Greene FL, Trotti A. *AJCC cancer staging manual* (7th ed). New York: Springer; 2010.
3. Wishart GC, Azzato EM, Greenberg DC, Rashbass J, Kearins O, Lawrence G *et al*. PREDICT: a new UK prognostic model that predicts survival following surgery for invasive breast cancer. *Breast Cancer Res*. 2010;12:R1.
4. Goldhirsch A, Wood WC, Coates AS, Gelber RD, Thürlimann B, Senn HJ. Strategies for subtypes--dealing with the diversity of breast cancer: highlights of the St. Gallen International Expert Consensus on the Primary Therapy of Early Breast Cancer 2011. *Ann Oncol* 2011;22:1736–1747.
5. National Comprehensive Cancer Network (NCCN). *NCCN Clinical Practice Guidelines in Oncology: Breast Cancer (V.1.2012)*. 2012. For additional information, see www.nccn.org
6. Eifel P, Axelson JA, Costa J, Crowley J, Curran WJ Jr, Deshler A *et al*. National Institutes of Health Consensus Development Conference Statement: adjuvant therapy for breast cancer, November 1–3, 2000. *J Natl Cancer Inst*. 2001;93:979–989.
7. Balslev I, Axelsson CK, Zedeler K, Rasmussen BB, Carstensen B, Mouridsen HT. The Nottingham Prognostic Index applied to 9,149 patients from the studies of the Danish Breast Cancer Cooperative Group (DBCG). *Breast Cancer Res Treat*. 1994;32:281–290.

8. Blamey RW, Ellis IO, Pinder SE, Lee AH, Macmillan RD, Morgan DA *et al.* Survival of invasive breast cancer according to the Nottingham Prognostic Index in cases diagnosed in 1990–1999. *Eur J Cancer* 2007;43:1548–1555.
9. Williams C, Brunskill S, Altman D, Briggs A, Campbell H, Clarke M *et al.* Cost-effectiveness of using prognostic information to select women with breast cancer for adjuvant systemic therapy. *Health Technol Assess* 2006;10:1–204.
10. Yerushalmi R, Woods R, Ravdin PM, Hayes MM, Gelmon KA. Ki67 in breast cancer: prognostic and predictive potential. *Lancet Oncol.* 2010;11:174–183.
11. Stuart-Harris R, Caldas C, Pinder SE, Pharoah P. Proliferation markers and survival in early breast cancer: a systematic review and meta-analysis of 85 studies in 32,825 patients. *Breast* 2008;17:323–334.
12. Paik S, Shak S, Tang G, Kim C, Baker J, Cronin M *et al.* A multigene assay to predict recurrence of tamoxifen-treated, node-negative breast cancer. *N Engl J Med.* 2004;351:2817–2826.
13. Cuzick J, Dowsett M, Pineda S, Wale C, Salter J, Quinn E *et al.* Prognostic Value of a Combined Estrogen Receptor, Progesterone Receptor, Ki-67, and Human Epidermal Growth Factor Receptor 2 Immunohistochemical Score and Comparison With the Genomic Health Recurrence Score in Early Breast Cancer. *J Clin Oncol.* 2011;29:4273–4278.
14. Klein ME, Dabbs DJ, Shuai Y, Brufsky AM, Jankowitz R, Puhalla SL *et al.* Prediction of the Oncotype DX recurrence score: use of pathology-generated equations derived by linear regression analysis. *Mod Pathol.* 2013;26:658–664.
15. Aleskandarany MA, Green AR, Benhasouna AA, Barros FF, Neal K, Reis-Filho JS *et al.* Prognostic value of proliferation assay in the luminal, HER2-positive, and triple-negative biologic classes of breast cancer. *Breast Cancer Res.* 2012;14:R3.
16. Aleskandarany MA, Rakha EA, Macmillan RD, Powe DG, Ellis IO, Green AR. MIB1/Ki-67 labelling index can classify grade 2 breast cancer into two clinically distinct subgroups. *Breast Cancer Res Treat.* 2010;127:591–599.
17. van 't Veer LJ, Dai H, van de Vijver MJ, He YD, Hart AA, Mao M *et al.* Gene expression profiling predicts clinical outcome of breast cancer. *Nature* 2002;415:530–536.
18. Harris L, Fritsche H, Mennel R, Norton L, Ravdin P, Taube S *et al.* American Society of Clinical Oncology 2007 update of recommendations for the use of tumor markers in breast cancer. *J Clin Oncol* 2007;25:5287–5312.
19. Parker JS, Mullins M, Cheang MC, Leung S, Voduc D, Vickery T *et al.* Supervised risk predictor of breast cancer based on intrinsic subtypes. *J Clin Oncol.* 2009;27:1160–1167.
20. Nielsen TO, Hsu FD, Jensen K, Cheang M, Karaca G, Hu Z *et al.* Immunohistochemical and clinical characterization of the basal-like subtype of invasive breast carcinoma. *Clin Cancer Res.* 2004;10:5367–5374.
21. Cheang MC, Voduc D, Bajdik C, Leung S, McKinney S, Chia SK *et al.* Basal-like breast cancer defined by five biomarkers has superior prognostic value than triple-negative phenotype. *Clin Cancer Res.* 2008;14:1368–1376.
22. Rakha EA, El-Rehim DA, Paish C, Green AR, Lee AH, Robertson JF *et al.* Basal phenotype identifies a poor prognostic subgroup of breast cancer of clinical importance. *Eur J Cancer.* 2006;42:3149–3156.

Breast Cancer Grading

Nottingham Criteria

Accurate grading of invasive breast cancer requires good fixation, processing, section cutting, staining and careful application of grading criteria. In the UK, about 20% of symptomatic breast cancers are grade 1, 30% grade 2, and 50% grade 3. These proportions may be different in asymptomatic cancers detected by mammographic screening. Special type cancers (lobular, etc) should also be graded. Three separate scores are given:

Gland (acinus) formation

Score 1: more than 75% of the whole carcinoma forms acini

Score 2: 10–75% of the whole carcinoma forms acini

Score 3: less than 10% of the whole carcinoma forms acini

Only score clearly formed glandular lumens surrounded by polarised cancer cells

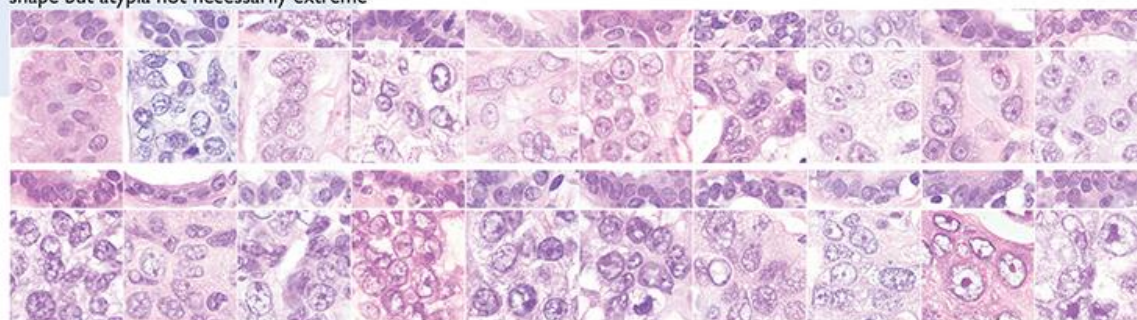
Nuclear atypia/pleomorphism

Only about 5% of symptomatic cancers score 1 for nuclear atypia; about 50% score 3.

Score 1: nuclei only slightly larger than benign breast epithelium (< 1.5 × normal area); minor variation in size, shape and chromatin pattern

Score 2: nuclei distinctly enlarged (1.5–2 × normal area), often vesicular, nucleoli visible; may be distinctly variable in size and shape but not always

Score 3: markedly enlarged vesicular nuclei (> 2 × normal area), nucleoli often prominent; generally marked variation in size and shape but atypia not necessarily extreme



Nuclei of 20 consecutive breast cancers by increasing mean nuclear area (left to right, top to bottom). Paired non-neoplastic breast epithelium is shown above each case for comparison. Only one cancer (top left) has nuclei which score 1. The others in the top row score 2. All 10 in the bottom row score 3.

Mitosis counts

Measure diameter of high power field (hpf) on your microscope to the nearest 0.01 mm. Always use same objective and eyepieces; if either is changed, measure again. Read score thresholds from table below. Scan sections to find area with most mitotic activity (often at tumour edge). In this area count definite mitoses in 10 consecutive fields. Skip fields with few carcinoma cells or obvious necrosis. Convert to score (1–3).

Table of mitosis score thresholds

Field diameter (mm)	Mitotic frequency score			Field diameter (mm)	Mitotic frequency score			Field diameter (mm)	Mitotic frequency score		
	1	2	3		1	2	3		1	2	3
0.40	≤4	5–9	≥10	0.50	≤7	8–14	≥15	0.60	≤10	11–20	≥21
0.41	≤4	5–9	≥10	0.51	≤7	8–14	≥15	0.61	≤10	11–21	≥22
0.42	≤5	6–10	≥11	0.52	≤7	8–15	≥16	0.62	≤11	12–22	≥23
0.43	≤5	6–10	≥11	0.53	≤8	9–16	≥17	0.63	≤11	12–22	≥23
0.44	≤5	6–11	≥12	0.54	≤8	9–16	≥17	0.64	≤11	12–23	≥24
0.45	≤5	6–11	≥12	0.55	≤8	9–17	≥18	0.65	≤12	13–24	≥25
0.46	≤6	7–12	≥13	0.56	≤8	9–17	≥18	0.66	≤12	13–24	≥25
0.47	≤6	7–12	≥13	0.57	≤9	10–18	≥19	0.67	≤12	13–25	≥26
0.48	≤6	7–13	≥14	0.58	≤9	10–19	≥20	0.68	≤13	14–26	≥27
0.49	≤6	7–13	≥14	0.59	≤9	10–19	≥20	0.69	≤13	14–27	≥28

Final grading

Add scores for acinus formation, nuclear atypia and mitosis count. Total score must be in the range 3–9.

Total score 3, 4 or 5 = **grade 1** Total score 6 or 7 = **grade 2** Total score 8 or 9 = **grade 3**

Prepared by Dr James J Going, Department of Pathology, Western Infirmary, Glasgow, based on Elston CW, Ellis IO. Pathological prognostic factors in breast cancer. I. The value of histological grade in breast cancer: experience from a large study with long-term follow-up. *Histopathology*, 1991; 19: 403–410, and reproduced with permission.

© NHS Cancer Screening Programmes 2005. Printed by Charlesworth, Wakefield.

Additional copies are available from DH Publications Orderline (tel 08701 555 455 or email doh@prolog.uk.com) quoting BGRADPSTR.

Appendix J Summary table – Explanation of level of evidence

(Adopted from Palmer K *et al. BMJ* 2008; 337:1832.)

Level of evidence	Nature of evidence
Level A	<p>At least one high-quality meta-analysis, systematic review of randomised controlled trials or a randomised controlled trial with a very low risk of bias and directly attributable to the target cancer type</p> <p>or</p> <p>A body of evidence demonstrating consistency of results and comprising mainly well-conducted meta-analyses, systematic reviews of randomised controlled trials or randomised controlled trials with a low risk of bias, directly applicable to the target cancer type.</p>
Level B	<p>A body of evidence demonstrating consistency of results and comprising mainly high-quality systematic reviews of case-control or cohort studies and high-quality case-control or cohort studies with a very low risk of confounding or bias and a high probability that the relation is causal and which are directly applicable to the target cancer type</p> <p>or</p> <p>Extrapolation evidence from studies described in A.</p>
Level C	<p>A body of evidence demonstrating consistency of results and including well-conducted case-control or cohort studies and high quality case control or cohort studies with a low risk of confounding or bias and a moderate probability that the relation is causal and which are directly applicable to the target cancer type</p> <p>or</p> <p>Extrapolation evidence from studies described in B.</p>
Level D	<p>Non-analytic studies such as case reports, case series or expert opinion</p> <p>or</p> <p>Extrapolation evidence from studies described in C.</p>
Good practice point (GPP)	<p>Recommended best practice based on the clinical experience of the authors of the writing group</p>

Appendix K AGREE compliance monitoring sheet

The cancer datasets of The Royal College of Pathologists comply with the AGREE standards for good quality clinical guidelines (www.agreetrust.org). The sections of this dataset that indicate compliance with each of the AGREE standards are indicated in the table.

AGREE standard	Section of dataset
Scope and purpose	
1. The overall objective(s) of the guideline is (are) specifically described	Introduction
2. The clinical question(s) covered by the guidelines is (are) specifically described	Introduction
3. The patients to whom the guideline is meant to apply are specifically described	Foreword
Stakeholder involvement	
4. The guideline development group includes individuals from all the relevant professional groups	Foreword
5. The patients' views and preferences have been sought	N/A
6. The target users of the guideline are clearly defined	Introduction
7. The guideline has been piloted among target users	Foreword
Rigour of development	
8. Systematic methods were used to search for evidence	Foreword
9. The criteria for selecting the evidence are clearly described	Foreword
10. The methods used for formulating the recommendations are clearly described	Foreword
11. The health benefits, side effects and risks have been considered in formulating the recommendations	Foreword
12. There is an explicit link between the recommendations and the supporting evidence	2–8
13. The guideline has been externally reviewed by experts prior to its publication	Foreword
14. A procedure for updating the guideline is provided	Foreword
Clarity of presentation	
15. The recommendations are specific and unambiguous	Throughout
16. The different options for management of the condition are clearly presented	Throughout
17. Key recommendations are easily identifiable	Throughout
18. The guideline is supported with tools for application	Appendices 3 and 4
Applicability	
19. The potential organisational barriers in applying the recommendations have been discussed	Foreword, Introduction
20. The potential cost implications of applying the recommendations have been considered	Foreword, Introduction
21. The guideline presents key review criteria for monitoring and/or audit purposes	12
Editorial independence	
22. The guideline is editorially independent from the funding body	Foreword
23. Conflicts of interest of guideline development members have been recorded	Foreword